

Adults Clinical Communications

MULTISYSTEM INFLAMMATORY SYNDROME IN AN ADULT

Mary-Kate Amato, MD,* Christopher Hennessy, MD,* Kaushal Shah, MD,† and Jeffrey Mayer, MD†

*Department of Emergency Medicine, New York-Presbyterian/Weill Cornell Medical College and Columbia Vagelos College of Physicians and Surgeons, New York, New York and †Department of Emergency Medicine, Weill Cornell Medical College, New York, New York

Corresponding Address: Mary-Kate Amato, MD, Department of Emergency Medicine, New York-Presbyterian/Weill Cornell Medical College and Columbia Vagelos College of Physicians and Surgeons, 525 E 68th St, New York, NY 10065

Abstract—Background: Multisystem inflammatory syndrome in children is a phenomenon that has emerged during the coronavirus disease 2019 (COVID-19) pandemic. There are, however, few reported cases of a similar disease in adults. **Case Report:** We describe a 25-year-old man who presented with prolonged fever and conjunctivitis and was found to have a post-COVID inflammatory syndrome. His symptoms improved with colchicine, steroids, and a truncated course of intravenous immunoglobulin. **Why Should an Emergency Physician Be Aware of This?:** Post-COVID inflammatory syndrome has the potential to lead to dangerous complications. In addition, the identification of occult COVID infections could have public health implications. © 2021 Elsevier Inc. All rights reserved.

Keywords—COVID-19; inflammatory syndrome; MIS-A; MIS-C

INTRODUCTION

The phenomenon of multisystem inflammatory syndrome in children (MIS-C) emerged during the coronavirus disease 2019 (COVID-19) pandemic. Children with MIS-C have current or recent COVID-19 infection or recent exposure to the disease. Reported symptoms include fever or chills, tachycardia, gastrointestinal symptoms, rash, conjunctival injection, and mucosal changes with a relative lack of severe respiratory disease. A large percentage of these patients develop shock and cardiac

dysfunction, requiring intensive care unit level care (1–3). Laboratory results in children with MIS-C show severe inflammation. Few similar cases in older patients, now named multisystem inflammatory syndrome in adults (MIS-A), have emerged as well (4). We report a related case of a 25-year-old man with prolonged fever, conjunctivitis, elevated inflammatory markers, and recent COVID-19 infection. Although this patient did not experience hemodynamic instability consistent with MIS-A, this case likely represents a variant of post-COVID-19 inflammatory syndromes.

Case Report

A 25-year-old African American man with a medical history significant only for severe autism (minimally communicative at baseline) initially presented with his family to an urgent care clinic with a 2-day history of fever and bilateral eye redness without vision change. The patient denied any shortness of breath, cough, or other symptoms. A chest radiograph revealed no infiltrates or other acute findings. The patient was started on amoxicillin-clavulanic acid and azithromycin to cover for presumed early bacterial infection not detected on the chest radiograph. In addition, he was also started on antihistamine eye drops for allergic conjunctivitis and was subsequently discharged.

On day 3 of his illness, the patient presented to the emergency department for persistent fever (temperature

Reprints are not available from the authors.

maximum [Tmax] 38.3°C) and eye redness. At the time of presentation, the patient was afebrile and his vital signs were otherwise unremarkable. The physical examination revealed no acute respiratory distress and was significant only for bilateral conjunctival injection. He was diagnosed with viral conjunctivitis, instructed to stop taking the antibiotics, and discharged home.

On day 10 of his illness, the patient again returned to the emergency department with continued bilateral eye redness and daily fever (Tmax 38.6°C). A review of systems was otherwise negative. Vital signs were 37.0°C, blood pressure 101/63 mm Hg, respiratory rate 18 breaths/min, heart rate 60 beats/min, and peripheral oxygen saturation 98% on room air. The patient appeared well and was in no acute respiratory distress. The physical examination was unchanged from his previous visit. A broader infectious workup was pursued, including a complete blood cell count, basic metabolic panel, COVID-19 polymerase chain reaction (PCR) swab, repeat chest radiograph, urinalysis, urine culture, and blood cultures. A complete blood cell count revealed a mild leukocytosis to $11.5 \times 10(3)/\mu\text{L}$ and anemia to 10.7 g/dL. The basic metabolic panel and urinalysis were unremarkable. The COVID-19 PCR study was negative. The chest radiograph featured a retrocardiac airspace opacity that was suspicious for pneumonia (Figures 1 and 2). The blood cultures were negative. The patient was prescribed

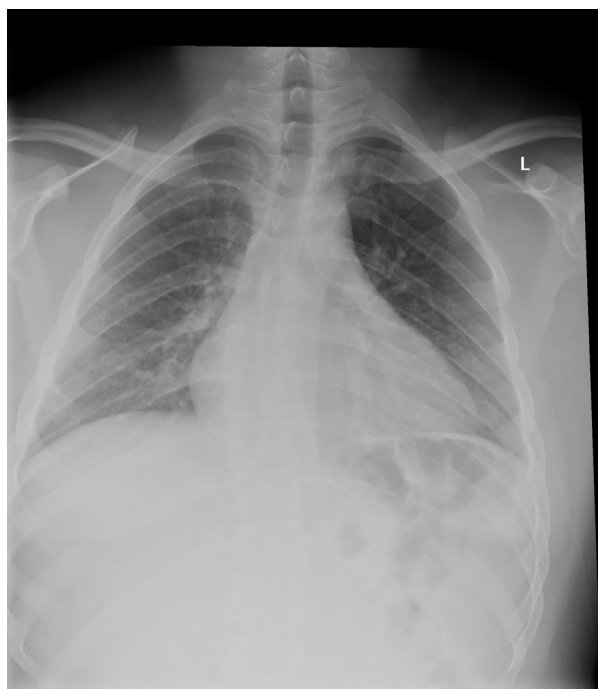


Figure 1. Posteroanterior chest x-ray with no pleural effusion or pneumothorax. The cardiomeastinal silhouette is mildly enlarged.

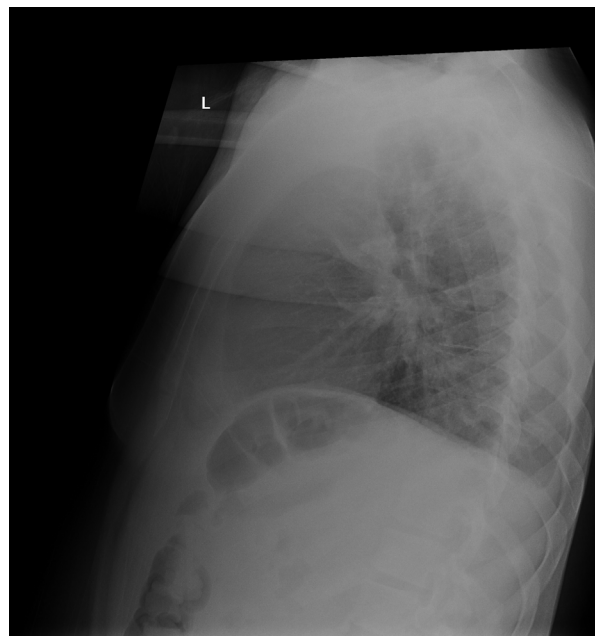


Figure 2. Lateral chest x-ray with retrocardiac airspace opacity.

doxycycline for pneumonia and erythromycin eyedrops for bacterial conjunctivitis. The antibiotic regimen was formulated in consultation with the hospital pharmacist given the failed versus incomplete course of antibiotics. The patient was then discharged.

Three days later, on day 13 of symptoms, the patient again presented to the emergency department with worsening eye redness and fever (Tmax 39.4°C) despite compliance with antibiotics. The patient denied any other new symptoms, and the physical examination was again unchanged. Laboratory studies revealed a white blood cell count of $10.83 \times 10(3)/\mu\text{L}$, hemoglobin of 10.9 g/dL, C-reactive protein of 22.1 mg/dL, and erythrocyte sedimentation rate 123 mm/hr, an unremarkable complete metabolic panel, lactate 0.80 mmol/L, procalcitonin <0.06 ng/mL, and a COVID-19 PCR study was again negative. A chest radiograph revealed a persistent retrocardiac opacity with trace bilateral pleural effusions, which may reflect pneumonia. In addition, ophthalmology was consulted, and concluded that the eye symptoms were likely caused by viral conjunctivitis, although uveitis could not be ruled out at the time. Moxifloxacin eye drops were recommended to prevent superinfection. Given the persistence of fever and failed outpatient treatment, the patient was then admitted to the medicine floor for further inpatient workup.

During the inpatient course, the patient was positive for anti-severe acute respiratory syndrome coronavirus 2 antibody on serologic testing, despite multiple previous negative nasal PCR swabs. Further infectious evaluation

was pursued; however, the results were negative. The patient was diagnosed with post-COVID-19 systemic inflammatory response, on the spectrum of Kawasaki-like manifestations recently reported in children and adults with MIS-C and MIS-A. The patient was treated with colchicine and steroids, and a brief intravenous immunoglobulin trial. This resulted in subsequent improvement in symptoms, including resolution of fever and conjunctival injection. His ESR and CRP trended down and he was discharged after a 17-day inpatient stay with a steroid taper and trimethoprim-sulfamethoxazole prophylaxis.

DISCUSSION

We report a 25-year-old man who presented with prolonged fever and conjunctivitis and was found to have elevated inflammatory markers. After undergoing an extensive and otherwise negative workup, the patient tested positive for COVID-19 antibodies. His illness was attributed to a post-COVID-19 inflammatory syndrome. He improved with colchicine, steroids, and a truncated course of intravenous immunoglobulin.

COVID-19 has made an enormous impact on our health care system. Much about this virus is yet to be fully understood, including COVID-19-related multisystem inflammatory disease in children. Given the commonality of features, it has been postulated that the pathophysiology of MIS-C may be similar to that of Kawasaki disease (5). Kawasaki disease treatment modalities have been used in the management of MIS-C (6).

Although this syndrome is more common in children, this case, along with several other reports of post-COVID-19 inflammatory syndrome in adults, shows that emergency physicians should consider this disease in their differential diagnoses for adults with prolonged fever, rash, conjunctivitis, lymphadenopathy, gastrointestinal symptoms, or headache in the setting of possible COVID-19 exposure or infection (4,7).

It is important to consider this diagnosis because many patients with MIS-C or MIS-A disease decompensate into a shock state, requiring admission to the intensive care unit (1). In addition, these patients have a high risk of cardiac manifestations, including myocarditis and coronary aneurysm (8). Inflammatory markers are useful for stratifying risk and monitoring response to therapy. Treatment includes steroids, intravenous immunoglobulin, and

immunomodulatory medications, as well as supportive care.

In addition, we recommend further observation and study to confirm whether conjunctivitis would be one of the constellations for COVID-19 symptoms. From a public health perspective, detecting cases of coronavirus in patients presenting with conjunctivitis could lead to more appropriate self-quarantining and, ultimately, a decreased transmission of the virus.

WHY SHOULD AN EMERGENCY PHYSICIAN BE AWARE OF THIS?

Emergency physicians should be aware of the possibility of post-COVID-19 inflammatory syndrome and MIS-A in adults, given the potential for dangerous complications demonstrated in pediatric populations. In the setting of this global pandemic, emergency physicians should have a low threshold for performing broad infectious and inflammatory workups in patients with prolonged and otherwise unexplained fever.

REFERENCES

1. Dufort EM, Koumans EH, Chow EJ, et al. Multisystem inflammatory syndrome in children in New York State. *N Engl J Med* 2020;383:347–58.
2. Toubiana J, Poirault C, Corsia A, et al. Kawasaki-like multisystem inflammatory syndrome in children during the covid-19 pandemic in Paris, France: prospective observational study. *BMJ* 2020;369:m2094.
3. Rauf A, Vijayan A, John ST, Krishnan R, Latheef A. Multisystem inflammatory syndrome with features of atypical Kawasaki disease during COVID-19 pandemic. *Indian J Pediatr* 2020;87:745–7.
4. Sokolovsky S, Soni P, Hoffman T, Kahn P, Scheers-Masters J. COVID-19 associated Kawasaki-like multisystem inflammatory disease in an adult. *Am J Emerg Med* 2021;39:253. e1–2.
5. Ebina-Shibuya R, Namkoong H, Shibuya Y, Horita N. Multisystem inflammatory syndrome in children (MIS-C) with COVID-19: insights from simultaneous familial Kawasaki disease cases. *Int J Infect Dis* 2020;97:371–3.
6. Sperotto F, Friedman KG, Son MBF, VanderPluym CJ, Newburger JW, Dionne A. Cardiac manifestations in SARS-CoV-2-associated multisystem inflammatory syndrome in children: a comprehensive review and proposed clinical approach. *Eur J Pediatr* 2021;180:307–22.
7. Cogan E, Foulon P, Cappeliez O, Dolle N, Vanfraechem G, De Backer D. Multisystem inflammatory syndrome with complete Kawasaki disease features associated with SARS-CoV-2 infection in a young adult. A case report. *Front Med (Lausanne)* 2020;7:428.
8. Ramcharan T, Nolan O, Lai CY, et al. Paediatric inflammatory multisystem syndrome: temporally associated with SARS-CoV-2 (PIMS-TS): cardiac features, management and short-term outcomes at a UK tertiary paediatric hospital. *Pediatr Cardiol* 2020;41:1391–401.