

## REVIEW ARTICLE

Dan L. Longo, M.D., *Editor*

## Cerebral Venous Thrombosis

Allan H. Ropper, M.D., and Joshua P. Klein, M.D., Ph.D.

CEREBRAL VENOUS THROMBOSIS IS AN UNUSUAL CEREBROVASCULAR DISORDER that is of current interest, in part because of rare cases associated with certain of the coronavirus disease 2019 (Covid-19) vaccines. The characteristics of infarction caused by cerebral venous thrombosis differ from those of the usual forms of ischemic stroke caused by occlusion of arterial vessels. This brief review calls attention to the diagnosis of cerebral venous thrombosis, based on clinical and imaging features, and treatments that have become available since the subject was reviewed in the *Journal* in 2005.<sup>1</sup>

From the Department of Neurology, Brigham and Women's Hospital, Boston.

*N Engl J Med* 2021;385:59-64.

DOI: 10.1056/NEJMra2106545

Copyright © 2021 Massachusetts Medical Society.

## ANATOMY AND PATHOPHYSIOLOGY

Dural sinus thrombosis refers to clots in large, dural venous conduits, and cortical vein thrombosis refers to occlusion of veins on the surface of the cortex. Cerebral venous thrombosis encompasses both dural clots and cortical vein occlusion. The most prominent dural venous channel is the superior sagittal sinus, which drains posteriorly into the transverse (lateral) sinuses and thence into the internal jugular veins on each side. The superior sagittal and transverse sinuses are fed by many tributary surface cortical veins that vary in size and location; on each side, the largest of these veins are named for Trolard (veins draped vertically over the parietal lobe and draining into the superior sagittal sinus) and for Labbé (veins situated horizontally over the temporal lobe and draining into the transverse sinus). It is common for venous clots to originate in a dural sinus and propagate to cortical veins; isolated cortical vein thrombosis has been reported in only 116 patients, on the basis of a review of the literature.<sup>2</sup> Thromboses also occur independently in deep venous structures (the straight sinus, vein of Galen, inferior sagittal sinus, internal cerebral veins that drain the thalami, and basal veins of Rosenthal), giving rise to syndromes local to the affected vein.

Cerebral venous thrombosis causes two distinct pathophysiological entities: cortical venous infarction with focal neurologic syndromes, and raised intracranial pressure, as summarized in the previous review in the *Journal*.<sup>1</sup> These clinical syndromes, individually or together, usually evolve over a period of hours or days but can progress for weeks.

## CLINICAL SYNDROMES

The presenting feature of dural sinus thrombosis is acute or subacute headache in 70 to 90% of patients, often with a normal neurologic examination. Seizures, usually focal convulsions, and stroke deficits may follow if cortical infarction occurs.

The headache usually progresses during a period of hours or days to severe aching or throbbing over the entire cranium, bifrontally, or at the vertex, the last being infrequent but more specific.<sup>3</sup> In a series of 200 patients with cerebral ve-

nous thrombosis, 136 had headache (of 1 to 3 days' duration in most patients at the time of diagnosis); in about one third of patients, cranial pain was unilateral, and in one fifth it was more localized.<sup>4</sup> Throbbing headache may occur, but in our experience, patients with migraine can distinguish this throbbing headache from their usual migraine headache. Coughing, bending over, or head movements tend to worsen the headache. A few patients have "thunderclap headache," which has the suddenness and intensity that the term implies but is most characteristic of subarachnoid hemorrhage. Papilledema may develop over a period of days or weeks after dural sinus thrombosis. Other manifestations of increased intracranial pressure, such as bilateral sixth cranial nerve palsies, can occur but are uncommon.

Focal neurologic deficits occur hours or days after the headache in about half of patients with cortical vein thrombosis. The common syndromes are paresis of one or both legs or hemiparesis from infarction in the frontoparietal regions surrounding the vein of Trolard, and aphasia and confusion from infarction in the temporal lobe surrounding the vein of Labbé. In a series of 181 patients, cerebral imaging showed frontal and frontoparietal lesions in 25% and 22% of the patients, respectively.<sup>5</sup> A few cases have been characterized by encephalopathy or coma, usually from multiple sinus or deep venous occlusions, sometimes with raised intracranial pressure. Deficits fluctuate and may be largely reversible; they may be heralded by or worsen after a convulsion. The main point is that the syndromes do not respect the territories involved in mundane arterial strokes.

Seizures occurred within a week after thrombosis in 34% of 1281 patients in a consortium study,<sup>6</sup> and status epilepticus may occur (and is sometimes refractory to treatment), with rates varying across large series. Syndromes of deep cerebral vein thrombosis are complex and include drowsiness or stupor from bilateral thalamic dysfunction and obstructive hydrocephalus.

Cavernous sinus thrombosis causes a regional syndrome of periorbital and forehead pain, ocular chemosis, and palsies of cranial nerves that pass through the structure (the third, fourth, and sixth cranial nerves and the ophthalmic and maxillary divisions of the fifth cranial nerve). If thrombosis extends from the cavernous to the

petrosal sinuses, there are brain-stem and cerebellar signs.

#### CAUSES

The canonical causes of cerebral venous thrombosis were summarized in the previous review in the *Journal*<sup>1</sup> and consist of disorders that cause systemic venous thrombosis, mainly a diverse group of hypercoagulable states that are usually evident before cerebral venous thrombosis occurs. These include adenocarcinoma, polycythemia vera, thrombocythemia, leukemia, sickle cell disease, and pregnancy or the postpartum period. Other causes, such as direct cranial trauma, neurosurgical procedures in the area of a venous sinus, and bacterial meningitis, are also apparent before cerebral venous thrombosis. Disorders that may be uncovered by exploring the cause of a cerebral venous thrombosis include antiphospholipid antibody syndrome and genetic forms of hypercoagulability, including factor V Leiden, protein S and protein C deficiency, prothrombin mutation, and hyperhomocysteinemia.

In a large registry series of patients with cerebral venous thrombosis with wide geographic representation, genetic thrombophilic disorders were reported in 22% of the study population and antiphospholipid antibodies in 6%.<sup>7</sup> Oral contraceptives and hormone-replacement therapy have long been known to be associated with cerebral venous thrombosis but have become much less common with the use of low-estrogen formulations. Cerebral venous thrombosis has been reported as a rare complication of cancer therapies such as tamoxifen, cisplatin, and L-asparaginase, as well as the erythropoietic hormone, epoetin alfa.

Disorders such as Behçet's syndrome account for cases in regions where the disorder is prevalent, and severe dehydration, usually from diarrheal illness in infants and children, causes cerebral venous thrombosis mainly in developing countries. In the first half of the 20th century, mastoiditis was a common cause of transverse sinus thrombosis ("otitic hydrocephalus") and is still a common cause in developing regions. In a case series of cerebral venous thrombosis in infants and children, acute systemic illnesses and head and neck infections were the primary causes.<sup>8</sup>

In addition, cerebral venous thrombosis can

be caused by three rare but pathophysiologically related hypercoagulable states: heparin-induced thrombocytopenia (HIT); autoimmune heparin-induced thrombocytopenia (aHIT), which is not triggered by heparin and includes an even more rare variant that also is not triggered by heparin (spontaneous HIT syndrome)<sup>9</sup>; and vaccine-induced immune thrombotic thrombocytopenia (VITT) (also known as thrombosis with thrombocytopenia syndrome [TTS]). These three entities are all associated with thrombosis, a low platelet count, and disseminated intravascular coagulation and are mediated by platelet-activating antibodies to platelet factor 4 (PF4). HIT, aHIT, and VITT are troublesome because they can be associated with thrombosis, primary hemorrhages, and secondary hemorrhage into areas of cerebral venous infarction.

The rare association of cerebral venous thrombosis with the two adenoviral vector vaccines against Covid-19 (1 case per 100,000 vaccine recipients for the ChAdOx1 nCoV-19 vaccine [AstraZeneca] and 1 per 1,000,000 for the Ad26.COV2.S vaccine [Johnson & Johnson/Janssen]), mainly in women, has been characterized by immune thrombotic thrombocytopenia mediated by platelet-activating antibodies to PF4.<sup>10</sup> In addition, cerebral venous thrombosis was reported in less than 1% of patients with severe acute respiratory syndrome coronavirus 2 (SARS-CoV-2) infection in one series<sup>11</sup> and in 2 of 22 Covid-19–related strokes in another series,<sup>12</sup> but in neither series did patients have thrombocytopenia and anti-PF4 antibodies.

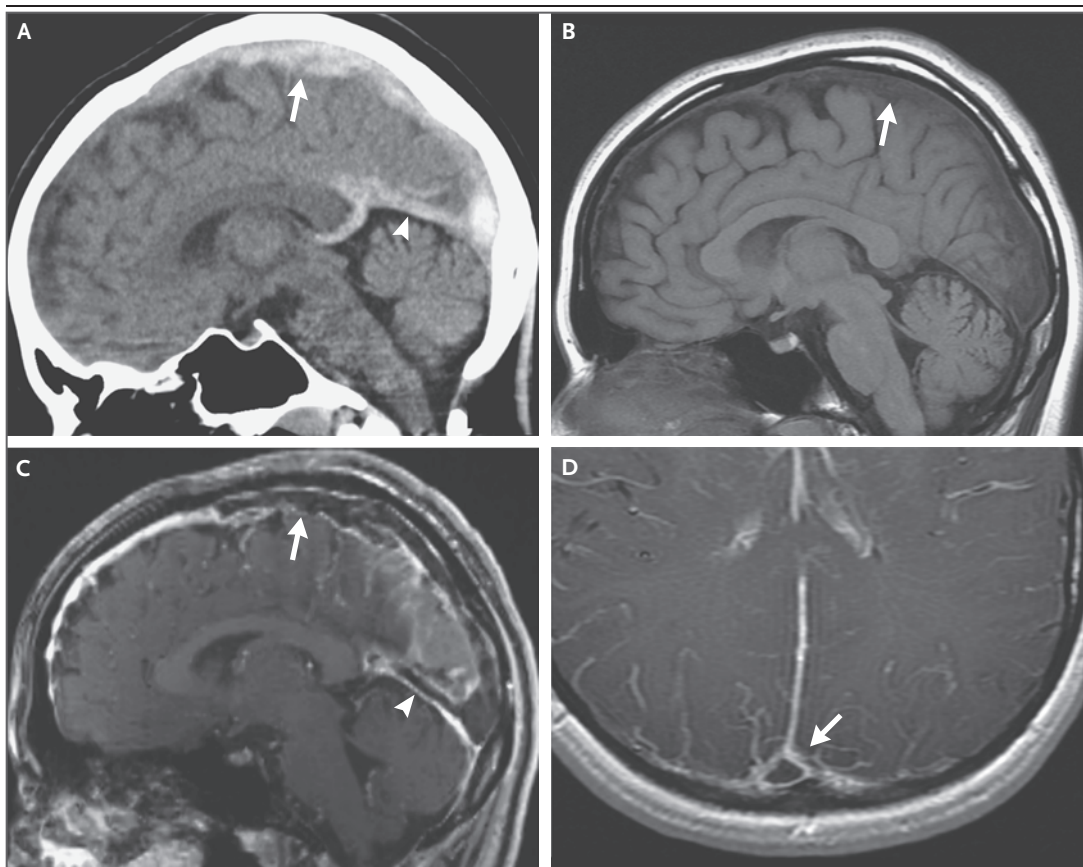
#### DIAGNOSIS

Computed tomography (CT) and magnetic resonance imaging (MRI) with contrast-enhanced venography are preferred methods for detecting dural venous sinus thrombosis and cortical vein thrombosis and have largely supplanted catheter-based angiography. The diagnostic finding is a segment of vein or sinus without blood flow. On unenhanced CT scans, the acute thrombus appears hyperdense (Fig. 1), and on unenhanced T1- and T2-weighted MRI scans, a normal flow void is absent at the location of the thrombus. Constitutional variation in the cerebral venous system, including atresias and functional stenoses in the transverse sinuses, artifactually simulate dural sinus occlusion. With CT and MRI

venography, the contrast column is interrupted at the location of the thrombus (Fig. 2). Dural wall enhancement without intrasinus enhancement produces an “empty delta” sign (Fig. 1), which has been described in CT studies<sup>14</sup> but also appears in contrast-enhanced MRI studies. Time-of-flight MRI venography does not require contrast material but is less sensitive than contrast-based imaging. Venous stroke appears as an edematous region with mixed infarction, hemorrhage, and contrast enhancement that does not respect arterial territories. In venous sinus thrombosis, particularly in cases accompanied by disseminated intravascular coagulation, cerebral hemorrhage may occur independent of the hemorrhagic venous infarction, and in rare cases, subarachnoid hemorrhage is the only imaging manifestation of cerebral venous thrombosis. If HIT, aHIT, or VITT is clinically suspected, special laboratory testing for anti-PF4 antibodies is indicated, along with an assay for platelet activation by the antibodies.

#### TREATMENT

Trials and studies of short- and long-term anticoagulant therapy have had mostly inconclusive results. Heparin has been widely used, even if there is hemorrhagic infarction, on the basis of a trial reported in 1991 involving 20 patients.<sup>15</sup> A Cochrane review in 2011 concluded that unfractionated heparin may be useful and safe but decried the lack of firm evidence.<sup>16</sup> A trial of low-molecular-weight heparin followed by warfarin showed no significant difference from placebo in preventing a poor outcome or death.<sup>17</sup> In a randomized trial comparing dabigatran with warfarin over a period of approximately 22 weeks in 120 patients, there were no recurrent venous thromboses, and the rates of bleeding were 1% and 3% in the two groups, respectively, with no significant difference in overall outcomes, perhaps because rates of recanalization of venous structures were high, at 60% and 67%, respectively.<sup>18</sup> Similarly, in a randomized trial involving 114 children treated with rivaroxaban after heparin or low-molecular-weight heparin, as compared with continued treatment with heparin or heparin plus warfarin, there were few outcome events, and no definite conclusions could be drawn regarding a composite outcome of systemic and cerebral venous thrombosis and bleed-



**Figure 1. Imaging Studies of Venous Sinus Thrombosis.**

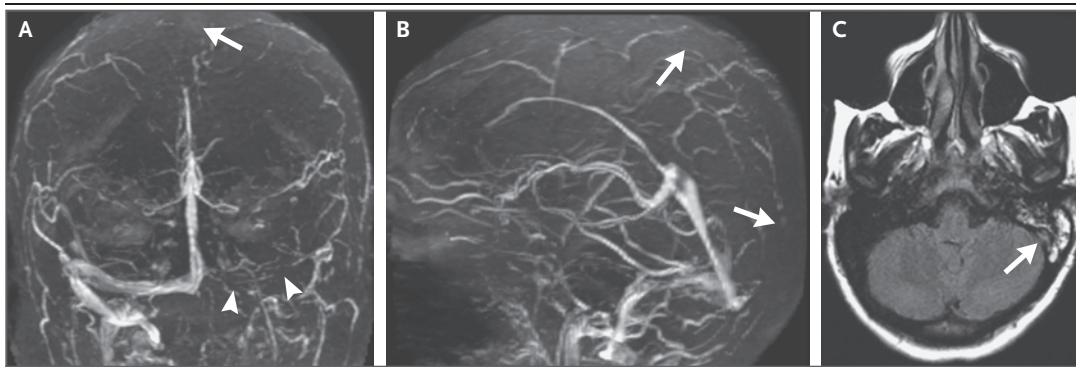
A midsagittal CT image of the brain without contrast material (Panel A) shows abnormal hyperattenuation in the superior sagittal sinus (arrow) and straight sinus (arrowhead). On a sagittal T1-weighted MRI scan without contrast material (Panel B), normal hypointense flow void is absent in the superior sagittal sinus (arrow). On a sagittal T1-weighted MRI scan obtained after intravenous administration of contrast material (Panel C), normal enhancement is absent in the occluded segment of the superior sagittal sinus (arrow) and straight sinus (arrowhead). An axial T1-weighted MRI scan obtained after intravenous administration of contrast material (Panel D) shows the “empty delta” sign (arrow) in the occluded segment of the superior sagittal sinus.

ing.<sup>19</sup> Antiphospholipid syndrome and inherited clotting disorders may require indefinite anticoagulation.

The above comments notwithstanding, heparin and platelet transfusions are avoided in all forms of immune thrombotic thrombocytopenia, including HIT and VITT.<sup>20</sup> In a series of five vaccine-related cases, intravenous immune globulin was used, and platelet counts rose despite initiation of low-molecular-weight heparin therapy.<sup>21</sup> Current expert recommendations are to avoid heparin (even when flushing catheters) in patients with VITT because of unpredictable effects on anti-PF4 antibodies and to use both intravenous immune globulin, to block the interaction of anti-PF4 antibodies with platelets, and

a nonheparin anticoagulant such as fondaparinux, argatroban, or a direct oral anticoagulant (rivaroxaban or apixaban).<sup>22</sup> Therapeutic plasma exchange with normal plasma as the replacement (rather than albumin) has also been used successfully in refractory cases.

Endovascular treatment of dural sinus thrombosis has been reported to have favorable results in case series, mainly for thrombectomy rather than thrombolysis,<sup>23,24</sup> but the studies have lacked a comparison group. A randomized trial of endovascular therapy as compared with heparin in 67 patients was stopped early. Patients were selected on the basis of a predicted poor outcome, and a variety of endovascular techniques were used, making conclusions uncertain.<sup>25</sup> Patients



**Figure 2. Venous Sinus Thrombosis with Mastoiditis.**

Time-of-flight MRI venography in the coronal (Panel A) and sagittal (Panel B) views shows that flow is absent in the superior sagittal sinus (arrows) and left transverse sinus (arrowheads). An axial T2-weighted, fluid-attenuated inversion recovery image (Panel C) shows opacification of the left mastoid air cells (arrow) due to mastoiditis. Images are courtesy of Ropper et al.<sup>13</sup>

with large venous infarctions and clinical or imaging evidence of brain herniation or raised intracranial pressure may benefit from decompressive hemicraniectomy. However, this approach has been studied less extensively in patients with cerebral venous thrombosis than in those with either arterial cerebral infarctions and brain edema or traumatic brain injury.

Anticonvulsant medication after a first seizure has generally been recommended on the basis of expert opinion, but prophylactic medication has not been endorsed. Medical therapy for raised intracranial pressure, such as glucocorticoids, acetazolamide, and mannitol, has not been adequately studied, and diuretics carry a theoretical risk of promoting thrombosis on the basis of dehydration. Treatment guidelines are addressed below.

#### OUTCOMES

In a registry study involving 624 patients with cerebral venous thrombosis, 8% had died at a median of 16 months, and 2% had recurrent sinus thrombosis.<sup>7</sup> According to small case series, patients with anti-PF4 antibodies, including those with cerebral venous thrombosis after ChAdOx1 nCoV-19 vaccination against Covid-19,<sup>10,20,21</sup> and children up to 18 years of age<sup>8</sup> may have poorer outcomes. In a series of 187 patients, most of whom had been treated with anticoagulants, cerebral venous thrombosis recurred in approximately 3% of the patients and extracranial thrombotic events, including pulmonary embolism, recurred in 10%.<sup>26</sup>

These outcome rates were similar to or higher than the rates in other series. One study led to the conclusion that women have better outcomes than men, probably because of different underlying causes of cerebral venous thrombosis.<sup>27</sup> Epilepsy as a long-term consequence of cerebral venous thrombosis has been infrequent, with almost all cases occurring after a seizure in the acute phase, but rates of this complication have ranged from 5 to 30% across series. The rare VITT syndrome may be associated with mortality up to 50% unless the syndrome is recognized quickly and appropriately treated.

#### GUIDELINES

European Stroke Organization guidelines from 2017 suggest initiating low-molecular-weight heparin as soon as possible after the diagnosis has been established (this does not apply to HIT or VITT), considering the use of decompressive craniectomy if intracranial pressure is raised, and using anticonvulsant agents if there have been seizures,<sup>28</sup> but the guidelines do not recommend glucocorticoids and acetazolamide for brain swelling. American Heart Association–American Stroke Association guidelines from 2011 provide an algorithm for the use of anticoagulant therapy, recommending full-dose unfractionated or low-molecular-weight heparin, followed by warfarin and acetazolamide, but not glucocorticoids, for raised intracranial pressure.<sup>29</sup>

## SUMMARY

The canonical clinical features and causes of cerebral venous thrombosis remain pertinent, and some new ones have emerged. Trials of anticoagulant therapy have used primary outcomes that included systemic venous thromboembolism and have had low event rates, making it difficult to draw conclusions about the choice or duration of anticoagulant therapy, but full-dose

low-molecular-weight heparin, followed by warfarin or direct oral anticoagulants for an unspecified period, appears to be an acceptable approach except in patients with HIT, aHIT, or VITT. Endovascular approaches to venous clot lysis and removal are promising and are being investigated.

No potential conflict of interest relevant to this article was reported.

Disclosure forms provided by the authors are available with the full text of this article at NEJM.org.

## REFERENCES

1. Stam J. Thrombosis of the cerebral veins and sinuses. *N Engl J Med* 2005;352:1791-8.
2. Coutinho JM, Gerritsma JJ, Zuurbier SM, Stam J. Isolated cortical vein thrombosis: systematic review of case reports and case series. *Stroke* 2014;45:1836-8.
3. Botta R, Donirpathi S, Yadav R, Kulkarni GB, Kumar MV, Nagaraja D. Headache patterns in cerebral venous thrombosis. *J Neurosci Rural Pract* 2017;8:Suppl 1:S72-S77.
4. Wasay M, Kojan S, Dai AI, Bobustuc G, Sheikh Z. Headache in cerebral venous thrombosis: incidence, pattern and location in 200 consecutive patients. *J Headache Pain* 2010;11:137-9.
5. Goyal G, Charan A, Singh R. Clinical presentation, neuroimaging findings, and predictors of brain parenchymal lesions in cerebral vein and dural sinus thrombosis: a retrospective study. *Ann Indian Acad Neurol* 2018;21:203-8.
6. Lindgren E, Silvis SM, Hiltunen S, et al. Acute symptomatic seizures in cerebral venous thrombosis. *Neurology* 2020;95(12):e1706-e1715.
7. Ferro JM, Canhão P, Stam J, Bousser M-G, Barinagarrementeria F. Prognosis of cerebral vein and dural sinus thrombosis: results of the International Study on Cerebral Vein and Dural Sinus Thrombosis (ISCVT). *Stroke* 2004;35:664-70.
8. deVeber G, Andrew M, Adams C, et al. Cerebral sinovenous thrombosis in children. *N Engl J Med* 2001;345:417-23.
9. Moores G, Warkentin TE, Farooqi MAM, Jevtic SD, Zeller MP, Perera KS. Spontaneous heparin-induced thrombocytopenia presenting as cerebral venous sinus thrombosis. *Neurology: Clinical Practice*. January 14, 2020 (<https://cp.neurology.org/content/early/2020/01/14/CPJ.0000000000000805>).
10. Greinacher A, Thiele T, Warkentin TE, Weisser K, Kyrle PA, Eichinger S. Thrombotic thrombocytopenia after ChAdOx1 nCoV-19 vaccination. *N Engl J Med* 2021;384:2092-101.
11. Siegler JE, Cardona P, Arenillas JF, et al. Cerebrovascular events and outcomes in hospitalized patients with COVID-19: the SVIN COVID-19 Multinational Registry. *Int J Stroke* 2020 September 30 (Epub ahead of print).
12. Sweid A, Hammoud B, Bekelis K, et al. Cerebral ischemic and hemorrhagic complications of coronavirus disease 2019. *Int J Stroke* 2020;15:733-42.
13. Ropper AH, Samuels MA, Klein JP, Prasad S. Adams and Victor's principles of neurology. 11th ed. New York: McGraw Hill, 2019:891.
14. Buonanno FS, Moody DM, Ball MR, Laster DW. Computed cranial tomographic findings in cerebral sinovenous occlusion. *J Comput Assist Tomogr* 1978;2:281-90.
15. Einhäupl KM, Villringer A, Meister W, et al. Heparin treatment in sinus venous thrombosis. *Lancet* 1991;338:597-600.
16. Coutinho J, de Bruijn SF, Deveber G, Stam J. Anticoagulation for cerebral venous sinus thrombosis. *Cochrane Database Syst Rev* 2011;8:CD002005.
17. de Bruijn SF, Stam J. Randomized, placebo-controlled trial of anticoagulant treatment with low-molecular-weight heparin for cerebral sinus thrombosis. *Stroke* 1999;30:484-8.
18. Ferro JM, Coutinho JM, Dentali F, et al. Safety and efficacy of dabigatran etexilate vs dose-adjusted warfarin in patients with cerebral venous thrombosis: a randomized clinical trial. *JAMA Neurol* 2019;76:1457-65.
19. Connor P, Sánchez van Kammen M, Lensing AWA, et al. Safety and efficacy of rivaroxaban in pediatric cerebral venous thrombosis (EINSTEIN-Jr CVT). *Blood Adv* 2020;4:6250-8.
20. Scully M, Singh D, Lown R, et al. Pathologic antibodies to platelet factor 4 after ChAdOx1 nCoV-19 vaccination. *N Engl J Med* 2021;384:2202-11.
21. Schultz NH, Sørvoll IH, Michelsen AE, et al. Thrombosis and thrombocytopenia after ChAdOx1 nCoV-19 vaccination. *N Engl J Med* 2021;384:2124-30.
22. Greinacher A, Selleng K, Warkentin TE. Autoimmune heparin-induced thrombocytopenia. *J Thromb Haemost* 2017;15:2099-114.
23. Siddiqui FM, Dandapat S, Banerjee C, et al. Mechanical thrombectomy in cerebral venous thrombosis: systematic review of 185 cases. *Stroke* 2015;46:1263-8.
24. Ilyas A, Chen C-J, Raper DM, et al. Endovascular mechanical thrombectomy for cerebral venous sinus thrombosis: a systematic review. *J Neurointerv Surg* 2017;9:1086-92.
25. Coutinho JM, Zuurbier SM, Bousser MG, et al. Effect of endovascular treatment with medical management vs standard care on severe cerebral venous thrombosis: the TO-ACT randomized clinical trial. *JAMA Neurol* 2020;77:966-73.
26. Palazzo P, Agius P, Ingrand P, et al. Venous thrombotic recurrence after cerebral venous thrombosis: a long-term follow-up study. *Stroke* 2017;48:321-6.
27. Coutinho JM, Ferro JM, Canhão P, et al. Cerebral venous and sinus thrombosis in women. *Stroke* 2009;40:2356-61.
28. Ferro JM, Bousser M-G, Canhão P, et al. European Stroke Organization guideline for the diagnosis and treatment of cerebral venous thrombosis — endorsed by the European Academy of Neurology. *Eur J Neurol* 2017;24:1203-13.
29. Saposnik G, Barinagarrementeria F, Brown RD Jr, et al. Diagnosis and management of cerebral venous thrombosis: a statement for healthcare professionals from the American Heart Association/American Stroke Association. *Stroke* 2011;42:1158-92.

Copyright © 2021 Massachusetts Medical Society.