

# Cervical spine clearance in the pediatric trauma population: What you need to know

Katie W. Russell, MD, Anastasia Kahan, MD, and R. Scott Eldredge, MD

**ABSTRACT:** Evaluation of the pediatric cervical spine after blunt trauma is an important topic that requires special consideration. In this article, we will review background information and differences between the pediatric and adult cervical spine. We will then give up-to-date guidance on best practice for screening and clearance of the cervical spine in children, including the advantages and disadvantages of different imaging techniques. Finally, we will introduce current topics of study and surmise what changes or innovations may be coming in the future. (*J Trauma Acute Care Surg.* 2025;98: 541–549. Copyright © 2024 Wolters Kluwer Health, Inc. All rights reserved.)

**KEY WORDS:** Cervical vertebrae/injury; Pediatrics; trauma; screening guideline.

Cervical spine injuries in children are serious; however, these types of injuries are uncommon. In the United States, millions of children are evaluated every year for possible cervical spine injury, but less than 1% are diagnosed with a clinically significant cervical spine injury.<sup>1–3</sup> While missing an injury could potentially result in devastating outcomes, the overwhelming fear of missing an injury resulting in overscreening and treatment may also have consequences. Emergency medical services providers are trained to almost ubiquitously apply cervical collars to patients who have endured trauma, and first-line hospital providers may be overly cautious when evaluating the cervical spine in children. Robust research and organized implementation are necessary to help direct management of the pediatric cervical spine.

There are notable differences when thinking about the pediatric cervical spine after blunt trauma compared with their adult counter parts. The first is that younger children do have different injury patterns than adults. Young children have relatively large heads, incomplete ossification, and a reliance on ligamentous structures for stability. Children younger than 9 years have a higher percentage of axial injuries (occiput-c2) compared with adults who more frequently have subaxial (c3–7) injuries, but by the age of 9 years, research has shown that injury patterns closely resemble those of adults.<sup>4–6</sup> Also noteworthy is the inability of preverbal children to actively participate in a physical examination causing some providers anxiety.<sup>7</sup>

Perhaps most importantly is the consideration of radiation risk in children. As providers of pediatric trauma care, we are constantly weighing the risks and benefits of ionizing radiation

on the individual patient. In adult trauma, the risk of ionizing radiation from imaging is far lower than the risk of missing an injury by forgoing imaging. In pediatric trauma, it is our responsibility to encourage proper imaging stewardship to dissuade unnecessary imaging in low-risk patients and obtaining appropriate imaging in those at high or medium risk for injury. However, it can be difficult to categorize patients into injury risk strata. We must identify patients who need imaging, use the appropriate imaging modality, and help design imaging protocols to acquire excellent images with as low as reasonably achievable amounts of radiation. While the exact risk of radiation is difficult to define, Pearce et al.<sup>8</sup> looked at a sample of children who underwent computed tomography (CT) evaluation in England, Wales, or Scotland and found that a cumulative dose of 50 to 60 mGy triples the risk of leukemia and brain tumors. Other studies describe the incidence of developing cancer as 24% higher among children who had a CT than those who did not, and the lifetime risk of thyroid cancer is 78% higher in persons who had a single cervical spine CT as a child.<sup>8–10</sup> An article by the American Pediatric Surgical Association estimated one cancer-related fatality per every 1,000 CTs performed in young children.<sup>11</sup> In summary, while the injured patient needs a thorough evaluation, thought and deliberation should be taken on who requires imaging to limit and avoid ionizing radiation whenever possible to thwart long term risks of radiation exposure.

## CERVICAL COLLAR

Cervical immobilization following blunt trauma has entered the realm of surgical dogma. In many areas of the country, emergency medical services providers are trained to routinely immobilize trauma patients with cervical-collars (c-collars) and backboards to stabilize a potential spinal injury.<sup>12</sup> A c-collar undoubtedly has the effect of reminding healthcare workers to be careful when transferring and handling the injured patient. While a campaign to eliminate c-collars is perhaps ill advised, it is important to recognize the limited evidence to support the use of these devices. There are reports that question the transcendent nature of the cervical collar. Hauswald et al.<sup>13</sup> compared cervical immobilization in New Mexico with a lack of

Submitted: July 14, 2024, Revised: October 13, 2024, Accepted: July 22, 2024, Published online: November 28, 2024.

From the Division of Pediatric Surgery, Department of Surgery (K.W.R., A.K.), University of Utah, Salt Lake City, Utah; and Division of General Surgery, Department of Surgery (R.S.E.), Mayo Clinic, Phoenix, Arizona.

Address for correspondence: Katie W. Russell, MD, Division of Pediatric Surgery, Department of Surgery, University of Utah, 100 N Mario Capecchi Dr, Ste 3800, Salt Lake City, UT 84113; email: katie.russell@hsc.utah.edu.

DOI: 10.1097/TA.0000000000004460

*J Trauma Acute Care Surg*  
Volume 98, Issue 4

immobilization in Malaysia and concluded that immobilization was at least of no value and potentially harmful. The study design is somewhat contentious but thought provoking.<sup>13</sup> Furthermore, Horodyski et al.<sup>14</sup> performed motion analysis on five lightly embalmed cadavers after creating unstable cervical spine injuries and found that the c-collar did not limit motion in any way. In addition, there are reports that cervical collars can aggravate atlanto-occipital dislocation (AOD) by adding external extension.<sup>15</sup> When an AOD injury pattern is detected, sand bag immobilization is preferred over a rigid collar.

External immobilization devices harbor other risks as well. Todd Maxon, a renowned pediatric trauma surgeon, is quoted as saying “do not even think about putting a c-collar on me,” after enduring his own motorcycle crash because of his fear and anxiety of respiratory and airway compromise related to a device he was sure he did not need. Risks of external cervical immobilization include difficulties with airway management, reduced respiratory capacity, increased intracranial pressure, patient discomfort and anxiety, and c-collar-associated pressure ulceration.<sup>16–19</sup> Increased intracranial pressure is a significant concern in patients with traumatic brain injury.<sup>20</sup> Chan et al.<sup>21</sup> reported cervical collar complications in 10% of pediatric patients in their retrospective cohort study and associated these complications with longer time to cervical spine clearance and higher injury severity. Among adults, there are reports of pressure injuries in 7% to 38% of trauma patients.<sup>22,23</sup> Melhado et al.<sup>19</sup> recently published a retrospective review of trauma patients in the Western Pediatric Surgery Research Consortium (WPSRC) reporting only 32 stage 2 and greater pressure injuries out of nearly 50,000 patients. The pressure injuries were typically in children admitted to the intensive care unit and with documented cervical spine injuries. They also observed a median time of 11 days posttrauma to detection of c-collar-associated pressure ulcerization.<sup>19</sup> While the exact prevalence of these injuries is likely driven by local milieu, the Agency for Healthcare Research and Quality has declared pressure ulcers as never events. Multidisciplinary concerted efforts are needed to prevent pressure injuries secondary to cervical immobilization whenever possible. It is important to understand the limitations of the c-collar and use appropriate judgment when managing patients in these devices.

## CERVICAL SPINE SCREENING

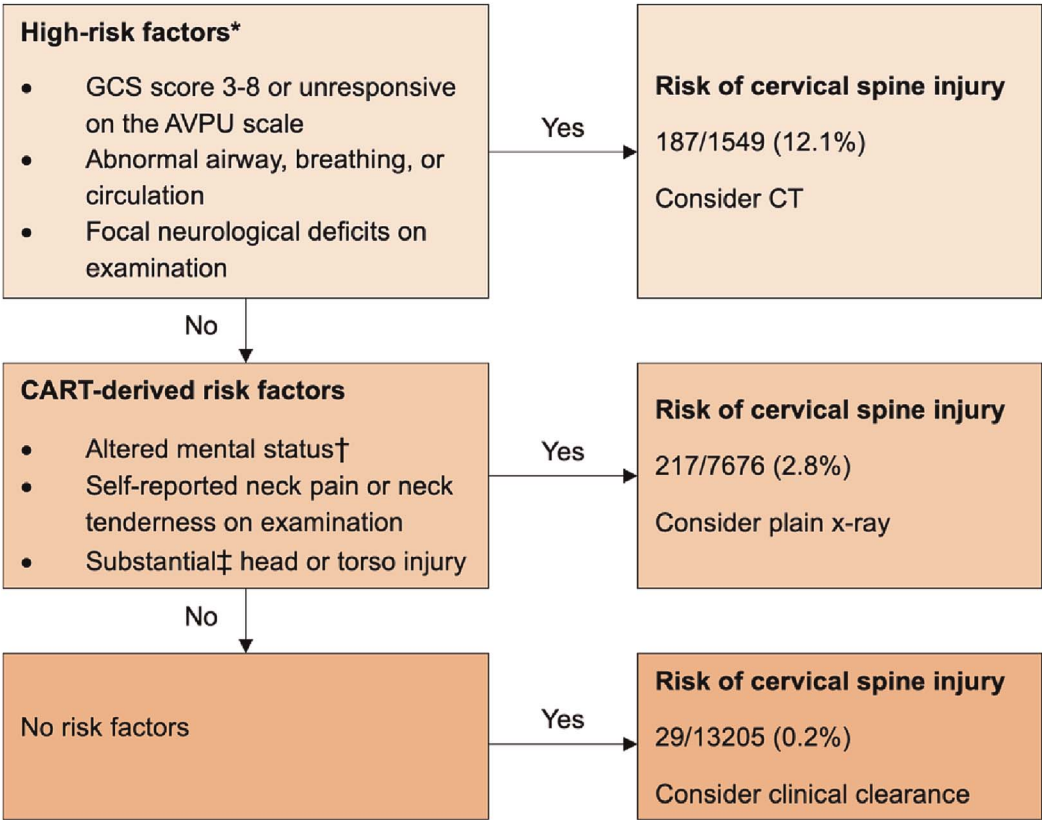
All blunt trauma patients need to be considered for cervical spine injury; however, there is a dilemma in which patients can be cleared clinically by physical examination and those who need an imaging adjunct as part of clearance. Several decision rules to guide imaging have been crafted and validated in adults with almost universal implementation. The National Emergency X-ray Utilization Study prediction rule was introduced in 2000 and has been shown to have 100% sensitivity when used in the emergency department for adult trauma patients.<sup>24,25</sup> However, the validity of National Emergency X-ray Utilization Study among children has been called into question as the original study only included 3,065 children, and of those, only 30 were found to have cervical spine injuries with no injuries in the younger than 2 years of age cohort.<sup>1,24–28</sup> While this decision-making tool has been applied to children across the

United States, the quality of research specific to children is questionable.<sup>29,30</sup> Similarly, the Canadian C-spine Rule has excellent sensitivity in alert adults, but the applicability to children is unknown.<sup>31</sup> Most projects dedicated to defining a rule specific to children have been limited by single center design, and small numbers.<sup>28</sup> A retrospective multicenter cohort, PEDSPINE (Clinical Clearance of the Cervical Spine in Blunt Trauma Patients Younger Than 3 Years), evaluated a scoring system for children younger than 3 years, but with a sensitivity of 76%, the utility is limited.<sup>7</sup> For the last several years, the Pediatric Emergency Care Applied Research Network (PECARN) has been systematically working on a pediatric cervical spine injury risk assessment tool.<sup>32–34</sup>

The PECARN prediction rule for cervical spine imaging was published in June of 2024 (Fig. 1). This study included 22,430 children across 9 pediatric emergency departments, with half in the derivation cohort and half in the validation cohort. A total of 433 (1.9%) had confirmed cervical spine injuries that required surgical intervention or hospital admission. During the first phase of this study, the researchers identified high risk indicators of cervical spine injury, which included altered mental status (GCS score of <9 or unresponsive on Alert, Verbal, Pain, Unresponsive scale), abnormal airway, breathing or circulation, and focal neurologic deficits including weakness, paresthesia, and numbness. The risk of a significant cervical spine injury was 12.1% in patients with the above risk factors, and in the presence of these findings, a cervical CT is recommended. They found a second group of indicators pertaining to a nonnegligible risk of cervical spine injury: reported neck pain, altered mental status (GCS score of 9–14; verbal or pain on Alert, Verbal, Pain, Unresponsive scale; or other signs of altered mental status), substantial head injury, substantial torso injury, and midline neck tenderness. In this group, the risk of significant injury was 2.8%, and in the presence of these risk factors, we recommend cervical x-ray. When the PECARN decision-making tool was applied for validation, it was determined to have a sensitivity of 94.3%, a specificity of 60.4%, and a negative predictive value of 99.9% in the detection of cervical spine injury in children. A total of 29 children with cervical spine injuries were missed by the rule, but none of these children required surgical intervention, and on retrospective analysis, most actually did have risk factors documented. By applying this rule, the use of CT would have been reduced by more than 50% without missing relevant injuries or increasing the number of x-rays.<sup>3</sup> The PECARN prediction rule is a well-executed, high-quality study in a field with a paucity of quality research. The authors support rapid implementation of this rule followed by monitored assessment.

## CERVICAL SPINE IMAGING

Radiologic interpretation of the cervical spine in children can be challenging because of morphologic changes of the maturing pediatric cervical spine. Several studies have highlighted the importance of subspecialty training in radiology and the importance of pediatric overreads when interpreting cervical spine images.<sup>35,36</sup> Hassan et al.<sup>37</sup> specifically looked at the differences among radiologists in interpreting cervical spine CTs and concluded that pediatric subspecialization improved the sensitivity



**Figure 1.** The PECARN cervical spine injury prediction rule.<sup>5</sup> Clinical algorithm for cervical spine imaging in children after blunt trauma predicated on the PECARN cervical spine injury prediction rule. Data are n/N (%). The risk of cervical spine injury was calculated from the combined derivation and validation cohorts using eligible children's risk factor data as recorded electronically by attending emergency department clinicians. High-risk factors were used to determine when CT is warranted for a child presenting to an emergency department after blunt trauma, and CART-derived risk factors were used to determine when plain x-rays were warranted. \*High-risk factors confirmed using bivariable Poisson regression with robust error estimates. †Altered mental status was defined as GCS score of 9 to 14, verbal or pain on AVPU, or other signs of altered mental status. ‡Substantial injuries were defined as those that warranted inpatient observation or surgical intervention. AVPU, Alert, Verbal, Pain, Unresponsive scale of consciousness; CART, classification and regression tree analysis; GCS, Glasgow Coma Scale.

of identifying cervical spine injuries in children. Pediatric subspecialists were more likely to identify injuries at the craniocervical junction. Knowledge of pediatric-specific injury patterns and developmental nuances heightens awareness to subtle imaging findings.<sup>37</sup> It is important to highlight that pediatric-specific institutions may have resources not available to adult trauma centers or general community hospitals that care for most pediatric trauma patients.

Current literature documents varying utilization of different imaging modalities for cervical spine evaluation. Ross et al.<sup>38</sup> reported on cervical spine imaging practices in 35 children's hospitals using the Children's Hospital Association's Pediatric Health Information System. They identified 25,238 pediatric patients evaluated in the emergency department for a traumatic injury and found that 66% of pediatric trauma patients underwent cervical spine x-ray alone, while 24% underwent CT alone. When stratified by age, children who were younger than 3 years and those between 15 and 17 years old were more likely to be evaluated with CT. Disturbingly, throughout the duration of the study, the use of CT increased by approximately 1.4% per year, while the use of x-ray decreased by 1.6% per year. The rate of

x-ray or CT alone across hospitals ranged from 7.6% to 91.2% and 2.1% to 85.9%, respectively. The use of magnetic resonance imaging (MRI) did not change over the study duration and was obtained in approximately 5% of pediatric trauma patients.<sup>38</sup> Massoumi et al.<sup>39</sup> also observed a significant variation in the imaging modality used to evaluate the cervical spine using the Trauma Quality Improvement Program database. When stratifying by trauma center designation, level I trauma centers were less likely to use CT in younger children than level II or III trauma centers. In addition, pediatric-designated trauma centers were less likely to use CT and more likely to use MRI.<sup>39</sup> Kim et al.<sup>2</sup> similarly found that pediatric trauma centers were less likely to use CT for cervical spine evaluation. Hereinafter, we highlight the test characteristics, the benefits, and the downsides of each imaging modality.

**Plain Film Radiography**

X-ray is an effective screening tool for pediatric cervical spine injury when a patient presents with normal mental status and can actively participate in a clinical examination, including alert infants and toddlers. X-ray provides an advantage as

radiographs can be easily obtained, sometimes in the trauma bay, and have a tenth of the radiation exposure compared with CT.<sup>40,41</sup> The sensitivity of x-ray in identifying cervical spine injuries has variable report, ranging from 56% to 100%. This variation is likely due to different factors including technique, quality, pretest probability, and experience of the radiologist and radiographic technician.<sup>26,40,42,43</sup> A lateral view with the patient in a supine position has a higher sensitivity for detecting injury compared with anteroposterior and odontoid views. The standard of care for cervical spine x-ray is a lateral image, which includes all seven vertebrae from the base of the skull to the top of the first thoracic vertebrae.<sup>44,45</sup> In obtunded children, the role of the x-ray is limited because of a higher prevalence of cervical spine injury and a lower test sensitivity.<sup>46</sup> In 2024, Jeong et al.<sup>47</sup> found that x-ray only identified 71% of AODs and 50% of the atlanto-axial dislocations in children with a GCS score of <9, in their single-center study.

Despite the benefits in children, utilization of cervical spine x-ray has crept out of many adult trauma centers and community hospitals, as this practice has largely been abandoned in adults given anatomic considerations such as degenerative joint disease and a relatively lower risk of radiation with CT.<sup>39,48,49</sup> The literature suggests that the use of x-ray alone for cervical spine evaluation and clearance is insufficient in adult trauma patients.<sup>49,50</sup> Fisher and Young<sup>49</sup> recently observed that 20% of adult trauma patients who underwent both x-ray and CT had a fracture that was missed on x-ray. Furthermore, technological advancements allow for CT images to be obtained more expeditiously, negating this historic benefit of plain x-ray.<sup>49,51</sup> Given that x-ray is not routinely obtained in the evaluation of adult trauma patients, these centers may be more reluctant when evaluating a pediatric patient. Similarly, the radiologists may be less comfortable with this technique. Despite its limitations, x-ray requires promotion in appropriate pediatric patients to reduce the risks with ionizing radiation in children with a low probability of cervical spine injury.

## Computed Tomography

The role of CT in evaluating and clearing the pediatric cervical spine is controversial. The first concern is radiation-related malignancies, and the second is a prevailing trepidation of CTs ability to identify clinically significant ligamentous injuries, as children are more prone to this type of injury.<sup>8,9,52</sup> Radiation-induced neoplasia is a documented risk of CT, including a risk of fatal malignancy in younger children.<sup>53,54</sup> In comparison with x-ray, CT is estimated to deliver 90 to 200 times the radiation dose.<sup>55,56</sup> Computed tomography is readily available, fast, and used widely in adult trauma evaluations. There is no doubt that its use should be limited to critical pediatric patients with a high risk of injury. The controversy is whether CT is satisfactory to clear a pediatric cervical spine in the absence of a reliable physical examination because of simultaneous head injury.

In 2023, Russell et al.<sup>57</sup> conducted a single-center review to assess the utility of CT in diagnosing clinically significant pediatric cervical spine injury, defined as an injury that required surgical fixation or halo placement. Over a 10-year period, they identified 2,306 patients who underwent CT evaluation and reported a 100% sensitivity of CT in identifying clinically significant cervical spine injuries. Among patients with a normal CT, 12% had further evaluation with MRI, and 17 ligamentous injuries

were identified, but on post hoc review, none were unstable, and none required surgical stabilization.<sup>57</sup> Similarly, Derderian et al.<sup>58</sup> retrospectively observed that CT reliably identified all unstable (disruption of two or more contiguous spinal columns) cervical spine injuries among their cohort of pediatric trauma patients who had both CT and MRI. Approximately 50% of their cohort with a normal CT was found to have a stable injury on MRI, and several of these children were treated with a c-collar at discharge, but they question the necessity of that treatment.<sup>58</sup> Gargas et al.<sup>59</sup> also reported zero missed unstable injuries after upgrading their CT scanner in 2005. Qualls et al.<sup>60</sup> evaluated 63 head-injured patients with a GCS score of <8 with both a CT and MRI and found no unstable injuries that were missed by CT. Azizi et al.<sup>61</sup> concluded that, in 212 negative CTs, MRI did not discover any missed injuries. The evidence is mounting that CT is highly sensitive for diagnosing injuries that need surgical stabilization.

In contrast to the above work, multiple groups including unpublished data out of the WPSRC presented at the American Academy of Pediatrics document significant injuries that have been missed by CT and identified on MRI.<sup>62,63</sup> Stephenson et al.<sup>62</sup> found the sensitivity of the CT to be closer to 95%, with three missed injuries at the craniocervical junction that were identified on MRI. On review of those CTs with missed injuries, each patient had an associated retroclival hematoma visible on both sagittal and coronal views. To understand the clinical significance of a retroclival hematoma, the authors reviewed the imaging of all patients with craniocervical junction injuries. Overall, they found that 72% (8 of 11) of patients with a craniocervical junction injury had an associated retroclival hematoma present on CT. In the remaining three patients without a retroclival hematoma, the craniocervical injury was apparent on CT.<sup>62</sup> It is important to note that there are important findings on head CT that may indicate cervical spine injury, most notably retroclival blood, which is a harbinger for cervical spine injury and warrants further imaging with MRI.

While recent studies are compelling in favor of CT for diagnosing clinically significant cervical spine injuries, they should be interpreted with caution. First, each was conducted at a free-standing level I pediatric trauma center, limiting the generalizability.<sup>57–61</sup> Level I pediatric trauma centers have specific resources for managing the unique physiology and anatomy of children that may not be available at all trauma centers, including board-certified pediatric radiologists.<sup>37,64</sup> Finally, there are no sufficiently powered prospective studies that determine the test characteristics of CT and MRI for screening and clearance of the pediatric cervical spine.

## Magnetic Resonance Imaging

Magnetic resonance imaging is the most sensitive diagnostic tool for detecting cervical ligamentous and other soft tissue injuries in pediatric patients, but it has the potential to miss bony injuries.<sup>27</sup> Magnetic resonance imaging has been reported to identify clinically unstable injuries, such as AOD, more reliably than CT.<sup>63</sup> However, MRI may be overly sensitive and pick up insignificant injuries, leading to confusion and potentially unnecessary immobilization. Magnetic resonance imaging lacks radiation and is thus ideal for pediatric patients, but it is limited by the time and sedation required to obtain images and by the reduced



availability at major trauma centers.<sup>65,66</sup> Few centers do have 24-hour access to MRI and are using this technology in combination with x-ray as a screening tool for cervical spine injuries.<sup>30</sup>

Utilization of MRI is more expensive and has a longer acquisition time than CT, which may result in the need for anesthesia and placement of an airway.<sup>65,66</sup> Melhado et al.<sup>67</sup> reported the median time for image acquisition ranges from 26 to 51 minutes. This is an extended trip out of the intensive care unit for critically ill patients and long enough that younger kids may require intubation and sedation. In a recent study, Lee et al.<sup>41</sup> observed that over half of their pediatric cohort who underwent MRI for cervical spine evaluation required an airway, and 57% were intubated specifically for MRI, with one serious adverse event associated with intubation. Magnetic resonance imaging was delayed for greater than 48 hours in approximately 20% of patients, meaning prolonged immobilization time in a c-collar.<sup>41</sup> This may be extended even longer in patients who have metallic neuromonitoring devices in place. The incidence of an adverse event during MRI for cervical spine evaluation is 0.8% to 1.3%.<sup>68,69</sup> Magnetic resonance imaging plays a role in cervical spine injuries for evaluation of the spinal cord, specific injuries to the discoligamentous complex, the presence of compressive hematomas, and for operative planning, but its utility in screening and clearance in patients with negative high quality bone imaging remains a question.<sup>57,61</sup>

## CERVICAL SPINE CLEARANCE

Following the evaluation of the cervical spine in blunt pediatric trauma, it is critical to efficiently clear the cervical spine and remove the c-collar if an injury is not identified or suspected. Clinical clearance is accomplished with a physical examination of the cervical spine, which consists of visualization and palpation of each cervical vertebra. In addition, patients should demonstrate pain-free full range of motion in active cervical flexion, extension, lateral flexion, and rotation. Clinical clearance can be safely conducted in the appropriate neurologically intact pediatric patient, including preverbal children. A combination of a normal clinical examination and negative imaging interpreted by a qualified radiologist is an undisputed method of cervical spine clearance. There are, however, several clinical circumstances when controversy exists regarding the appropriateness of clearance.

Pannu et al.<sup>29</sup> reported underutilization of written protocols for evaluation and clearance of the pediatric cervical spine, with only 46% of centers using a written protocol. A recent systematic review found wide variation among clearance protocols in pediatric trauma, observing variation in the type of imaging used for screening and variation in clearance practices.<sup>38,39,70</sup> The Pediatric Cervical Spine Clearance Working Group published a consensus statement in 2019 in an attempt to promote the implementation of a standardized cervical spine clearance pathway for pediatric blunt trauma,<sup>71</sup> but despite this, the use of a standardized protocol has not been successfully adopted by many trauma centers.<sup>30,70</sup> While details may be up for debate, development, implementation, and compliance of a protocol are associated with a reduction in the number of missed injuries and unnecessary radiation.<sup>72</sup> After implementation of a cervical spine protocol, trauma centers have reported a 23% to 57% reduction in cervical spine CTs.<sup>73,74</sup> Protocols have also been shown to expedite the timing of cervical spine clearance in pediatric trauma.<sup>73</sup>

Furthermore, protocols have the potential to reduce hospital charges and costs.<sup>73,74</sup> Pennell et al.<sup>73</sup> estimated an annual savings of almost \$400,000 because of a reduction in radiographic studies when applying the PCSCWG guideline, without any missed injuries. While protocols may vary locally, it is important that hospitals create a standardized evaluation and clearance process for the pediatric cervical spine. The PCSCWG protocol is a well-written expert consensus and the best currently published protocol.

## Alert Patients

One group of patients that needs mention are those who get a cervical spine x-ray as part of cervical spine evaluation in the emergency department, and although imaging is normal, they have persistent posterior midline tenderness at the time of anticipated discharge. This scenario leaves trauma surgeons and the emergency department with a clinical conundrum where they can either obtain (1) CT, (2) MRI, and (3) spine consult or (4) discharge the patient in cervical spine immobilization. Prior to any of the aforementioned options, we would guide providers to clarify that the x-ray is of good quality and perhaps discuss with the radiologist that the child has continued midline tenderness, as our radiology colleagues often do not have full clinical patient information at the time of radiologic interpretation. To minimize further radiation and to use resources appropriately, several institutions have documented their experiences of discharging these children in c-collar precautions with planned follow-up. Dorney et al.<sup>75</sup> evaluated 307 pediatric patients sent home from the emergency department in a hard collar, and 85% had the collar cleared at a median of 10 days postinjury. In those with persistent pain after the first visit, MRI was used to diagnose 10 children with either congenital anomalies or small injuries; none of which required surgical intervention.<sup>75</sup> Hewes et al.<sup>76</sup> evaluated 98 children sent home in a c-collar and found that half of these families chose to discontinue the collar without the recommended follow-up. There was one patient with severe persistent pain 2 weeks after trauma and was found to have an odontoid fracture that required fusion on advanced imaging. In retrospect, the radiologist had commented that the odontoid was not well visualized on the initial x-ray. The authors conclude that the practice is safe but emphasize the need for specialty follow-up and repeat imaging in cases of persistent pain after discharge.<sup>76</sup>

Alert patients who are admitted to the hospital with negative imaging but persistent pain is another group that needs attention. The concept of next day reevaluation is important and has been shown to limit radiation without increasing hospital length of stay.<sup>77</sup>

## Obtunded Patients

While clearance of the pediatric cervical spine in an awake and correlative patient is not controversial, clearance in an obtunded pediatric patient leaves room for debate. One reason for this controversy is that there is no agreement among trauma surgeons on the definition of obtunded. In addition, the debate centers around whether it is safe to clear a pediatric spine based on a normal CT alone or if an MRI is required. In 2015, the Eastern Association for the Surgery of Trauma published a guideline, Cervical Spine Collar Clearance in the Obtunded Adult Blunt Trauma Patient.<sup>65</sup> Many centers changed their practices and began clearing the adult c-spine based on normal CTs

without the addition of an MRI. This guideline was based on a review of 1,017 patients with a 9% incidence of stable ligamentous injury detected on MRI and a 0% incidence of unstable ligamentous injuries not detected by CT. There were no children included in this study.<sup>65</sup> Given the unique anatomical considerations in children, these findings in adults require careful study prior to their application in the pediatric population. That said, this guideline is being applied to children or at least adolescents at some centers nationally.<sup>30</sup>

The current recommendation from PCSCWG guides clinicians to obtain an MRI in the setting of an obtunded child with a normal CT.<sup>71</sup> These recommendations are in part based on data from prior decades with older imaging technology.<sup>59,71</sup> Technologic advancements have led to the development of the multidetector CT, a modality that provides sagittal and coronal reconstructions using 64-slice helical scans. The imaging quality has proven to be far superior to its historic single-slice CT counterpart.<sup>59</sup> However, at the time of this publication, the authors recommend following this algorithm curated by expert opinion (Fig. 2). We believe that this is the best published algorithm; it is supported by the Pediatric Trauma Society, there is vocal concern about missed injuries on CT in obtunded patients, and there is a lack of prospective data documenting the safety of clearance based on a normal CT alone.

## SPECIAL CONSIDERATIONS

One group that requires special consideration is the nonaccidental trauma population. In children with abusive head trauma, there is concern for concomitant cervical spine injury; however, the incidence of unstable clinically significant

injury is reported as quite low. Increased MRI utilization has led to increased immobilization without identification of severe injuries requiring stabilization.<sup>78,79</sup> It is important to collaborate with child abuse specialists because, while MRI may not impact surgical care, identification of injuries on MRI may be important when considering legal ramifications of child abuse.

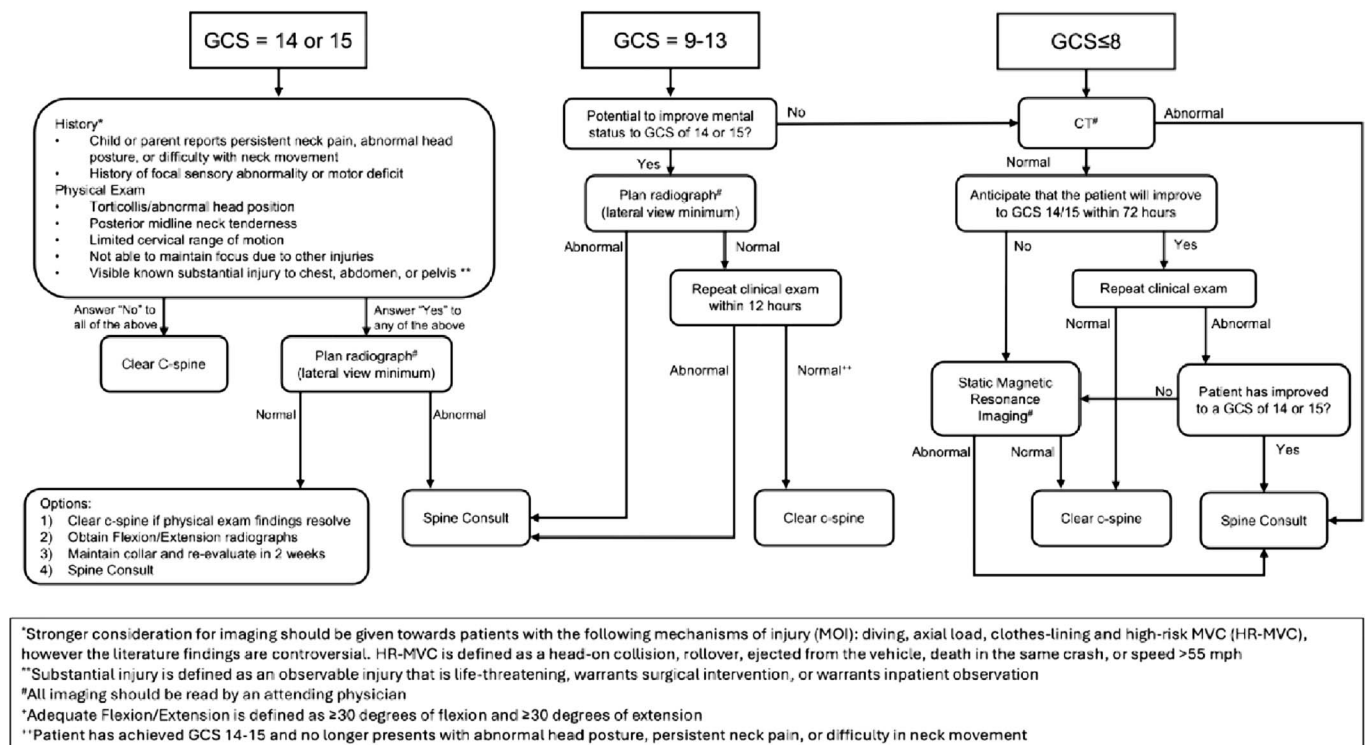
## ON THE HORIZON

The WPSRC and the Western Trauma Association are currently enrolling in the Western Pediatric Cervical Spine Study. This study was modeled after a 2017 study by Inaba et al.<sup>80</sup> prospectively evaluating cervical spine clearance practices in adults. In that study, the sensitivity of CT for clinically significant injury was 98.5%, with the only misses in elderly patients with neurologic symptoms.<sup>80</sup> The aim of the current study is to determine the sensitivity of CT in the adolescent and pediatric populations. This study is anticipated to complete enrollment in 2026.

## Limited Sequence MRI

One major limitation of MRI is the time required and potential need for sedation with general anesthesia to obtain images without motion artifact. This limitation is often apparent in critically injured children, as some patients may not tolerate the time spent away from the pediatric intensive care unit or may be unable to lay flat due to a concomitant traumatic brain injury.<sup>65,66</sup> Pediatric researchers have reviewed the utility of abbreviated MRI protocols to decrease the time of MRI and the need for sedation while identifying pediatric pathology.<sup>67</sup>

**Pediatric Cervical Spine Clearance Working Group Algorithm**



**Figure 2.** Pediatric Cervical Spine Clearance Working Group algorithm.<sup>75</sup>

Abbreviated MRI protocols, or limited sequence MRIs (LSMRI), achieve shorter imaging acquisition times by limiting the number of sequences obtained and accelerating the speed of imaging acquisition.

In 2024, Melhado et al.<sup>67</sup> conducted a large retrospective review at 10 level I pediatric trauma centers to identify the role of LSMRI in identifying clinically unstable cervical spine injuries among pediatric patients. They reviewed all blunt pediatric trauma patients who underwent an MRI. Of the 2,663 patients identified in the study, 1,008 injuries were identified on full-sequence MRI with 301 unstable injuries (11%). A pediatric board-certified radiologist from each institution reviewed the MRIs from their respective institutions as if they were an LSMRI. When using the anatomic plus fluid-sensitive LSMRI, only four (0.3%) of CSI injuries were missed, and none of the missed injuries were determined to be clinically unstable. While the time required to obtain an LSMIR was not formally addressed in this study, the authors anecdotally indicated that LSMIRs require 15 to 20 minutes to obtain at the study centers. The role of LSMRI has not been established in the evaluation of the pediatric cervical spine; however, this provides compelling insights on its future use as a screening examination.<sup>67</sup>

## SUMMARY

Cervical spine injury occurs in 1% of pediatric patients after blunt trauma. Small children have a higher incidence of injury at the craniocervical junction, but after the age of 9 years, injury patterns mirror adult patients. The PECARN prediction rule is the highest quality of evidence to guide imaging decisions. In general, we should limit ionizing radiation in alert pediatric trauma patients and encourage x-rays whenever possible, but CT is warranted in critically ill patients. Retroclival blood on a cervical spine or head CT is a sign of injury at the craniocervical junction and needs further investigation. It is important to develop and follow a hospital protocol. The consensus statement from the PCSCWG may be referenced for clearance decisions. Evaluation of the pediatric cervical spine is a topic of current exploration, and we anticipate further guidance in the next few years.

## AUTHORSHIP

K.W.R. contributed in the literature review. K.W.R., A.K., and R.S.E. contributed in the drafting of the manuscript. K.W.R., A.K., and R.S.E. contributed in the critical revision.

## DISCLOSURE

Conflicts of Interest: Author Disclosure forms have been supplied and are provided as Supplemental Digital Content (<http://links.lww.com/TA/E84>).

## REFERENCES

1. Viccellio P, Simon H, Pressman BD, Shah MN, Mower WR, Hoffman JR. A prospective multicenter study of cervical spine injury in children. *Pediatrics*. 2001;108(2):e20–e20.
2. Kim W, Ahn N, Ata A, Adamo MA, Entezami P, Edwards M. Pediatric cervical spine injury in the United States: defining the burden of injury, need for operative intervention, and disparities in imaging across trauma centers. *J Pediatr Surg*. 2021;56(2):293–296.
3. Leonard JC, Harding M, Cook LJ, Leonard JR, Adelgais KM, Ahmad FA, et al. PECARN prediction rule for cervical spine imaging of children presenting to the emergency department with blunt trauma: a multicentre prospective observational study. *Lancet Child Adolesc Health*. 2024;8(7):482–490.
4. Leonard JR, Jaffe DM, Kuppermann N, Olsen CS, Leonard JC. Pediatric Emergency Care Applied Research Network (PECARN) cervical spine study group. Cervical spine injury patterns in children. *Pediatrics*. 2014;133(5):e1179–e1188.
5. Mohseni S, Talving P, Branco BC, Chan LS, Lustenberger T, Inaba K, et al. Effect of age on cervical spine injury in pediatric population: a National Trauma Data Bank review. *J Pediatr Surg*. 2011;46(9):1771–1776.
6. Nadarajah V, Jauregui JJ, Perfetti D, Shasti M, Koh EY, Henn RF. What are the trends and demographics in sports-related pediatric spinal cord injuries? *Phys Sportsmed*. 2018;46(1):8–13.
7. Luckhurst CM, Wiberg HM, Brown RL, Bruch SW, Chandler NM, Danielson PD, et al. Pediatric cervical spine injury following blunt trauma in children younger than 3 years: the PEDSPINE II study. *JAMA Surg*. 2023;158(11):1126–1132.
8. Pearce MS, Salotti JA, Little MP, McHugh K, Lee C, Kim KP, et al. Radiation exposure from CT scans in childhood and subsequent risk of leukaemia and brain tumours: a retrospective cohort study. *Lancet*. 2012;380(9840):499–505.
9. Miglioretti DL, Johnson E, Williams A, Greenlee RT, Weinmann S, Solberg LJ, et al. The use of computed tomography in pediatrics and the associated radiation exposure and estimated cancer risk. *JAMA Pediatr*. 2013;167(8):700–707.
10. Mathews JD, Forsythe AV, Brady Z, Butler MW, Goergen SK, Byrnes GB, et al. Cancer risk in 680,000 people exposed to computed tomography scans in childhood or adolescence: data linkage study of 11 million Australians. *BMJ*. 2013;346:f2360.
11. Rice HE, Frush DP, Farmer D, Waldhausen JH. APSA education committee. Review of radiation risks from computed tomography: essentials for the pediatric surgeon. *J Pediatr Surg*. 2007;42(4):603–607.
12. Nolte PC, Liao S, Kuch M, Grützner PA, Münzberg M, Kreinest M. Development of a new emergency medicine spinal immobilization protocol for pediatric trauma patients and first applicability test on emergency medicine personnel. *Pediatr Emerg Care*. 2022;38(1):e75–e84.
13. Hauswald M, Ong G, Tandberg D, Omar Z. Out-of-hospital spinal immobilization: its effect on neurologic injury. *Acad Emerg Med*. 1998;5(3):214–219.
14. Horodyski M, DiPaola CP, Conrad BP, Rechline GR. Cervical collars are insufficient for immobilizing an unstable cervical spine injury. *J Emerg Med*. 2011;41(5):513–519.
15. Kolcun JPG, Broderick R. Reduction of atlanto-occipital dislocation after cervical collar removal. *World Neurosurg*. 2023;180:67–68.
16. Leonard JC, Mao J, Jaffe DM. Potential adverse effects of spinal immobilization in children. *Prehosp Emerg Care*. 2012;16(4):513–518.
17. Davies G, Deakin C, Wilson A. The effect of a rigid collar on intracranial pressure. *Injury*. 1996;27(9):647–649.
18. Liao S, Schneider NRE, Hüttlin P, Grützner PA, Weilbacher F, Matschke S, et al. Motion and dural sac compression in the upper cervical spine during the application of a cervical collar in case of unstable craniocervical junction—a study in two new cadaveric trauma models. *PLoS One*. 2018;13(4):e0195215.
19. Melhado C, Russell KW, Acker SN, Padilla BE, Lofberg K, Spurrier RG, et al. Cervical collar-associated pressure injury in pediatric trauma patients: a Western Pediatric Surgery Research Consortium study. *J Pediatr Surg*. 2024;59(2):326–330.
20. Morris CGT, McCoy E. Cervical immobilisation collars in ICU: friend or foe? *Anaesthesia*. 2003;58(11):1051–1053.
21. Chan M, Al-Buali W, Charyk Stewart T, Singh RN, Kornecki A, et al. Cervical spine injuries and collar complications in severely injured paediatric trauma patients. *Spinal Cord*. 2013;51(5):360–364.
22. Powers J, Daniels D, McGuire C, Hilbish C. The incidence of skin breakdown associated with use of cervical collars. *J Trauma Nurs*. 2006;13(4):198–200.
23. Ham W, Schoonhoven L, Schuurmans MJ, Leenen LP. Pressure ulcers from spinal immobilization in trauma patients: a systematic review. *J Trauma Acute Care Surg*. 2014;76(4):1131–1141.
24. Hoffman JR, Wolfson AB, Todd K, Mower WR. Selective cervical spine radiography in blunt trauma: methodology of the National Emergency X-radiography Utilization Study (NEXUS). *Ann Emerg Med*. 1998;32(4):461–469.
25. Hoffman JR, Mower WR, Wolfson AB, Todd KH, Zucker MI. Validity of a set of clinical criteria to rule out injury to the cervical spine in patients with blunt trauma. National Emergency X-radiography Utilization Study group. *N Engl J Med*. 2000;343(2):94–99.
26. Garton HJL, Hammer MR. Detection of pediatric cervical spine injury. *Neurosurgery*. 2008;62(3):700–708 discussion 700–8.



27. Burns EC, Yanchar NL. Using cervical spine clearance guidelines in a pediatric population: a survey of physician practices and opinions. *CJEM*. 2011; 13(1):1–6.
28. Slaar A, Fockens MM, Wang J, Maas M, Wilson DJ, Goslings JC, et al. Triage tools for detecting cervical spine injury in pediatric trauma patients. *Cochrane Database Syst Rev* 2017;12(12):.
29. Pannu GS, Shah MP, Herman MJ. Cervical spine clearance in pediatric trauma centers: the need for standardization and an evidence-based protocol. *J Pediatr Orthop*. 2017;37(3):e145–e149.
30. Eldredge RS, Yorgitis B, Padilla BE, Western Pediatric Cervical Spine Research Group, Russell KW. Practices in clearance of the pediatric cervical spine following blunt trauma: a Western Pediatric Cervical Spine Study analysis. In: Pediatric Trauma Society 10th Annual Meeting, November 6, 2024.
31. Stiell IG, Wells GA, Vandemheen KL, Clement CM, Lesiuk H, De Maio VJ, et al. The Canadian C-spine rule for radiography in alert and stable trauma patients. *JAMA*. 2001;286(15):1841–1848.
32. Leonard JC, Kuppermann N, Olsen C, Babcock-Cimpello L, Brown K, Mahajan P, et al. Factors associated with cervical spine injury in children after blunt trauma. *Ann Emerg Med*. 2011;58(2):145–155.
33. Leonard JC, Browne LR, Ahmad FA, Schwartz H, Wallendorf M, Leonard JR, et al. Cervical spine injury risk factors in children with blunt trauma. *Pediatrics*. 2019;144(1):e20183221.
34. Ahmad FA, Schwartz H, Browne LR, Lassa-Claxton S, Wallendorf M, Brooke Lerner E, et al. Methods for collecting paired observations from emergency medical services and emergency department providers for pediatric cervical spine injury risk factors. *Acad Emerg Med*. 2017;24(4):432–441.
35. Sickles EA, Wolverton DE, Dee KE. Performance parameters for screening and diagnostic mammography: specialist and general radiologists. *Radiology*. 2002;224(3):861–869.
36. Alessandrino F, Bono CM, Potter CA, Harris MB, Sodickson AD, Khurana B. Spectrum of diagnostic errors in cervical spine trauma imaging and their clinical significance. *Emerg Radiol*. 2019;26(4):409–416.
37. Hassan N, Butler C, DeCoul J, Crumb T, Flohr S, Reischman D, et al. Pediatric cervical spine injuries on CT: difference in accuracy of interpretations by pediatric versus non-pediatric radiologists. *Emerg Radiol*. 2020;27(2): 185–190.
38. Ross EE, Ourshalimian S, Spurrier RG, Chaudhari PP. Trends and variation in cervical spine imaging utilization across children's hospitals for pediatric trauma. *J Trauma Acute Care Surg*. January 2024, 97:400–406.
39. Massoumi R, Wertz J, Duong T, Tseng C-H, Jen HC-H. Variation in pediatric cervical spine imaging across trauma centers—a cause for concern? *J Trauma Acute Care Surg*. 2021;91(4):641–648.
40. ten Brinke JG, Slinger G, Slaar A, Saltzherr TP, Hogervorst M, Goslings JC. Increased and unjustified CT usage in paediatric C-spine clearance in a level 2 trauma centre. *Eur J Trauma Emerg Surg*. 2021;47(3):781–789.
41. Lee RP, Zhou NJ, Hidalgo J, Tittsworth WL, Uribe-Cardenas R, Chowdhury R, et al. Weighing the risk profile of cervical spine MRI in evaluating pediatric cervical spine injuries. *Pediatr Neurosurg*. 2022;57(5):314–322.
42. Brockmeyer DL, Ragel BT, Kestle JRW. The pediatric cervical spine instability study. A pilot study assessing the prognostic value of four imaging modalities in clearing the cervical spine for children with severe traumatic injuries. *Childs Nerv Syst*. 2012;28(5):699–705.
43. Hale DF, Fitzpatrick CM, Doski JJ, Stewart RM, Mueller DL. Absence of clinical findings reliably excludes unstable cervical spine injuries in children 5 years or younger. *J Trauma Acute Care Surg*. 2015;78(5):943–948.
44. Silva CT, Doria AS, Traubici J, Moineddin R, Davila J, Shroff M. Do additional views improve the diagnostic performance of cervical spine radiography in pediatric trauma? *AJR Am J Roentgenol*. 2010;194(2):500–508.
45. Lindholm EB, Malik A, Parikh D, Mamdouhi T, Alper L, Nanassy A, et al. Single-lateral cervical radiograph in pediatric trauma is equivalent to multiple views. *J Trauma Acute Care Surg*. 2019;87(4):813–817.
46. Flynn JM, Closkey RF, Mahboubi S, Dormans JP. Role of magnetic resonance imaging in the assessment of pediatric cervical spine injuries. *J Pediatr Orthop*. 2002;22(5):573–577.
47. Jeong D, Beno S, Drake JM, Freire G. Clinical characteristics of upper cervical spine injuries in children: a retrospective case series. *J Neurosurg Pediatr*. 2024;33(5):452–460.
48. Yorkgitis BK, McCauley DM. Cervical spine clearance in adult trauma patients. *JAAPA*. 2019;32(2):12–16.
49. Fisher A, Young WF. Is the lateral cervical spine x-ray obsolete during the initial evaluation of patients with acute trauma? *Surg Neurol*. 2008;70(1): 53–57 discussion 58.
50. Brohi K, Healy M, Fotheringham T, Chan O, Aylwin C, Whitley S, et al. Helical computed tomographic scanning for the evaluation of the cervical spine in the unconscious, intubated trauma patient. *J Trauma*. 2005;58(5): 897–901.
51. Blackmore CC, Mann FA, Wilson AJ. Helical CT in the primary trauma evaluation of the cervical spine: an evidence-based approach. *Skeletal Radiol*. 2000;29(11):632–639.
52. Barnes BC, Kamat PP, McCracken CM, Santore MT, Mallory MD, Simon HK, et al. Radiologic imaging in trauma patients with cervical spine immobilization at a pediatric trauma center. *J Emerg Med*. 2019;57(4):429–436.
53. Brenner DJ, Elliston CD, Hall EJ, Berdon WE. Estimated risks of radiation-induced fatal cancer from pediatric CT. *Am J Roentgenol*. 2001;176(2): 289–296.
54. Smith-Bindman R, Lipson J, Marcus R, Kim K-P, Mahesh M, Gould R, et al. Radiation dose associated with common computed tomography examinations and the associated lifetime attributable risk of cancer. *Arch Intern Med*. 2009;169(22):2078–2086.
55. Fenton SJ, Hansen KW, Meyers RL, Vargo DJ, White KS, Firth SD, et al. CT scan and the pediatric trauma patient—are we overdoing it? *J Pediatr Surg*. 2004;39(12):1877–1881.
56. Jimenez RR, Deguzman MA, Shiran S, Karrellas A, Lorenzo RL. CT versus plain radiographs for evaluation of c-spine injury in young children: do benefits outweigh risks? *Pediatr Radiol*. 2008;38(6):635–644.
57. Russell KW, Iantorno SE, Iyer RR, Brockmeyer DL, Smith KM, Polukoff NE, et al. Pediatric cervical spine clearance: a 10-year evaluation of multidetector computed tomography at a level 1 pediatric trauma center. *J Trauma Acute Care Surg*. 2023;95(3):354–360.
58. Derderian SC, Greenan K, Mirsky DM, Stence NV, Graber S, Hankinson TC, et al. The utility of magnetic resonance imaging in pediatric trauma patients suspected of having cervical spine injuries. *J Trauma Acute Care Surg*. 2019;87(6):1328–1335.
59. Gargas J, Yaszay B, Kruk P, Bastrom T, Shellington D, Khanna S. An analysis of cervical spine magnetic resonance imaging findings after normal computed tomographic imaging findings in pediatric trauma patients. *J Trauma Acute Care Surg*. 2013;74(4):1102–1107.
60. Qualls D, Leonard JR, Keller M, Pineda J, Leonard JC. Utility of magnetic resonance imaging in diagnosing cervical spine injury in children with severe traumatic brain injury. *J Trauma Acute Care Surg*. 2015;78(6): 1122–1128.
61. Azizi N, Huynh JL, Raslan O, Bobinski M, Haccin-Bey L, Ozturk A. Pediatric cervical spine clearance after blunt trauma and negative CT: what is the role of MRI? *J Neuroradiol*. 2024;51(5):101206.
62. Stephenson KJ, Bullard KL, Wyrick DL, Ramakrishnaiah RH, Albert GW, Maxson RT. Can you see with CT? Is cervical spine computed tomographic imaging sufficient in pediatric trauma? *Am J Surg*. 2023;226(1):122–127.
63. Melhado C, Russell K, Polukoff N, Acker S, Prendergast C, Jamshidi, et al. The negative predictive value of a normal cervical spine CT compared to MRI after blunt trauma in children. In: AAP National Conference & Exhibition Section on Surgery, Washington, DC; 2023.
64. Webman RB, Carter EA, Mittal S, Wang J, Sathya C, Nathens AB, et al. Association between trauma center type and mortality among injured adolescent patients. *JAMA Pediatr*. 2016;170(8):780–786.
65. Patel MB, Humble SS, Cullinane DC, Day MA, Jawa RS, Devin CJ, et al. Cervical spine collar clearance in the obtunded adult blunt trauma patient: a systematic review and practice management guideline from the Eastern Association for the Surgery of Trauma. *J Trauma Acute Care Surg*. 2015;78(2): 430–441.
66. Frank JB, Lim CK, Flynn JM, Dormans JP. The efficacy of magnetic resonance imaging in pediatric cervical spine clearance. *Spine (Phila Pa 1976)*. 2002;27(11):1176–1179.
67. Melhado C, Durand R, Russell KW, Polukoff NE, Rampton J, Iyer RR, et al. The sensitivity of limited-sequence MRI in identifying pediatric cervical spine injury: a Western Pediatric Surgery Research Consortium multicenter retrospective cohort study. *J Trauma Acute Care Surg*. March 2024;97: 407–413.
68. Jaimes C, Murcia DJ, Miguel K, DeFuria C, Sagar P, Gee MS. Identification of quality improvement areas in pediatric MRI from analysis of patient safety reports. *Pediatr Radiol*. 2018;48(1):66–73.
69. Snyder EJ, Zhang W, Jasmin KC, Thankachan S, Donnelly LF. Gauging potential risk for patients in pediatric radiology by review of over 2,000 incident reports. *Pediatr Radiol*. 2018;48(13):1867–1874.



70. Letica-Kriegel AS, Kaplan A, Orlas C, Masiakos PT. Variability of pediatric cervical spine clearance protocols: a systematic review. *Ann Surg.* 2022;276(6):989–994.
71. Herman MJ, Brown KO, Sponseller PD, Phillips JH, Petrucelli PM, Parikh DJ, et al. Pediatric cervical spine clearance: a consensus statement and algorithm from the pediatric cervical spine clearance working group. *J Bone Joint Surg Am.* 2019;101(1):e1.
72. Arbutnot M, Mooney DP. The sensitivity and negative predictive value of a pediatric cervical spine clearance algorithm that minimizes computerized tomography. *J Pediatr Surg.* 2017;52(1):130–135.
73. Pennell C, Gupta J, March M, Arthur LG, Lindholm E, Herman M, et al. A standardized protocol for cervical spine evaluation in children reduces imaging utilization: a pilot study of the pediatric cervical spine clearance working group protocol. *J Pediatr Orthop.* 2020;40(8):e780–e784.
74. Overmann KM, Robinson BRH, Eckman MH. Cervical spine evaluation in pediatric trauma: a cost-effectiveness analysis. *Am J Emerg Med.* 2020;38(11):2347–2355.
75. Dorney K, Kimia A, Hannon M, Hennelly K, Meehan WP, Proctor M, et al. Outcomes of pediatric patients with persistent midline cervical spine tenderness and negative imaging result after trauma. *J Trauma Acute Care Surg.* 2015;79(5):822–827.
76. Hewes HA, Ravindra VM, Ryan S, Russell KW, Soisson S, Brockmeyer DL. The fate of the cervical collar: an observational pilot study investigating follow-up care after emergency department discharge in children with mild traumatic neck injuries. *Pediatr Emerg Care.* 2023;39(4):274–278.
77. Kavuri V, Pannu G, Moront M, Pizzutillo P, Herman M. “Next day” examination reduces radiation exposure in cervical spine clearance at a level 1 pediatric trauma center: preliminary findings. *J Pediatr Orthop.* 2019;39(5):e339–e342.
78. Samples DC, Staulcup S, Hovis G, Gustin P, Meier M, Mirsky D, et al. Refining the role of cervical spine immobilization and stabilization in pediatric non-accidental trauma, a retrospective series of 1008 patients. *Childs Nerv Syst.* 2022;38(12):2357–2364.
79. Oh A, Sawvel M, Heaner D, Bhatia A, Reisner A, Tubbs RS, et al. Changes in use of cervical spine magnetic resonance imaging for pediatric patients with nonaccidental trauma. *J Neurosurg Pediatr.* 2017;20(3):271–277.
80. Inaba K, Byerly S, Bush LD, Martin MJ, Martin DT, Peck KA, et al. Cervical spinal clearance: a prospective Western Trauma Association multi-institutional trial. *J Trauma Acute Care Surg.* 2016;81(6):1122–1130.