

Managing Emergency Endotracheal Intubation Utilizing a Bougie

Ryan N. Barnicle, MD, MSEd*; Alexander Bracey, MD; Scott D. Weingart, MD

*Corresponding Author. E-mail: ryanbarniclemd@gmail.com.

0196-0644/\$-see front matter

Copyright © 2024 by the American College of Emergency Physicians.

<https://doi.org/10.1016/j.annemergmed.2024.04.021>

[Ann Emerg Med. 2024;■:1-.]

INTRODUCTION

The endotracheal tube (ETT) introducer, or “bougie,” is used to cannulate the trachea prior to ETT delivery using the Seldinger technique. In most emergency departments, the bougie is not incorporated into a primary intubation strategy and has historically been relegated to an adjunctive role or used as a rescue device for difficult airways. This may be due to inexperience with the optimized technique, difficulty troubleshooting bougie-related challenges, concern of procedure prolongation, or skepticism of its efficacy as a primary intubation device. However, recent literature has demonstrated the clear utility of a bougie-first strategy when combined with standard geometry laryngoscopy, while also underscoring the need for repetitive use in the pursuit of procedural mastery.¹⁻⁶ In the largest trial in which operators did not have increased familiarity with the bougie, first-pass success with a bougie (80.4%) was not significantly different than with a stylet (83%).⁴ However, first-pass success for operators who predominantly utilize a bougie-first approach has been shown to be 96% when patients have difficult airway characteristics and 99% in those without difficult airways.²

A technical overview for the effective use of bougies during endotracheal intubation is presented here and serves as a foundational guide for trainees, educators, and physicians aiming to optimize bougie-related skill and strategy. Our intent is to provide a level of detail not explained in the literature previously, while recognizing that operators may still modify this foundational procedure and incorporate the bougie into various other advanced airway techniques.⁷⁻⁹ The following recommendations, when not specifically referenced, are based on our informed practice because there is a dearth of evidence regarding the specific microskills of bougie-assisted intubation.

FEATURES

Most bougies used for adult intubations are 15F (5 mm) in diameter, which accommodate ETTs sized 6.0 mm or more and range from 50 to 70 cm in length. The distal end features a stiff 30°-angulated coude tip that facilitates cannulation of the trachea. Most single-use versions are made of a pliable plastic that can be temporarily manipulated to a desired conformation (Figure 1A). We consider the following features important:

Single Use: Bougies should be single use and disposable given that relying on the logistics of sterilizing reusable bougies may result in critical device shortages.

Material: The exact composition of bougies varies.

Currently, no evidence exists supporting a specific material or brand. The material should hold a desired conformation for the duration of the procedure.

Length: A 70-cm bougie facilitates ETT hand-off and delivery without extensive manipulation of the portion in the trachea, minimizing the risk of decannulation. Operators may find that shorter bougies do not sufficiently protrude out of the ETT, complicating removal.

Depth Marker: Some bougies have a circumferential black line at 23 cm (Figure 1) that, when advanced to the level of the teeth, indicates the coude tip is past the adult glottis.

Flexible Tip: Bougies with silicone atraumatic articulating tips allow for “steering” through the glottis (Figure 2), but the advantages remain theoretical. Notably, the control sliders require an ETT sized 7.0 mm or more.

PREPARATION

Storage: Bougies should be stored straight in sterile packaging because folding or curving during storage can induce a disadvantageous conformation that might

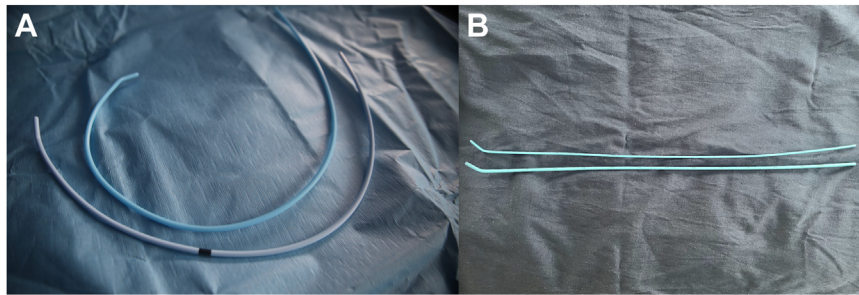


Figure 1. A, Two different brands of disposable single-use bougies are shown in curved conformations. The black line on the lower bougie marks the appropriate insertion depth (23 cm) when aligned with the teeth. B, These bougies in straight conformations highlight the different diameters between typical adult and pediatric bougies.

inhibit the procedure. We recognize straight storage is not always possible in the out-of-hospital setting.

Curving: Operators should consider beginning the procedure with a modest curve in the distal third of the bougie to facilitate tracheal cannulation, even when the glottis is easily visualized. Our practice is to place the bougie in a “snail tail” spiral configuration during preparation (Figure 3). To ensure that the curve lasts long enough, the “snail tail” should be released immediately prior to insertion.

Preloading: We do not endorse “preloading” the ETT. Various “grips” have been described for solo-operators to reduce time to ETT delivery without supporting evidence. Importantly, preloaded configurations compromise the main advantages of the bougie and may inhibit troubleshooting maneuvers.

ADVANTAGES AND DISADVANTAGES

Bougies have several advantages versus stylets. There is often a transient obstruction of the glottic view as the ETT-over-stylet is delivered, which can lead to

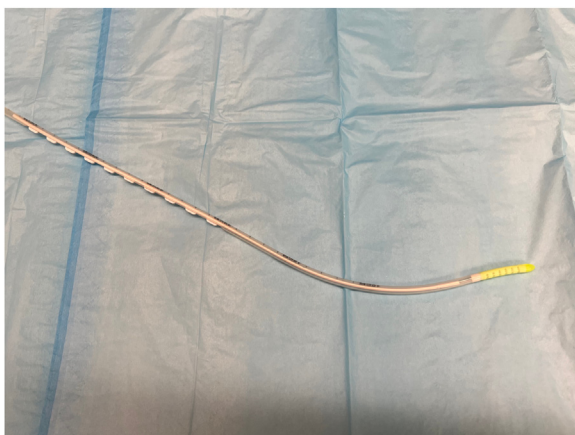

Figure 2. A bougie featuring a flexible silicone tip and permanent curve is shown here. The white posterior tabs slide up and down to steer the flexible tip.

esophageal placement or other complications. Because the bougie diameter is narrower than an ETT-over-stylet, particularly at the level of the cuff, there is a comparatively improved field of view as the bougie approaches the glottis. This allows for continuous visualization until tracheal cannulation (Figure 4). The narrower profile is also beneficial when encountering challenging scenarios (eg, airway edema, epiglottitis (Video E1, available at <http://www.annemergmed.com>), an omega-shaped epiglottis (Video E2, available at <http://www.annemergmed.com>), soiling (Video E3, available at <http://www.annemergmed.com>), or airway trauma). If the coudé tip is seen cannulating the trachea in these scenarios, the ETT can be delivered confidently even if visualization is subsequently compromised.

The coudé tip is also an advantageous feature because it can be guided to where the glottic opening is presumed to be with challenging modified Cormack–Lehane views (Video E4, available at <http://www.annemergmed.com>), a well-described strategy.¹⁰ However, reserving the bougie for only these suboptimal views risks scenarios where operators will not have device mastery when it is needed most.

Tactile feedback is another reported advantage, but there are important caveats. Operators may be reassured by feeling “clicks” as the coudé tip is advanced against anterior tracheal rings but this is an imperfect clinical sign and is only noted about 90% of the time.^{2,11-13} The absence of “clicks” is not indicative of esophageal placement. Moreover, “clicks” will not be felt if the coudé tip is rotated 90° to intentionally avoid tracheal rings.

Operators may experience the “hold up” sign when resistance to further advancement occurs at the carina, mainstem bronchi, or smaller airways. This reliably indicates tracheal cannulation. A lack of resistance beyond 45 cm conversely indicates esophageal placement.¹³ However, operators do not need to intentionally seek “hold up” for confirmation if tracheal cannulation is clearly visualized during laryngoscopy.



Figure 3. Placing the bougie in a “snail tail” spiral prior to the procedure is one option for inducing an optimal curve in the lower one-third of the bougie that should persist long enough after release to cannulate the trachea.

Procedure prolongation is a potential disadvantage, but has not been associated with harm. Driver et al^{1,2,4} have noted procedure prolongation ranging from 2 seconds to 14 seconds, but without clinically significant complications associated with the bougie. Other studies have shown equivalent time to intubation.^{3,14}

Finally, iatrogenic trauma to the airway with bougies is possible, but this has been limited to case reports.¹⁵⁻¹⁷ When data are systematically recorded for bougie versus stylet, injuries are extremely rare and are similar between the 2 ETT delivery strategies. The 2 largest randomized trials, which enrolled a total of 1,859 patients, reported that complications were rare with both techniques.^{2,4} The bougie groups had similar or lower rates of pneumothorax and iatrogenic bleeding. There were no injuries to the

glottis or thoracic structures observed in either trial. Still, operators should never apply undue force with the bougie if resistance is encountered.

PATIENT SELECTION

A bougie-first strategy is appropriate for all airways being managed with standard geometry laryngoscopy and standard ETTs, but specific subgroups of patients are known to benefit from a bougie-first approach, including those with suboptimal laryngoscopy views, soiled airways, obesity, and needing cervical immobilization.² Notably, if hyperangulated video laryngoscopy is used, the current evidence does not support combined bougie use, and this has been previously described as “incompatible” by experts.^{18,19} In hyperangulated video laryngoscopy views, the coude tip is often seen malpositioned posterior to the arytenoids after insertion because the angle necessary to access the trachea requires an overly dramatic curve in the bougie that is difficult to maintain for the duration of the procedure. Additionally, if a scenario demands an ETT size of less than 6.0 mm, a standard adult bougie is too large. Operators should be aware that various smaller pediatric and neonatal bougies are available.²⁰

FOUNDATIONAL PROCEDURE

Below is a discussion of the essential bougie-related technical skills and strategies to employ during an intubation. Supplement E1 (available at <http://www.annemergmed.com>) serves as foundational guide with a detailed step-by-step template for incorporating a bougie into an intubation attempt, highlighting essential closed-

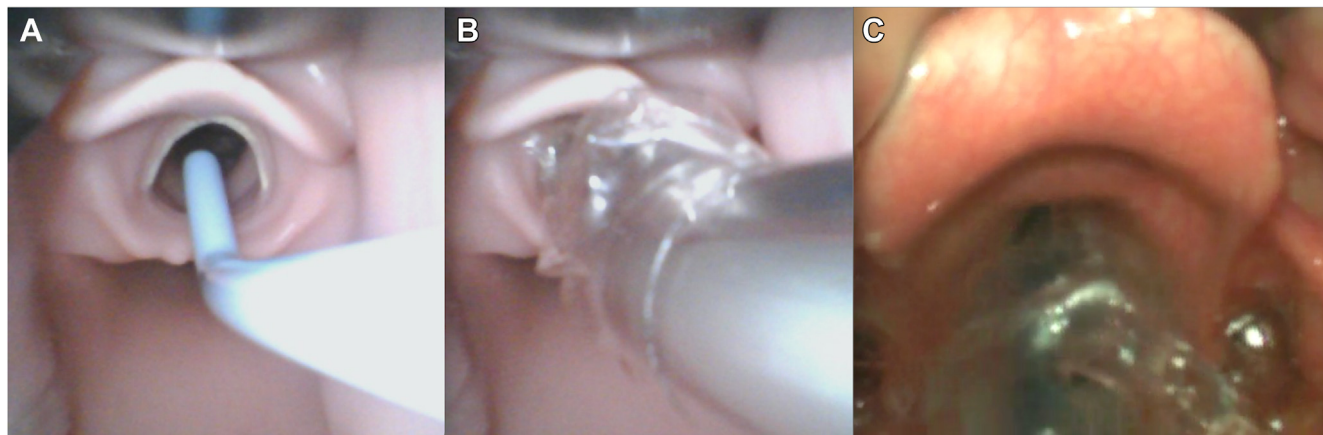


Figure 4. A, A bougie allows for a continuous, unobstructed view of tracheal cannulation. B, These standard geometry video laryngoscopy images of a simulation airway highlight how a cuffed ETT with a stylet blocks the view of the vocal cords prior to tracheal cannulation, risking misplacement or compromised troubleshooting. C, The ETT cuff is seen blocking the view of the vocal cords of an actual patient. Image courtesy of Hennepin County Medical Center.

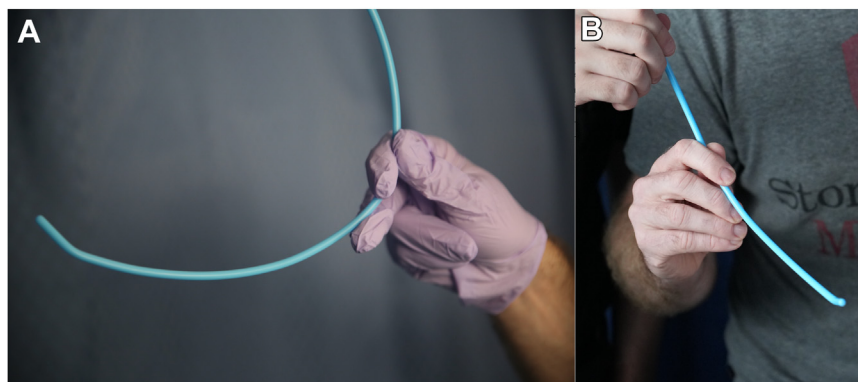


Figure 5. A, The bougie is grasped with a “tripod” grip in the right hand. The middle finger is behind/under the bougie while it is grasped firmly between the index finger and thumb. Pressure applied with the posterior middle finger allows for microadjustments during insertion. B, Alternate angle showing hand-off with assistant.

loop communication, choreography, and microskills. The guide reflects our typical practice, but operators can modify it to suit individual preferences and scenarios.

Assistance

Using an experienced assistant is optimal (Video E5, available at <http://www.annemergmed.com>). Equipment can be prepared while the operator focuses on laryngoscopy. Closed-loop communication and a choreographed hand-off allows the operator to maintain a continuous view of the glottis without needing to reach blindly for the bougie or ETT. Solo-operators can perform just as effectively, but there are discrete steps that occur in sequence instead of in tandem (Video E6, available at <http://www.annemergmed.com>).

Preparation

Our practice is to curve the bougie using the “snail tail” technique. Curving may reduce the need to remove the

bougie and reshape it later if the trachea cannot be cannulated on the first attempt with a straight bougie.

Grip

Utilizing a right-handed “tripod” grip proximal to the midpoint of the bougie (Figure 5) allows the middle finger that is behind/under the bougie to apply leverage, which may facilitate microadjustments of the coude tip. Operators may prefer to grip with 4 fingers.

Insertion

Operators should look into the mouth as the bougie is inserted and not the screen if video laryngoscopy is utilized. If curved, the bougie can be inserted at the midline alongside the curve of the laryngoscope (Figure 6) with a rotational motion that brings the coude tip toward the glottis. The coude tip is angled anteriorly as it passes through the cords. If kept straight,

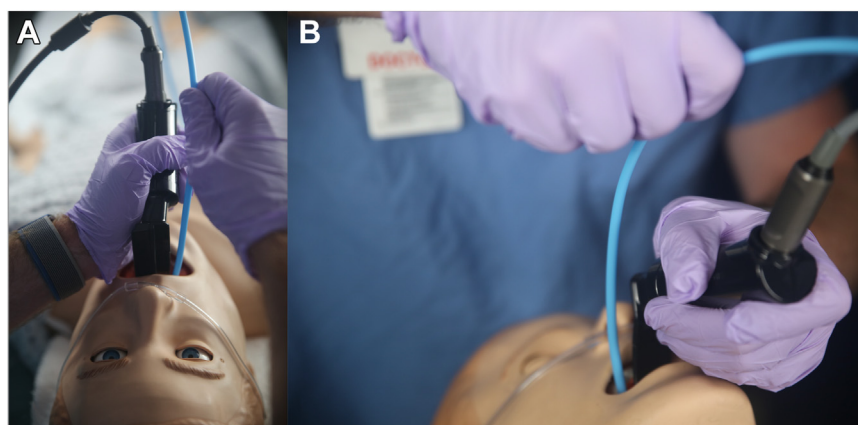


Figure 6. A, The bougie is inserted parallel to the laryngoscope through a rotational movement that follows the curve of the blade, angling the coude tip straight toward the glottis. B, Alternate angle is shown.

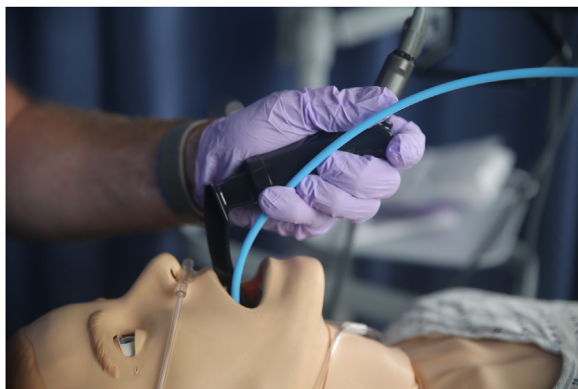

Figure 7. The operator can stabilize the bougie at the proper depth by gripping the bougie against the handle of the laryngoscope with the left finger(s).

the bougie should be inserted initially at the corner of the mouth.

Bougie Rotation

Intentionally rotating the bougie 90° after passing through the cords avoids hang-up on the anterior tracheal rings.

Advancement

Advancement can cease once the black line (23 cm) is even with the teeth or if “hold up” occurs.

Stabilizing

Once the bougie is stabilized at the appropriate depth, continuous forward force is unnecessary. A solo-operator

should stabilize the bougie against the laryngoscope handle with the finger(s) of the left hand (Figure 7).

ETT Hand-Off

The assistant introduces the ETT over the proximal end of the bougie, but should only advance it to the operator’s fingers before relinquishing full control. Further manipulation from the assistant is unnecessary. The operator should not “feed” the bougie up through the ETT because this increases the risk of tracheal decannulation.

ETT Delivery

The ETT should be advanced over the bougie past the corner of the mouth to the glottis. As the bevel tip approaches the glottis, it should be intentionally rotated 90° counterclockwise and advanced into the trachea to the proper depth. Counterclockwise rotation directs the ETT bevel posteriorly, which avoids hang-up on the arytenoids (Figure 8).

Equipment Removal

If present, an assistant should inflate the cuff and remove the bougie while the ETT is stabilized by the operator’s right hand. The laryngoscope can then be removed. If alone, the operator stabilizes the ETT and removes the laryngoscope first. Then, the operator inflates the ETT cuff and removes the bougie.

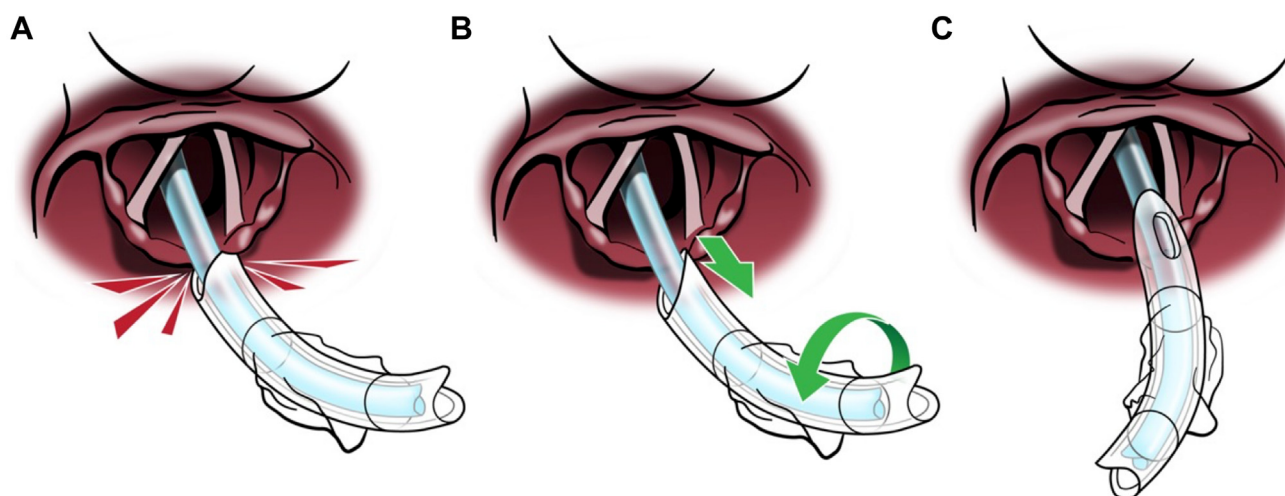


Figure 8. A, The bevel tip of the ETT is hung up on the arytenoids. B, The ETT is withdrawn slightly and then rotated 90° counterclockwise so that the bevel tip is at 12 o’clock. C, With the bevel facing posteriorly, the ETT passes smoothly through the glottis. Image courtesy of Hennepin County Medical Center.

TROUBLESHOOTING

Challenges with advancing the bougie or the ETT exist, but operators should employ the following maneuvers if experiencing difficulty.²¹ Failing to respond appropriately to these challenges has been described as distinct performance errors noted during standard geometry video laryngoscopy.²²

Bougie Hang-Up

If the coudé tip becomes stuck on the anterior tracheal rings despite optimal valleculla manipulation, there are remedies. Continuing to hold the bougie's shaft, operators should discontinue forward pressure and apply a 90° rotation to release the coudé tip and allow advancement (Video E7, Video E8, and Video E9, available at <http://www.annemergmed.com>). If rotation fails, the operator can move to the proximal end of the bougie and employ a "twirl" technique that will transfer rotational forces to the coudé tip and release it from the tracheal rings (Video E10, available at <http://www.annemergmed.com>).²³

ETT Hang-Up

If the ETT cannot be advanced through the glottis over the bougie, it is often stuck on the arytenoids. Operators should halt forward pressure, pull back slightly on the ETT, and rotate the ETT bevel tip 90° counterclockwise to the 12 o'clock position in the tracheal opening before advancing into the trachea (Figure 8; Video E11 and Video E12, available at <http://www.annemergmed.com>).

Loss of View Due to Premature Removal of Laryngoscope

Operators may hastily remove the laryngoscope before visualizing the ETT going through the cords over the bougie. This causes the tongue and oropharyngeal structures to collapse posteriorly and can potentially inhibit ETT delivery. If this occurs, operators should re-establish the view first instead of withdrawing the ETT or bougie (Video E13, available at <http://www.annemergmed.com>).

Mark F. Brady, MD, MPH, Department of Emergency Medicine, The Warren Alpert Medical School of Brown University, Providence, RI, USA filmed, edited, and revised all original procedure videos and photographs. Keegan S. McNally, MD, MMSc, Department of Emergency Medicine, The Warren Alpert Medical School of Brown University, Providence, RI, USA acted as procedure assistant for the original videos and helped edit the detailed foundational procedure guides.

Supervising editor: Steven M. Green, MD. Specific detailed information about possible conflict of interest for individual editors is available at <https://www.annemergmed.com/editors>.

Author affiliations: From the Department of Emergency Medicine (Barnicle), the Warren Alpert Medical School of Brown University, Providence, RI; Department of Emergency Medicine (Bracey), Albany Medical Center, Albany, NY; and the Department of Emergency Medicine (Weingart), Nassau County Medical Center, East Meadow, NY.

All authors attest to meeting the four [ICMJE.org](http://www.icmje.org) authorship criteria: (1) Substantial contributions to the conception or design of the work; or the acquisition, analysis, or interpretation of data for the work; AND (2) Drafting the work or revising it critically for important intellectual content; AND (3) Final approval of the version to be published; AND (4) Agreement to be accountable for all aspects of the work in ensuring that questions related to the accuracy or integrity of any part of the work are appropriately investigated and resolved.

Funding and support: By *Annals'* policy, all authors are required to disclose any and all commercial, financial, and other relationships in any way related to the subject of this article as per ICMJE conflict of interest guidelines (see www.icmje.org). The authors have stated that no such relationships exist.

REFERENCES

1. Driver B, Dodd K, Klein LR, et al. The bougie and first-pass success in the emergency department. *Ann Emerg Med.* 2017;70:473-478 e1.
2. Driver BE, Prekker ME, Klein LR, et al. Effect of use of a bougie vs endotracheal tube and stylet on first-attempt intubation success among patients with difficult airways undergoing emergency intubation: a randomized clinical trial. *JAMA.* 2018;319:2179-2189.
3. Sheu YJ, Yu SW, Huang TW, et al. Comparison of the efficacy of a bougie and stylet in patients with endotracheal intubation: A meta-analysis of randomized controlled trials. *J Trauma Acute Care Surg.* 2019;86:902-908.
4. Driver BE, Semler MW, Self WH, et al. Effect of use of a bougie vs endotracheal tube with stylet on successful intubation on the first attempt among critically ill patients undergoing tracheal intubation: a randomized clinical trial. *JAMA.* 2021;326:2488-2497.
5. von Hellmann R, Fuhr N, Ward AMI, et al. Effect of bougie use on first-attempt success in tracheal intubations: a systematic review and meta-analysis. *Ann Emerg Med.* 2024;83:132-144.
6. Latimer AJ, Harrington B, Counts CR, et al. Routine use of a bougie improves first-attempt intubation success in the out-of-hospital setting. *Ann Emerg Med.* 2021;77:296-304.
7. Dharamsi A, Gray S, Hicks C, et al. Bougie-assisted cricothyroidotomy: Delphi-derived essential steps for the novice learner. *CJEM.* 2019;21:283-290.
8. Gottlieb M, Sharma V, Field J, et al. Utilization of a gum elastic bougie to facilitate single lung intubation. *Am J Emerg Med.* 2016;34:2408-2410.
9. Cochran-Caggiano N, Holliday J, Howard C. A novel intubation technique: bougie introduction via ducanto suction catheter. *J Emerg Med.* 2024;66:221-224.
10. Moscati R, Jehle D, Christiansen G, et al. Endotracheal tube introducer for failed intubations: a variant of the gum elastic bougie. *Ann Emerg Med.* Jul 2000;36:52-56.

11. Bair AE, Laurin EG, Schmitt BJ. An assessment of a tracheal tube introducer as an endotracheal tube placement confirmation device. *Am J Emerg Med.* Oct 2005;23:754-758.
12. Shah KH, Kwong BM, Hazan A, et al. Success of the gum elastic bougie as a rescue airway in the emergency department. *J Emerg Med.* Jan 2011;40:1-6.
13. Kidd JF, Dyson A, Latto IP. Successful difficult intubation. Use of the gum elastic bougie. *Anaesthesia.* 1988;43:437-438.
14. Heegaard WG, Black C, Pasquerella C, et al. Use of the endotracheal tube introducer as an adjunct for oral tracheal intubation in the prehospital setting. *Air Med J.* 2003;22:28-31.
15. Smith BL. Haemopneumothorax following bougie-assisted tracheal intubation. *Anaesthesia.* 1994;49:91.
16. Arndt GA, Cambray AJ, Tomasson J. Intubation bougie dissection of tracheal mucosa and intratracheal airway obstruction. *Anesth Analg.* 2008;107:603-604.
17. Kadry M, Popat M. Pharyngeal wall perforation—an unusual complication of blind intubation with a gum elastic bougie. *Anaesthesia.* 1999;54:404-405.
18. Tosh P, Rajan S, Kumar L. Ease of intubation with C-MAC videolaryngoscope: use of 60 degrees angled styletted endotracheal tube versus intubation over bougie. *Anesth Essays Res.* 2018;12:194-198.
19. Weingart SD, Driver B. Meta-analysis on bougie use for emergency airways. *J Trauma Acute Care Surg.* 2019;87:741.
20. Prekker ME, Bjorklund AR, Myers C, et al. The pediatric bougie for the first tracheal intubation attempt in critically ill Children. *Ann Emerg Med.* 2023;81:667-676.
21. Shah KH, Kwong B, Hazan A, et al. Difficulties with gum elastic bougie intubation in an academic emergency department. *J Emerg Med.* Oct 2011;41:429-434.
22. Weingart SD, Barnicle RN, Janke A, et al. A taxonomy of key performance errors for emergency intubation. *Am J Emerg Med.* 2023;73:137-144.
23. Dasgupta N. EMCrit guest post – drawing circles for bougie hangup. EMCrit Blog. Updated September 6, 2019. Accessed April 18, 2022. <https://emcrit.org/emcrit/drawing-circles/>