


Ultrasonography in thoracic and abdominal stab wound injury: results from the FETTHA study

Donia Bouzid,^{1,2,3,4} Alexy Tran-Dinh,^{1,5,6} Brice Lortat-Jacob,⁵ Enora Atchade,⁵ Sylvain Jean-Baptiste,⁵ Parvine Tashk,⁵ Aurelie Snauwaert,⁵ Nathalie Zappella,⁵ Pascal Augustin,⁵ Quentin Pellenc,⁷ Yves Castier,^{1,6,7} Lara Ribeiro,⁸ Augustin Gaudemer,⁹ Antoine Khalil,^{1,9,10} Philippe Montravers,^{1,5,10} Sebastien Tanaka ,^{5,11} on behalf of the Bichat stab wounds injury study group

Handling editor Jason E Smith

► Additional supplemental material is published online only. To view, please visit the journal online (<http://dx.doi.org/10.1136/emered-2023-213078>).

For numbered affiliations see end of article.

Correspondence to

Dr Sebastien Tanaka, APHP, Paris, Ile-de-France, France; sebastien.tanaka@aphp.fr

Received 7 January 2023
Accepted 17 August 2023

ABSTRACT

Background While the role of Extended Focused Assessment with Sonography in Trauma (eFAST) is well defined in the management of severe blunt trauma, its performance in injuries caused by stab wounds has been poorly assessed.

Methods Prospective single centre study which included all patients with stab wounds to the thorax or abdomen between December 2016 and December 2018. All patients underwent initial investigation with both eFAST and CT scan, except in cases of haemodynamic or respiratory instability, and in cases with a positive diagnosis by eFAST in which case surgery without CT scan was performed.

Results Of the 200 consecutive patients included, 14 unstable patients underwent surgery immediately after eFAST. In these 14 patients, 9 had cardiac tamponade identified by eFAST and all were confirmed by surgery. In the remaining 186 patients, the median time between eFAST and CT scan was 30 min (IQR 20–49 min). Test characteristics (including 95% CI) for eFAST compared with reference standard of CT scan for detecting pneumothorax were as follows: sensitivity 77% (54%–92%), specificity 93% (90%–97%), positive predictive value (PPV) 60% (49%–83%), negative predictive value (NPV) 97% (93%–99%). Test characteristics (including 95% CI) for eFAST compared with CT scan for detecting haemothorax were as follows: sensitivity 97% (74%–99%), specificity 96% (92%–98%), PPV 83% (63%–93%) and NPV 99% (96%–100%). Finally, test characteristics (including 95% CI) for eFAST compared with CT scan for detecting haemoperitoneum were as follows: sensitivity 75% (35%–97%), specificity 97% (93%–99%), PPV 55% (23%–83%) and NPV 99% (96%–99%).

Conclusions In patients admitted with stab wounds to the torso, eFAST was not sensitive enough to diagnose pneumothorax and haemoperitoneum, but performed better in the detection of cardiac tamponade and haemothorax than the other injuries. More robust multicentre studies are needed to better define the role of eFAST in this specific population.

INTRODUCTION

Trauma is a major worldwide public health issue, causing disability, morbidity and significant mortality.¹

WHAT IS ALREADY KNOWN ON THIS TOPIC

⇒ While the place of Extended Focused Assessment with Sonography in Trauma (eFAST) has been evaluated in the management of severe trauma, its performance in the investigation of stab wound injuries has never been assessed.

WHAT THIS STUDY ADDS

⇒ In this prospective study involving only patients with stab wounds to the torso, eFAST was not sensitive enough to diagnose pneumothorax and intra-abdominal injury, but performed better in the detection of cardiac tamponade and haemothorax.

HOW THIS STUDY MIGHT AFFECT RESEARCH, PRACTICE OR POLICY

⇒ In this population of patients with thoracic or abdominal stab wounds, a CT scan may not be required in the event of haemothorax and/or cardiac tamponade detected on eFAST.

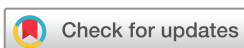In trauma resulting from acts of violence, penetrating gunshot and stab wounds result in specific clinical patterns and management strategies that are different from accidental injuries such as motor vehicle collisions.² While the role of Extended Focused Assessment with Sonography in Trauma (eFAST) is well defined in the management of blunt trauma,³ its use in thoracic and abdominal stab wound injuries is less clearly defined. In contrast to well-powered studies enrolling gunshot injury patients,⁴ only case reports or small studies have been performed to analyse the use of eFAST in stab wound injuries, with disparate results.^{5–14}

The present study aimed to assess the diagnostic performance of eFAST in a population of intensive care unit (ICU) patients with stab wound injuries to the torso.

METHODS

Design

The FETTHA (Fast-Echographie dans les Traumatismes THoraciques et Abdominaux) study is a prospective observational study conducted from 1 December 2016 to 31 December 2018, in the ICU



© Author(s) (or their employer(s)) 2023. No commercial re-use. See rights and permissions. Published by BMJ.

To cite: Bouzid D, Tran-Dinh A, Lortat-Jacob B, et al. *Emerg Med J* Epub ahead of print: [please include Day Month Year]. doi:10.1136/emered-2023-213078

of a French academic hospital. Given this was a diagnostic accuracy study, the Standards for Reporting Diagnostic Accuracy (STARD) checklist was used.¹⁵

Patients

Consecutive patients aged 16 years and older admitted to our ICU with thoracic and/or abdominal stab wounds were included in this study. All stab wound injuries addressed in our hospital are directly admitted to our ICU.

Exclusion criteria included isolated head, cervical or limb wounds without thoracic or abdominal involvement, secondary transfer from another hospital and gunshot wound injuries.

All patients were assessed and treated by the trauma team in the ICU in accordance with standard protocols.¹⁶

Intervention

At the time of patient admission to the ICU, the usual procedures in our department consist of a clinical examination followed by an eFAST examination performed by one ICU senior physician with at least 3 years of experience from a team of eight ICU senior physicians. The device used for the eFAST is an Affinity 70 G (Koninklijke Philips N.V., Netherlands). A low-frequency phased array probe (2–5 MHz) (Koninklijke Philips N.V.) is used for the investigation.

The eFAST protocol consists of a combined ultrasonographic evaluation of the chest and abdomen, allowing the detection of different injuries, including pneumothorax (PTX), haemothorax (HTX), pericardial effusion and haemoperitoneum. To define the anatomical location of the injury, the wound site is divided into three areas (thorax, thoracoabdominal and abdominal), as defined in a previous study.¹⁷ The thoracoabdominal area is defined by the upper boundary of the fourth intercostal space (anterior), the sixth intercostal space (lateral), the eighth intercostal space (posterior) and the lower edge of the ribs.

After the eFAST, patients undergo a contrast-enhanced thoracoabdominal CT scan (One Aquilion, GENESIS, Canon, Otawara, Tochigi, Japan). In the event of haemodynamic instability (systolic BP <90 mmHg)¹⁸ or respiratory compromise (oxygen saturation (SpO₂) <90% at admission)¹⁹ with an eFAST diagnosis justifying emergency surgery, the CT scan is not performed, and the patient is immediately transferred to the operating theatre. The CT scan is interpreted by a senior radiologist unaware of the results of the eFAST. Patients then undergo subsequent surgical exploration according to their clinical presentation, severity and imaging results.

Data collection

An ICU resident of the department collected baseline characteristics, including demographic data, time of injury, type of weapon, pre-hospital treatment and medical history. eFAST and thoracoabdominal CT scan data were prospectively collected. We also compiled all information related to ICU stay, including Simplified Acute Physiology Score II (SAPS-II), need for mechanical ventilation, vasopressor administration, ICU and hospital length of stay and 28-day mortality. No missing data were observed among the variables collected for the study.

Statistical analysis

Statistical analysis was performed using STATA V.15 (Stata Corp LLC, USA). All continuous parameters are reported as medians and IQRs, and frequency values are presented as absolute values and percentages. The diagnostic performance of eFAST was evaluated by assessing the sensitivity (Se), specificity (Sp),

positive predictive value (PPV), negative predictive value (NPV) and accuracy (Acc) for each thoracic and abdominal pathological finding, including the detection of free fluid in each eFAST examination view. Injuries in the thoracoabdominal area were considered in both the thoracic and abdominal injury groups for this analysis. The CT scan findings were considered the gold standard for evaluating the sensitivity and specificity of the eFAST.

RESULTS

Patients

During the study period, 217 patients were admitted with penetrating injury. Of these, 17 patients were excluded (12 patients were admitted with gunshot wounds and 5 patients had stab wounds outside the thoracic or abdominal areas). The remaining 200 patients were included in the FETTHA study analysis: 86 patients with thoracic stab wounds, 68 patients with thoracoabdominal stab wounds and 32 patients with abdominal stab wounds (figure 1). Fourteen unstable patients underwent exploratory surgery immediately after eFAST, without undergoing CT scanning.

Patient characteristics, types of injury and outcomes of the 200 patients (186 stable and 14 unstable) are presented in table 1.

Unstable cases

Fourteen patients were transferred to the operating theatre directly after eFAST and therefore did not undergo a CT. Of these, one patient underwent surgical haemostasis for massive HTX, and two patients had liver or bowel injuries. Nine patients had cardiac tamponade identified by eFAST and confirmed by surgery. Two unstable patients did not have any injury reported during the emergency laparotomy (haemodynamic instability in the context of drug use).

eFAST diagnostic performances in thoracic and abdominal injuries

Following systematic eFAST examination, a CT scan was performed in 186 patients (151 thoracic stab wounds and 99 abdominal stab wounds) within a median time of 30 min (IQR 20–49 min) after admission. Multiple injuries were observed in 85 patients (46%), the median number of injuries was 1.^{1–3}

eFAST findings

eFAST identified 28 patients with PTX, 36 with HTX and 11 with haemoperitoneum (caused by gastric, bowel, spleen or liver injuries, one of which required direct surgery for hepatic haemostasis). In 18 cases, eFAST was considered normal, while the CT scan was abnormal.

CT scan findings

The CT scan identified 22 patients with PTX and 31 with HTX. In four cases, CT scans detected minimal PTX, and in three cases, subcutaneous emphysema was detected, which did not require any specific treatment. Eleven patients had abnormal abdominal findings (hepatic, splenic contusion or laceration, pneumoperitoneum) on CT scan. In three other cases, the CT scan suggested the presence of intraperitoneal fluid, but laparoscopy was normal.

Surgical findings

Overall, 86 out of 186 (46%) patients had superficial injury without thoracic or abdominal cavity penetration and required simple stitching with an uneventful course. Thirty-two patients

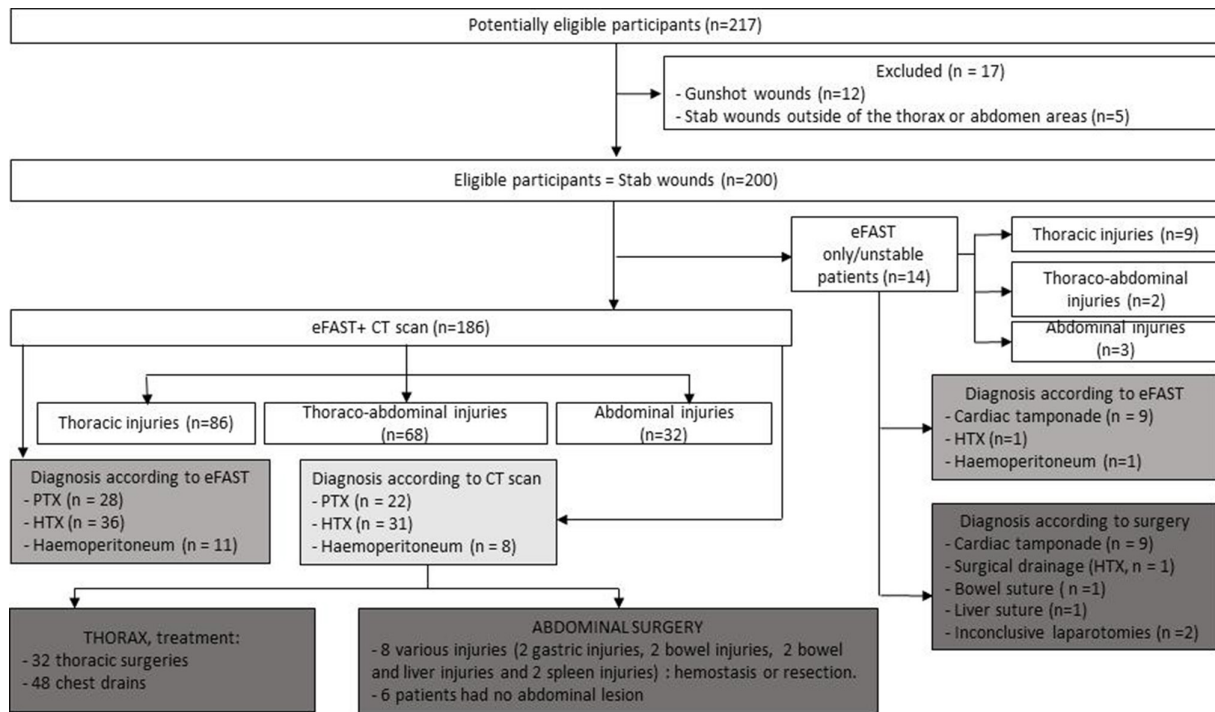


Figure 1 Study flowchart. eFAST, Extended Focused Assessment with Sonography in Trauma; HTX, haemothorax; PTX, pneumothorax.

underwent surgical procedures for thoracic injuries, while 48 patients underwent thoracic intercostal drainage. Fourteen patients underwent abdominal surgery, of which eight cases showed evidence of various injuries (two gastric, two bowel, two spleen, two patients had bowel and liver injuries) and six cases had no abnormality detected at laparoscopy; among them, three CT scans suggested the presence of intraperitoneal fluid. Six patients had a surgical exploration for limb injuries.

The test characteristics of eFAST compared with CT are shown in [table 2](#). Cross-tabulations are presented in online supplemental table 1.

	Total patients n=200	Unstable patients n=14	Stable patients n=186
Age (years), median (IQR)	30 (23–40)	26 (22–46)	30 (23–38)
Male sex, n (%)	182 (91%)	12 (86%)	170 (91%)
Thoracic injury, n (%)	95 (48%)	8 (57%)	87 (47%)
Thoracoabdominal injury, n (%)	70 (35%)	6 (43%)	64 (34%)
Abdominal injury, n (%)	35 (17%)	0 (0%)	35 (19%)
Systolic BP (mm Hg), median (IQR)	121 (112–134)	90 (82–105)	122 (112–134)
Diastolic BP (mm Hg), median (IQR)	71 (65–84)	60 (54–74)	72 (65–86)
Heart rate (/min), median (IQR)	85 (77–100)	95 (90–117)	82 (72–92)
Respiratory rate (/min), median (IQR)	18 (15–22)	22 (18–26)	18 (15–22)
Glasgow Coma Score, median (IQR)	15 (15)	15 (15)	15 (15)
SAPS-II on ICU admission, median (IQR)	8 (6–11)	12 (9–16)	8 (5–9)
ISS on ICU admission, median (IQR)	6 (4–9)	12 (9–16)	4 (4–9)
ICU length of stay, median (IQR)	1 (1)	3 (1–5)	1 (1)
Hospital length of stay, median (IQR)	2 (1–4)	14 (4–16)	1 (1–4)
28-day mortality, n (%)	2 (1%)	2 (14%)	0 (0%)
ICU, intensive care unit; ISS, Injury Severity Score; SAPS-II, Simplified Acute Physiology Score II.			

DISCUSSION

In this study of 200 patients with chest or abdominal stab wounds, eFAST showed high accuracy in diagnosing cardiac tamponade. For the diagnosis of pneumothorax, eFAST has high specificity and good NPV but only moderate sensitivity in comparison to CT scans. eFAST performs well in detecting HTX but poorly in detecting intra-abdominal injuries. A negative eFAST does not adequately rule out potentially life-threatening injuries, in which case further evaluation with CT is still required.

Whereas many studies on trauma frequently include a combination of different mechanisms,^{2,20,21} our study focuses on eFAST in a homogeneous population of penetrating stab wounds.

Regarding patients with haemodynamic or respiratory instability, our study showed that eFAST detected all cases of cardiac tamponade, leading to a surgical procedure without a CT scan. Tayal *et al*, in a study of both stab and gunshot wounds, reported that eFAST had a sensitivity and a specificity of 100% in patients with cardiac tamponade.¹² In a same mixed population, Matsushima *et al* also found very high eFAST sensitivity and specificity.¹⁴ Nevertheless, the literature on this subject is scarce.

When comparing eFAST to CT, Soffer *et al* in a stable heterogeneous population of both stab and gunshot injuries, showed that eFAST lacked the sensitivity to be used alone in determining operative intervention.⁸ Moreover, in a large prospective cohort enrolling 601 heterogeneous trauma patients, Zanobetti *et al* evaluated the diagnostic performance of eFAST compared with CT.²² For the diagnosis of PTX, performance was slightly better than in our cohort (sensitivity 84% (77–89) vs 77% (54–92); NPV 95% (93–97) vs 97% (93–99)). Nevertheless, our study was exploratory and based on a small cohort of patients; at this stage, it does not seem appropriate to avoid a CT scan in all circumstances, as a CT will allow a better characterisation of PTX, its size and localisation.²³ In contrast, for HTX, the performance was better in our study than in Zanobetti *et al*'s study (sensitivity 97% (74–99) vs 82% (74–88)).

Table 2 Results of eFAST diagnostic performances compared with CT scans in the 186 stable patients

eFAST	Sensitivity (%) 95% CI	Specificity (%) 95% CI	PPV (%) 95% CI	NPV (%) 95% CI	Acc (%)
PTX	77% (54%–92%)	93% (90%–97%)	60% (49%–83%)	97% (93%–99%)	92%
HTX	97% (74%–99%)	96% (92%–98%)	83% (63%–93%)	99% (96%–100%)	96%
Haemoperitoneum	75% (35%–97%)	97% (93%–99%)	55% (23%–83%)	99% (96%–99%)	96%

Acc, accuracy; HTX, haemothorax; NPV, negative predictive value; PPV, positive predictive value; PTX, pneumothorax.

Our findings suggested a higher accuracy than the results of a meta-analysis reporting 12 studies evaluating eFAST in trauma patients (sensitivity and specificity in the detection of HTX of 67% and 99%, respectively).²⁴ Similar to the Zanobetti *et al* study, NPV was also very high (99% vs 97%). The high performance of eFAST for the detection of HTX in our study is very encouraging. According to our findings, the presence of HTX on eFAST is a good argument for treating HTX (medical drainage, surgical management or simple monitoring according to the volume found) without performing a CT scan. Nevertheless, before that, it seems necessary to perform a randomised study including a high number of patients.

Globally, our results emphasise that eFAST is a useful tool in managing patients with torso stab wounds but is not sufficient for diagnosis alone, especially for the diagnosis of PTX.

Concerning the eFAST performances in our cohort of patients, sensitivity to detect intraperitoneal fluid was low (sensitivity 75%). This result could be explained by the high sensitivity of CT to detect small amounts of intraperitoneal fluid compared with eFAST. The delay between the eFAST and the CT scan (median of 30 min in our study) could also explain the different findings between these two modalities.

In line with our study, Udobi *et al* showed that 13 (32%) of 41 patients with abdominal injuries had a false-negative eFAST concerning various injuries (ie, liver, small bowel, colon, stomach, spleen, gall bladder or kidney) identified during surgery.⁹ In a recent German study, FAST had a sensitivity and specificity of 59.4% and 94.2%, respectively, while CT scans had a sensitivity and specificity of 93.2% and 85.1%, respectively, in detecting intraperitoneal fluid.²⁵ In a retrospective study involving 103 patients with stab and gunshot wounds, sensitivity and specificity of the abdominal FAST was 68.5 and 93.9%, respectively.¹⁴ Finally, in a population of 72 various trauma mechanisms (31 stab wounds, 37 gunshot wounds and 4 other wounds), Boulanger *et al* showed that the sensitivity of eFAST for abdominal injury was 67%, the specificity was 98%, the PPV was 92% and the NPV was 89%.¹¹ Our study reports slightly inferior performances compared with those of previous studies. Thus, even if eFAST seems to be a potentially useful tool to detect intraperitoneal fluid, a negative eFAST examination does not exclude abdominal injuries, such as a diaphragm or hollow viscus perforation.

This is a relatively small single centre study and therefore our findings should be interpreted in that context. Another limitation is that we did not stratify the performance of the eFAST by experience of physicians, which varied from 3 to 6 years. This type of stratification should be considered in a future multi-centre study. Third, we collected the eFAST data only at admission. Performing the eFAST at the same time as the CT scan (ie, without the delay of 30 min between the two investigations) could be very informative.

In conclusion, in a population of 200 patients with chest and abdominal stab wounds, eFAST does not accurately detect PTX when compared with CT scan. eFAST can

accurately detect cardiac tamponade and HTX, allowing physicians to proceed with treatment without a CT scan in the presence of these entities. Moreover, our study confirms that some abdominal injuries are still underdetected with ultrasound compared with CT scan. Further multicentre studies should be conducted to further assess the diagnostic performance of eFAST in this specific population of patients with torso stab wounds.

Author affiliations

¹Université Paris Cité, Paris, France

²INSERM UMR1137, IAME, F-75006, Paris, France

³Université de Montpellier, VBMI, INSERM U1047, Nîmes, France

⁴AP-HP Nord, Emergency Department, Bichat-Claude Bernard University Hospital, Paris, France

⁵AP-HP Nord, Anesthesiology and Intensive Care Department, Bichat-Claude Bernard University Hospital, Paris, France

⁶INSERM UMR1148, Paris, France

⁷AP-HP Nord, Thoracic and Vascular Surgery Department, Bichat-Claude Bernard University Hospital, Paris, France

⁸AP-HP Nord, Visceral Surgery Department, Bichat-Claude Bernard University Hospital, Paris, France

⁹AP-HP Nord, Radiology Department, Bichat-Claude Bernard University Hospital, Paris, France

¹⁰PHERE, Physiopathology and Epidemiology of Respiratory Diseases, French Institute of Health and Medical Research (INSERM) U1152, Paris, France

¹¹INSERM UMR1188, Saint-Denis de la Réunion, France

Collaborators Bichat stab wounds injury study group: AH, AEK, AY, AM, AS, AG, BP, MA, NC, CDT, CD, DL, EK, FL, IB, JS, LS, LC, MR, MBR, RS, YR, SR, SB, SY, JV, PM, AG, AR, JS, KA, LR, SM.

Contributors DB, ST and PM contributed to study concept and design. DB and ST performed statistical analysis. DB, ST, ATD, BLJ, EA, SJB, PT, AS, NZ, PA, QP, YC, LR and PM were involved in patient care and data collection. AG and AK blindly interpreted CT scan data. DB, ST, ATD, EA, NZ and PM were involved in data analysis and interpretation. DB, ST, ATD and PM performed critical revision of the manuscript. All the authors read and approved the final manuscript. ST is the guarantor.

Funding The authors have not declared a specific grant for this research from any funding agency in the public, commercial or not-for-profit sectors.

Competing interests None declared.

Patient and public involvement Patients and/or the public were not involved in the design, or conduct, or reporting or dissemination plans of this research.

Patient consent for publication Consent obtained directly from patient(s)

Ethics approval This study involves human participants and was approved by CPP Lyon Sud, France (reference/approval ID: RCB 2017-A00001-52). Participants gave informed consent before taking part. Participants gave informed consent to participate in the study before taking part.

Provenance and peer review Not commissioned; externally peer reviewed.

Data availability statement Data are available upon reasonable request.

Supplemental material This content has been supplied by the author(s). It has not been vetted by BMJ Publishing Group Limited (BMJ) and may not have been peer-reviewed. Any opinions or recommendations discussed are solely those of the author(s) and are not endorsed by BMJ. BMJ disclaims all liability and responsibility arising from any reliance placed on the content. Where the content includes any translated material, BMJ does not warrant the accuracy and reliability of the translations (including but not limited to local regulations, clinical guidelines, terminology, drug names and drug dosages), and is not responsible for any error and/or omissions arising from translation and adaptation or otherwise.

ORCID iD

Sebastien Tanaka <http://orcid.org/0000-0003-4698-3287>

REFERENCES

- 1 Ameratunga S, Hajar M, Norton R. Road-traffic injuries: confronting disparities to address a global-health problem. *The Lancet* 2006;367:1533–40.
- 2 Descamps C, Hamada S, Hanouz J-L, et al. Gunshot and stab wounds in France: descriptive study from a national trauma Registry. *Eur J Trauma Emerg Surg* 2022;48:3821–9.
- 3 Gaarder C, Kroepelien CF, Loekke R, et al. Ultrasound performed by Radiologists-confirming the truth about FAST in trauma. *J Trauma* 2009;67:323–7.
- 4 Boulanger BR, McLellan BA, Brenneman FD, et al. Prospective evidence of the superiority of a Sonography-based algorithm in the assessment of blunt abdominal injury. *J Trauma* 1999;47:632–7.
- 5 Khaladj N, Knobloch K, Winterhalter M, et al. Transthoracic echocardiography as a diagnostic tool in patients with Thoracic stab wounds: early ultrasonographic evaluation in the emergency room. *Unfallchirurg* 2008;111:107–11.
- 6 Hart D, Budhram G, Reardon R, et al. Bedside echocardiography in the management of a Thoracic stab wound with early Pericardial Tamponade. *Acad Emerg Med* 2008;15:1322–3.
- 7 Reardon R, Joing S. Hemothorax after a stab wound to the chest, with clear breath sounds and a normal radiograph. *Acad Emerg Med* 2006;13:786.
- 8 Soffer D, McKenney MG, Cohn S, et al. A prospective evaluation of Ultrasonography for the diagnosis of penetrating torso injury. *J Trauma* 2004;56:953–7.
- 9 Udobi KF, Rodriguez A, Chiu WC, et al. Role of Ultrasonography in penetrating abdominal trauma: a prospective clinical study. *J Trauma* 2001;50:475–9.
- 10 Boulanger BR, Brenneman FD, Kirkpatrick AW, et al. The indeterminate abdominal sonogram in Multisystem blunt trauma. *J Trauma* 1998;45:52–6.
- 11 Boulanger BR, Kearney PA, Tsuei B, et al. The routine use of Sonography in penetrating torso injury is beneficial. *J Trauma* 2001;51:320–5.
- 12 Tayal VS, Beatty MA, Marx JA, et al. FAST (focused assessment with Sonography in trauma) accurate for cardiac and intraperitoneal injury in penetrating anterior chest trauma. *Journal of Ultrasound in Medicine* 2004;23:467–72.
- 13 Soto JA, Morales C, Múnera F, et al. Penetrating stab wounds to the abdomen: use of serial US and contrast-enhanced CT in stable patients. *Radiology* 2001;220:365–71.
- 14 Matsushima K, Khor D, Berona K, et al. Double jeopardy in penetrating trauma: get FAST, get it right. *World J Surg* 2018;42:99–106.
- 15 Bossuyt PM, Reitsma JB, Bruns DE, et al. STARD 2015: an updated list of essential items for reporting diagnostic accuracy studies. *BMJ* 2015;351:h5527.
- 16 Desai N, Harris T. Extended focused assessment with Sonography in trauma. *BJA Educ* 2018;18:57–62.
- 17 Mariadason JG, Parsa MH, Ayuyao A, et al. Management of stab wounds to the Thoracoabdominal region. A clinical approach. *Ann Surg* 1988;207:335–40.
- 18 Loggers SAI, Koedam TWA, Giannakopoulos GF, et al. Definition of hemodynamic stability in blunt trauma patients: a systematic review and assessment amongst Dutch trauma team members. *Eur J Trauma Emerg Surg* 2017;43:823–33.
- 19 Požgaj Z, Kristek D, Lovrić I, et al. Pulmonary contusions after blunt chest trauma: clinical significance and evaluation of patient management. *Eur J Trauma Emerg Surg* 2018;44:773–7.
- 20 Sander A, Spence R, Ellsmere J, et al. Penetrating abdominal trauma in the era of selective conservatism: a prospective cohort study in a level 1 trauma center. *Eur J Trauma Emerg Surg* 2022;48:881–9.
- 21 Pereira BMT, Nogueira VB, Calderan TRA, et al. Penetrating cardiac trauma: 20-Y experience from a university teaching hospital. *J Surg Res* 2013;183:792–7.
- 22 Zanobetti M, Coppa A, Nazerian P, et al. Chest abdominal-focused assessment Sonography for trauma during the primary survey in the emergency Department: the CA-FAST protocol. *Eur J Trauma Emerg Surg* 2018;44:805–10.
- 23 Frongillo E, Rea G, Tinti MG, et al. Limitations of focused assessment with Sonography in trauma (FAST) protocols in transthoracic US. *Radiology* 2017;285:693–4.
- 24 Rahimi-Movaghar V, Yousefifard M, Ghelichkhani P, et al. Application of Ultrasonography and radiography in detection of Hemothorax; a systematic review and meta-analysis. *Emerg Tehran Iran* 2016;4:116–26.
- 25 Malkomes P, Störmann P, El Youzouri H, et al. Characteristics and management of penetrating abdominal injuries in a German level I trauma center. *Eur J Trauma Emerg Surg* 2019;45:315–21.

Supplemental Table S1 : eFAST diagnostic performances compared to CT scans: cross-tabulations

PTX	CT-scan positive	CT-scan negative	Total
eFAST positive	17	11	28
eFAST negative	5	153	158
Total	22	165	186
HTX	CT-scan positive	CT-scan negative	Total
eFAST positive	30	6	36
eFAST negative	1	149	150
Total	31	155	186
Haemoperitoneum	CT-scan positive	CT-scan negative	Total
eFAST positive	6	5	11
eFAST negative	2	173	175
Total	8	178	186

PTX : pneumothorax , HTX : haemothorax.