

I JOINED USACS TO MAKE A BIGGER IMPACT IN INNOVATION^{1,2,3}

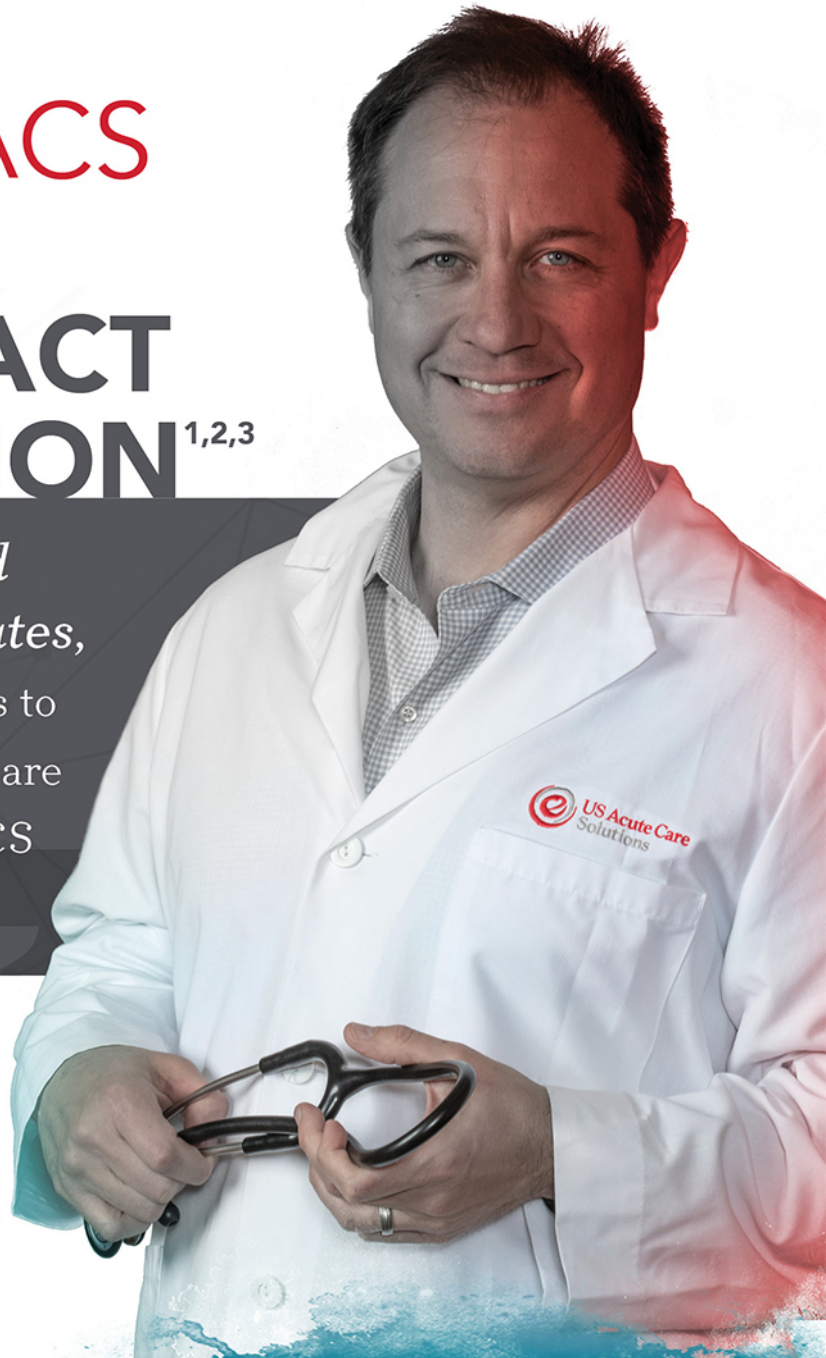With more than 500 EM and inpatient programs in 30 states, USACS offers unparalleled access to a network to advance innovative care and improve outcomes. Let USACS help you make a difference too.

Jesse Pines, MD

EM Residency: University of Virginia (2004)
National Director of Clinical Innovation

REFERENCES:

1. Oskvarek JJ, Pines JM; US Acute Care Solutions Research Group. Opioid Prescription Reduction After Implementation of a Feedback Program in a National Emergency Department Group. *Ann Emerg Med.* 2022 May;79(5):420-432.
2. Pines JM, et al. The Impact of Advanced Practice Provider Staffing on Emergency Department Care: Productivity, Flow, Safety, and Experience. *Acad Emerg Med.* 2020 Nov;27(11):1089-1099.
3. Pines JM, et al. Under the Microscope: High Variability and Limited Construct Validity in Emergency Department Patient-Experience Scores. *Ann Emerg Med.* 2018 May;71(5):545-554.e6.



EM CAREERS NATIONWIDE



US Acute Care Solutions

All full-time physicians are provided:

Company stock ownership | 10% company-funded 401(k) | 24/7 on-shift clinical support
Great locations nationwide | The best health and wellness benefits | A mission that has real meaning

Learn more at: usacs.com



CONSENSUS STATEMENT

Guidelines for reasonable and appropriate care in the emergency department 3 (GRACE-3): Acute dizziness and vertigo in the emergency department

Jonathan A. Edlow FACEP, MD^{1,2} | Christopher Carpenter MD, MSC^{3,4} |
 Murtaza Akhter MD^{5,6} | Danya Khoujah MD^{7,8} | Evie Marcolini MD^{9,10} |
 William J. Meurer MD¹¹ | David Morrill¹² | James G. Naples MD^{1,13} |
 Robert Ohle MBBCh, MA, MSc^{14,15,16} | Rodney Omron MD, MPH^{17,18} |
 Sameer Sharif MD, BMSc (Hon.)¹⁹ | Matt Siket MD^{20,21} |
 Suneel Upadhye MD, MSc^{22,23} | Lucas Oliveira J. e Silva MD, MS^{24,25} |
 Etta Sundberg²⁶ | Karen Tartt^{27,28} | Simone Vanni MD^{29,30} |
 David E. Newman-Toker MD, PhD³¹ | Fernanda Bellolio MD, MS^{32,33}

¹Department of Emergency Medicine, Harvard Medical School, Boston, Massachusetts, USA

²Department of Emergency Medicine, Beth Israel Deaconess Medical Center, Boston, Massachusetts, USA

³Department of Emergency Medicine, Washington University School of Medicine, St. Louis, Missouri, USA

⁴Department of Emergency Medicine, Washington University, St. Louis, Missouri, USA

⁵Department of Emergency Medicine, Penn State School of Medicine, State College, Pennsylvania, USA

⁶Hershey Medical Center, State College, Pennsylvania, USA

⁷Department of Emergency Medicine, University of Maryland School of Medicine, Baltimore, Maryland, USA

⁸Department of Emergency Medicine, Adventhealth Tampa, Tampa, Florida, USA

⁹Department of Emergency Medicine, Geisel School of Medicine, Dartmouth, Hanover, New Hampshire, USA

¹⁰Department of Emergency Medicine, Dartmouth-Hitchcock Medical Center, Lebanon, New Hampshire, USA

¹¹Department of Emergency Medicine, University of Michigan Medical School, Ann Arbor, Michigan, USA

¹²Patient Representative, Lakeland, Florida, USA

¹³Division of Otolaryngology-Head & Neck Surgery, Beth Israel Deaconess Medical Center, Boston, Massachusetts, USA

¹⁴Department of Emergency Medicine, Northern Ontario School of Medicine, Sudbury, Ontario, Canada

¹⁵Health Science North Research Institute, Sudbury, Ontario, Canada

¹⁶Department of Emergency Medicine, Health Sciences North, Sudbury, Ontario, Canada

¹⁷Department of Emergency Medicine, Johns Hopkins University School of Medicine, Baltimore, Maryland, USA

¹⁸Department of Emergency Medicine, Johns Hopkins Hospital, Baltimore, Maryland, USA

¹⁹Division of Critical Care and Emergency Medicine, Department of Medicine, McMaster University, Hamilton, Ontario, Canada

²⁰Department of Emergency Medicine, Robert Larner College of Medicine at the University of Vermont, Burlington, Vermont, USA

²¹Department of Emergency Medicine, Larner College of Medicine, University of Vermont, Burlington, Vermont, USA

²²Emergency Medicine, Evidence and Impact (HEI), McMaster University, Burlington, Ontario, Canada

²³Health Research Methods, Evidence and Impact (HEI), McMaster University, Burlington, Ontario, Canada

²⁴Mayo Clinic, Rochester, Minnesota, USA

²⁵Department of Emergency Medicine, Hospital de Clinicas de Porto Alegre, Porto Alegre, Rio Grande do Sul, Brazil

²⁶COO Royal Oasis Pool and Spas, Las Vegas, Nevada, USA

Jonathan A. Edlow and Christopher Carpenter contributed equally as first authors.

Fernanda Bellolio and David E. Newman-Toker contributed equally as senior authors.

Supervising Editor: Dr. Jeffrey Kline

²⁷Absinthe Brasserie & Bar, San Francisco, California, USA

²⁸St. George Spirits, San Francisco, California, USA

²⁹Department of Emergency Medicine, University of Florence, Firenze, Italy

³⁰Department of Emergency Medicine, University Hospital Careggi, Firenze, Italy

³¹Department of Neurology, Johns Hopkins University School of Medicine, Baltimore, Maryland, USA

³²Mayo Clinic College of Medicine, Rochester, Minnesota, USA

³³Department of Emergency Medicine, Mayo Clinic, Rochester, Minnesota, USA

Correspondence

Jonathan A. Edlow, Department of Emergency Medicine, Beth Israel Deaconess Medical Center, Boston, MA 02215, USA.

Email: jedlow@bidmc.harvard.edu

Funding information

Society for Academic Emergency Medicine

Abstract

This third Guideline for Reasonable and Appropriate Care in the Emergency Department (GRACE-3) from the Society for Academic Emergency Medicine is on the topic adult patients with acute dizziness and vertigo in the emergency department (ED). A multidisciplinary guideline panel applied the Grading of Recommendations Assessment, Development, and Evaluation (GRADE) approach to assess the certainty of evidence and strength of recommendations regarding five questions for adult ED patients with acute dizziness of less than 2 weeks' duration. The intended population is adults presenting to the ED with acute dizziness or vertigo. The panel derived 15 evidence-based recommendations based on the timing and triggers of the dizziness but recognizes that alternative diagnostic approaches exist, such as the STANDING protocol and nystagmus examination in combination with gait unsteadiness or the presence of vascular risk factors. As an overarching recommendation, (1) emergency clinicians should receive training in bedside physical examination techniques for patients with the acute vestibular syndrome (AVS; HINTS) and the diagnostic and therapeutic maneuvers for benign paroxysmal positional vertigo (BPPV; Dix-Hallpike test and Epley maneuver). To help distinguish central from peripheral causes in patients with the AVS, we recommend: (2) use HINTS (for clinicians trained in its use) in patients with nystagmus, (3) use finger rub to further aid in excluding stroke in patients with nystagmus, (4) use severity of gait unsteadiness in patients without nystagmus, (5) do *not* use brain computed tomography (CT), (6) do *not* use routine magnetic resonance imaging (MRI) as a first-line test if a clinician trained in HINTS is available, and (7) use MRI as a confirmatory test in patients with central or equivocal HINTS examinations. In patients with the spontaneous episodic vestibular syndrome: (8) search for symptoms or signs of cerebral ischemia, (9) do *not* use CT, and (10) use CT angiography or MRI angiography if there is concern for transient ischemic attack. In patients with the triggered (positional) episodic vestibular syndrome, (11) use the Dix-Hallpike test to diagnose posterior canal BPPV (pc-BPPV), (12) do *not* use CT, and (13) do *not* use MRI routinely, unless atypical clinical features are present. In patients diagnosed with vestibular neuritis, (14) consider short-term steroids as a treatment option. In patients diagnosed with pc-BPPV, (15) treat with the Epley maneuver. It is clear that as of 2023, when applied in routine practice by emergency clinicians without special training, HINTS testing is inaccurate, partly due to use in the wrong patients and partly due to issues with its interpretation. Most emergency physicians have not received training in use of HINTS. As such, it is not standard of care, either in the legal sense of that term ("what the average physician would do in similar circumstances") or in the common parlance sense ("the standard action typically used by physicians in routine practice").

AT-A-GLANCE SUMMARY

In emergency department (ED) patients with new dizziness or vertigo without an obvious medical or neurological cause, the first step is to try to determine which presenting syndrome the patient has, based on the timing and triggers of symptoms (see [Figure 1](#)). As with any patient with any chief complaint, some patients are not able to unambiguously report the timing and triggers of their symptoms. In situations in which the timing and triggers category is unclear, other diagnostic frameworks, such as the STANDING protocol and various combinations of HINTS components and gait unsteadiness or vascular risk factors, may also be diagnostically useful. Because these physical examination elements are not commonly used in routine emergency medicine practice, their incorporation into practice is aspirational and represents a forward-looking policy to improve care of these patients.

- Acute vestibular syndrome (AVS): acute onset of continuous, persistent dizziness or vertigo lasting longer than 24 h (see [Figure 1](#)).
- Spontaneous episodic vestibular syndrome (s-EVS): one or more discrete episodes of untriggered, spontaneous dizziness or vertigo (see [Figure 1](#)).
- Triggered (positional) episodic vestibular syndrome (t-EVS): one or more discrete very brief episodes of triggered, positional dizziness or vertigo. (see [Figure 1](#)).

One recommendation is based on training. Most of the specific recommendations are based on these timing and trigger categories and some are based on particular diagnoses.

Training	Recommendation
Training of emergency clinicians	FOR: Emergency clinicians should receive training in bedside physical examination techniques for patients with the AVS (HINTS) and diagnostic and therapeutic maneuvers for benign paroxysmal positional vertigo (BPPV; Dix–Hallpike test and Epley maneuver)
Presenting syndrome	Recommendation
AVS	<p>FOR: Diagnosis using HINTS testing to distinguish a peripheral vestibular disorder (usually vestibular neuritis) from a central one (usually stroke) by an appropriately trained clinician:</p> <ul style="list-style-type: none"> If examination confirms a peripheral disorder, then treat accordingly; no imaging required If examination suggests stroke or a central cause, obtain confirmatory magnetic resonance imaging with diffusion-weighted images [MRI-DWI] and/or consult neurology <p>NEXT BEST: MRI-DWI if no one qualified in using the HINTS examination is readily available</p> <p>AGAINST: CT with or without CT angiography (CTA)/CT cerebral perfusion analysis (CTP)</p>

Training	Recommendation
s-EVS	<p>FOR: Diagnosis using history taking</p> <ul style="list-style-type: none"> If the clinical impression suggests a benign cause (vestibular migraine or Menière disease), refer to vestibular specialist If history suggests TIA, manage as TIA; obtain vascular imaging (CT angiography [CTA] or MRI angiography [MRA]) of the head and neck and/or consult neurology <p>AGAINST: Routine neuroimaging in those at low risk of TIA</p>
t-EVS	<p>FOR: Diagnosis using Dix–Hallpike test for posterior canal BPPV (pc-BPPV) by an appropriately trained clinician</p> <ul style="list-style-type: none"> If examination confirms pc-BPPV, then treat accordingly; no imaging required if patient responds to repositioning If examination suggests a central mimic or appropriate treatment with a repositioning maneuver fails, consider obtaining an MRI-DWI and/or consult neurology <p>NEXT BEST: Urgent (<72h) referral for diagnosis as an outpatient, ideally to an appropriately trained specialist.</p> <p>AGAINST: CT with or without CTA/CTP</p>

Specific diagnoses

Vestibular neuritis	FOR: Shared decision making weighing risks and benefits of short-term steroid treatment for vestibular neuritis among patients presenting within three days of symptom onset
BPPV	<p>FOR: Bedside Epley canalith repositioning maneuver for pc-BPPV (diagnosed using the Dix–Hallpike test) in the ED by an appropriately trained clinician</p> <p>NEXT BEST: Urgent outpatient referral for treatment <72h, ideally by an appropriately trained specialist</p> <p>AGAINST: Outpatient vestibular suppressant therapy such as meclizine</p>

Ideally, refer discharged patients both to an appropriate specialist (e.g., otorhinolaryngologist, neurologist, or other specialist with advanced vestibular training when available in that practice setting) and to their primary care physician for further evaluation and treatment. If these physicians are not available in a given setting within a reasonable time frame, a physical therapist with advanced vestibular training may be the best referral choice. Vestibular neuritis is caused by inflammation of the vestibular component of the eighth cranial nerve, thought to be similar to Bell's palsy of the seventh cranial nerve. Refer all patients diagnosed with vestibular neuritis for vestibular rehabilitation therapy whether or not steroids are used and, if an outpatient vestibular suppressant regimen (e.g., meclizine) is needed, it should only be administered short term (i.e., no longer than 3–5 days; a sample discharge instruction sheet is included in [Appendix S9](#)).

For patients with suspected BPPV whose Dix–Hallpike test shows horizontal nystagmus or no nystagmus, instead of the expected upbeat (vertical upward)–torsional nystagmus, as illustrated in [Figures 2 and 7](#), consider the diagnosis of horizontal canal BPPV

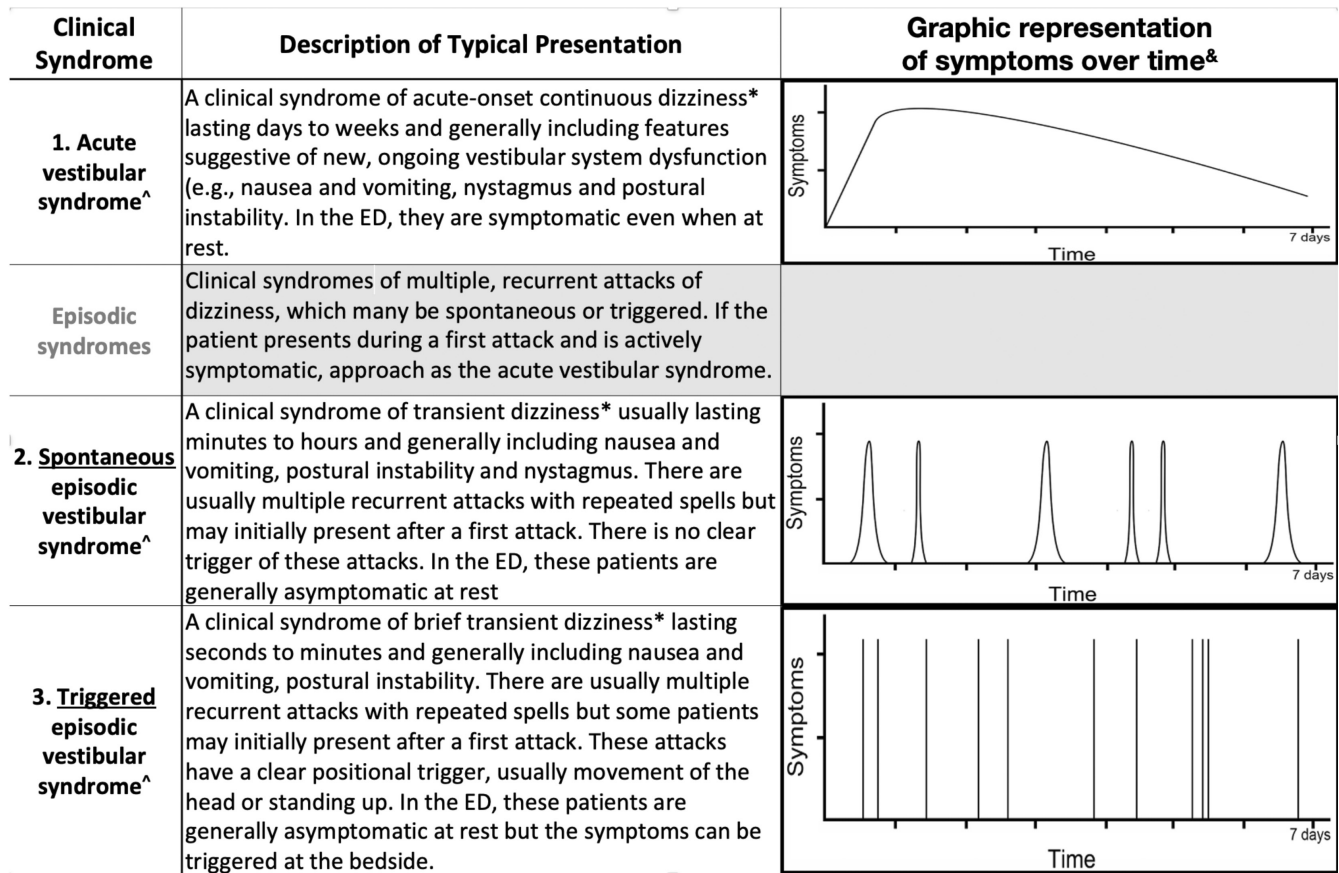


FIGURE 1 Clinical presentation patterns of patients with acute dizziness based on timing and triggers. *The word endorsed by the patient does not have etiologic significance; as above, this would include patient descriptors like vertigo and unsteadiness. [&]The number of episodes depicted in the graphic is arbitrary; there is no specific number required, but a first prolonged episode of dizziness can sometimes mimic an AVS. [^]The word “vestibular” refers to the nature of the symptom and can be due to pathology originating in either the central or the peripheral vestibular structures (and may be due to underlying medical etiologies such as orthostatic hypotension or cardiac dysrhythmias). AVS, acute vestibular syndrome.

(hc-BPPV). The preferred diagnostic maneuver is the supine roll test, and the therapeutic maneuver is either the Lempert (barbecue) roll or the Gufoni maneuver. Some emergency clinicians are appropriately trained to diagnose and treat hc-BPPV (and differentiate it from dangerous central mimics). However, because hc-BPPV is a more nuanced diagnosis, based on a majority vote, the GRACE-3 writing committee did not include it in the formal recommendations.

General note: These recommendations do not apply to dizzy patients who have obvious general medical causes for their symptoms (e.g., a cardiac dysrhythmia or medication side effect) or to dizzy patients with an obvious stroke or other central nervous system pathology (e.g., patients with hemiplegia, visual field deficit, altered mental status). For patients with general medical causes, the approach will depend on the cause and, for stroke patients, institutional stroke protocols should be followed. The three presenting syndromes outlined above are based on timing and triggers of the dizziness (see [Figures 1 and 4](#)).

INTRODUCTION

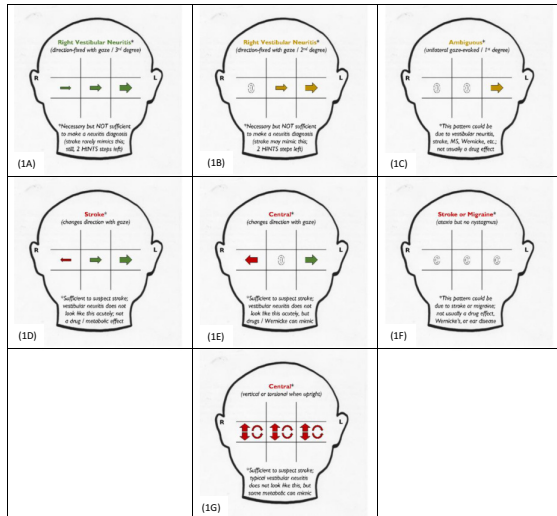
Acute dizziness or vertigo is a common emergency department (ED) presentation, accounting for 2.1%–3.6% of visits per year,^{6–10} with an

estimated annual cost approximating \$10 billion in the United States, a large proportion of which is related to imaging.¹¹ Resource use and ED length of stay for these patients are higher than in patients with other chief complaints.^{6,9} Use of neuroimaging in the ED, especially noncontrast computed tomography of the head (CT) is rising over time,^{9,12} while the proportion of diagnostically useful studies is decreasing.¹³

The traditional diagnostic paradigm, developed 50 years ago, based on symptom quality (asking the patient, “What do you mean by dizzy?”), suggests that the differential diagnosis and clinical evaluation be based on the patient's description of dizziness (vertigo, lightheadedness, imbalance or disequilibrium, or “other”).¹⁴ This paradigm was never properly validated, has significant methodological flaws, and does not reliably predict underlying causes.^{15,16} Patients often use different words to describe their vestibular symptoms. The Barany Society has developed formal international consensus criteria, terminology, and definitions for many vestibular disorders (which can be downloaded from the *Journal of Vestibular Research* website: <https://www.iospress.com/jvr-icvd>). Although some of the terminology is more detailed than most nonvestibular specialists require, the writing committee has tried to use terms that are aligned with these consensus definitions but that also make sense to front-line clinicians.

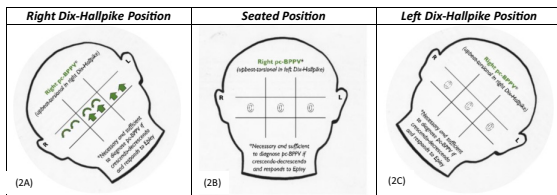
The Acute Vestibular Syndrome (AVS)

Panel 1: Nystagmus possibilities in the AVS

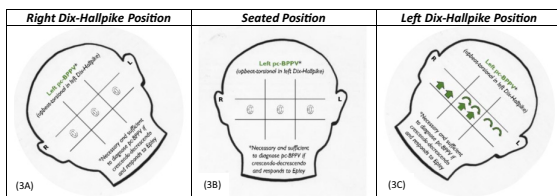


The Triggered (Positional) Episodic Vestibular Syndrome (t-EVS)

Panel 2: DIX-HALLPIKE: POSTERIOR CANAL BPPV (RIGHT EAR AFFECTED)

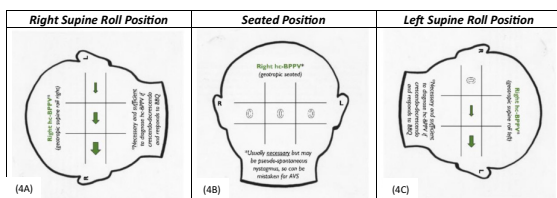


Panel 3: DIX-HALLPIKE: POSTERIOR CANAL BPPV (LEFT EAR AFFECTED)



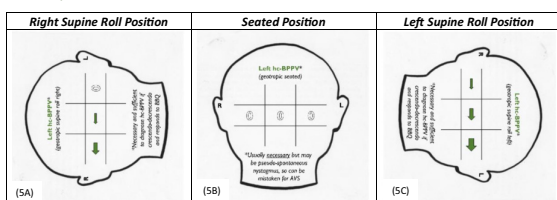
The Triggered (Positional) Episodic Vestibular Syndrome (t-EVS)

Panel 4: SUPINE ROLL: HORIZONTAL CANAL BPPV, TYPICAL "GEOTROPIC" VARIANT (RIGHT EAR AFFECTED)



The nystagmus is referred to as "geotropic" because, during the supine roll, it beats towards the floor. Note that often the only difference between right- and left ear-down positions is the relative intensity of the nystagmus. The nystagmus on the more intense side usually beats towards the affected ear.

Panel 5: SUPINE ROLL: HORIZONTAL CANAL BPPV, TYPICAL "GEOTROPIC" VARIANT (LEFT EAR AFFECTED)



The nystagmus is referred to as "geotropic" because, during the supine roll, it beats towards the floor. Note that often the only difference between right- and left ear-down positions is the relative intensity of the nystagmus. The nystagmus on the more intense side usually beats towards the affected ear.

FIGURE 2 Graphic representation of nystagmus patterns. The

crisscross lines within each "head" form nine squares that indicate the direction of the patient's gaze. The central square indicates primary gaze (looking straight ahead). The left middle square is the patient looking toward their right and the left middle square is the patient looking toward their left. The arrows indicate the direction of the fast phase of the nystagmus and their thickness corresponds to the amplitude of the nystagmus. Green color indicates a peripheral pattern, orange an ambiguous pattern, and red central. The open clear black and white circles indicate no nystagmus in that direction of gaze. The R and L on the cartoon's ears indicate the right and left sides. (Panel 1) The AVS. The "degree" of nystagmus is shown in panels 1A–1C. First degree is only present when the patient is looking in the direction of the fast phase. Second degree is present both in primary gaze and when looking in the direction of the fast phase. Third degree is present in primary gaze and also when looking both to the right and left. (1G) Nystagmus that is torsional or vertical upbeat or vertical downbeat indicates a central cause in patients with the AVS. Note that the absence of nystagmus (1F), or the presence of direction-fixed nystagmus (1A–1C) does not, by itself, exclude stroke. (Panels 2 and 3) pc-BPPV. These panels show the nystagmus of right- or left-sided pc-BPPV when performing the Dix–Hallpike test. For either side (2B and 3B), there is no nystagmus when the patient is sitting up looking straight ahead. For either side, the Dix–Hallpike will be positive on the involved side and negative on the uninvolved side. In primary gaze, the nystagmus is upbeat and torsional, but its vector changes as the patients looks to their right or left. The heads are shown at 45° to indicate that this is in the position of the Dix–Hallpike where the head is intentionally angled at 45° before being lowered off the plane of the stretcher. (Panels 4 and 5) hc-BPPV (more common "geotropic" variety). These panels show the nystagmus on performing the supine head roll test. Again, in primary gaze sitting up, there is no nystagmus (4B and 5B). They illustrate that the nystagmus will have a greater amplitude (will be more intense) with the affected ear down (toward the ground), allowing clinicians who feel comfortable treating hc-BPPV to identify the involved side. These panels show the head on its side as it will be during performance of the supine head roll test. AVS, acute vestibular syndrome; BPPV, benign paroxysmal positional vertigo; hc-BPPV, horizontal canal BPPV; t-EVS, transient episodic vestibular syndrome.

The Barany Society defines "dizziness" as the sensation of disturbed or impaired spatial orientation without a false or distorted sense of motion, "vertigo" as the sensation of self-motion (of head or body) when no self-motion is occurring or the sensation of distorted self-motion during an otherwise normal head movement, and "postural symptoms" as balance symptoms related to maintenance of postural stability, occurring only while upright (seated, standing, or walking).¹⁷

Evidence shows that patients' dizziness descriptors (e.g., "vertigo" vs. "lightheadedness" or "imbalance," "unsteadiness," and others) often change when reassessed even minutes later and that many patients simultaneously endorse multiple descriptors, undercutting the logic of a symptom quality-based paradigm.^{18,19} Accordingly, we use the general term "dizziness" to mean dizziness or

Box 1. Recommendations

Training emergency clinicians to perform bedside eye movement examinations

Recommendation 1: Emergency clinicians should receive training in bedside physical examination techniques for patients with the AVS (HINTS) and diagnostic and therapeutic maneuvers for BPPV (Dix–Hallpike test and Epley maneuver), since untrained ED physicians do not reliably apply or accurately interpret results of this bedside eye movement examination [ungraded good practice statement].

Diagnosis of the AVS

Recommendation 2: In adult ED patients with AVS with nystagmus, we recommend routine use of the three-component head impulse, nystagmus, test of skew (HINTS) examination for clinicians trained in its use* to distinguish between central (stroke) and peripheral (inner ear, usually vestibular neuritis) diagnoses (strong recommendation, **FOR**) [high certainty of evidence].

Recommendation 3: In adult ED patients with AVS with nystagmus, we suggest assessing hearing at the bedside by finger rub to identify new unilateral hearing loss as an additional criterion to aid in the identification of stroke, even if the three-component HINTS examination result suggests a peripheral vestibular diagnosis (conditional recommendation, **FOR**) [moderate certainty of evidence].

Recommendation 4: In adult ED patients with AVS without nystagmus, we suggest assessing severity of gait unsteadiness to help distinguish between central (stroke) and peripheral (inner ear, usually vestibular neuritis) diagnoses (conditional recommendation, **FOR**) [moderate certainty of evidence].

Recommendation 5: In adult ED patients with AVS with or without nystagmus, we recommend against routine use of noncontrast CT of the brain or CTA to help distinguish between central (stroke) and peripheral (inner ear, usually vestibular neuritis) diagnoses (strong recommendation, **AGAINST**; see “Implementation considerations”) [high certainty of evidence].

Recommendation 6: In adult ED patients with AVS with or without nystagmus, if a clinician trained in use of HINTS is available, we recommend against routine use of MRI of the brain or cerebral vasculature (MRA) as the first-line diagnostic test (prior to physical examination) to help distinguish between central (stroke) and peripheral (inner ear, usually vestibular neuritis) diagnoses (strong recommendation, **AGAINST**; see “Implementation considerations”) [high certainty of evidence].

Recommendation 7: In adult ED patients with AVS and central or equivocal HINTS results, we recommend use of stroke protocol MRI (with DWI and MRA) to further help distinguish between central (stroke) and peripheral (inner ear, usually vestibular neuritis) diagnoses. (strong recommendation, **FOR**; see “Implementation considerations” regarding timing of MRI) [high certainty of evidence].

Diagnosis of the s-EVS

Recommendation 8: In adult ED patients with s-EVS, the writing committee believes that routine use of a detailed history and physical examination with emphasis on cranial nerves including visual fields, eye movements, limb coordination, and gait assessment helps to distinguish between central (TIA) and peripheral (vestibular migraine, Menière disease) diagnoses [ungraded good practice statement].

Recommendation 9: In adult ED patients with s-EVS, we recommend against routine use of CT to help distinguish between central (TIA) and peripheral (vestibular migraine, Menière disease) diagnoses (strong recommendation, **AGAINST**) [moderate certainty of evidence].

Recommendation 10: In adult ED patients with s-EVS and concern for TIA, we suggest use of CTA or MRA of the head and neck to rule out posterior circulation vascular pathology (conditional recommendation, **FOR**) [moderate certainty of evidence].

Diagnosis of the t-EVS

Recommendation 11: In adult ED patients with t-EVS, we recommend routine use of the Dix–Hallpike test to diagnose pc-BPPV (strong recommendation, **FOR**) [moderate certainty of evidence].

Recommendation 12: In adult ED patients with t-EVS, we recommend against routine use of CT or CTA (strong recommendation, **AGAINST**) [moderate certainty of evidence].

Recommendation 13: In adult ED patients with t-EVS diagnosed with typical pc-BPPV by a positive Dix–Hallpike test with the characteristic nystagmus, we suggest against routine use of MRI or MRA (conditional recommendation, **AGAINST**) [moderate certainty of evidence].

Treatment of acute vestibular neuritis

Recommendation 14: In adult ED patients with a clinical diagnosis of vestibular neuritis, we suggest shared decision making with patients to weigh risks and benefits of short-term steroid treatment for those presenting within 3 days of symptom onset (conditional recommendation, **FOR**) [very low certainty of evidence].

Box 1. Continued

Treatment of pc-BPPV

Recommendation 15: In adult ED patients with pc-BPPV diagnosed by a positive Dix–Hallpike test, we recommend the Epley[†] canalith repositioning maneuver be performed at the time of diagnosis (strong recommendation, **FOR**) [moderate certainty of evidence].

[‡]As of December 2022, the specifics of training emergency clinicians in the use of these eye movement examination techniques have not been fully defined. There is no validated training course in these skills that can be widely implemented at the necessary scale. However, both anecdotal experience and evidence from published studies show that emergency physicians can learn to correctly use these techniques.^{1–3} Routine training mechanisms that lead to demonstrated proficiency should be developed and incorporated into the curriculum in medical school, emergency medicine residency programs, continuing medical education courses, and other educational vehicles. The writing committee acknowledges that until such training opportunities are routinely available, it is unrealistic to expect that all emergency clinicians will be able to acquire competency in the skills necessary to safely implement these examination techniques without expert backup (e.g., by using bedside video-oculography to verify the accuracy of bedside findings or by obtaining specialty consultation, either in person or by telemedicine).

[†]The original Epley canalith repositioning maneuver included applying a vibratory stimulus over the mastoid bone during the procedure.⁴ This aspect of the Epley maneuver does not appear to increase efficacy,⁵ so the current standard maneuver (i.e., without vibration) is technically the “modified Epley maneuver.” However, most clinicians use the term “Epley maneuver” to describe the modified maneuver, which is how we have used it in this document.

vertigo, unsteadiness, or other vestibular symptoms throughout the article except where otherwise specified (such as when referring to formal international consensus definitions or to publications that specify those words in their inclusion criteria). Accumulating evidence and expert opinion published over the past 15 years suggest that a diagnostic paradigm based on the timing and triggers of the dizziness (rather than symptom quality or descriptor) is a more diagnostically useful way to approach patients with acute dizziness.^{16,18–24} Patients are more consistent in their responses to questions about timing and triggers of their dizziness compared to their reports on type of dizziness (i.e., “What do you mean dizzy?”).¹⁹ Despite its intrinsic logic and fact that a timing and triggers approach to dizziness is the way we approach most other chief complaints,²⁰ we acknowledge that this approach has not been formally validated in an all-comer ED population.

With a timing and triggers paradigm, most acutely dizzy patients in the ED present in one of three patterns (Figure 1). These categories drive the differential diagnosis, the diagnostic testing, and the interpretation of many of these tests. International consensus definitions for three specific vestibular syndromes relevant in the ED have been incorporated into the International Classification of Vestibular Disorders and the International Classification of Diseases 11th Revision (ICD-11).¹⁷ Abridged, slightly modified definitions are provided below:

Acute vestibular syndrome

A clinical syndrome of acute-onset continuous dizziness lasting days to weeks and generally including features suggestive of new, ongoing vestibular system dysfunction (e.g., nausea and vomiting, nystagmus, and postural instability). In the ED, patients are symptomatic

even at rest, and exacerbation from head movement or position change is typical.

Spontaneous episodic vestibular syndrome

A clinical syndrome of transient dizziness usually lasting minutes to hours and generally including features suggestive of temporary, short-lived vestibular system dysfunction (e.g., nausea and vomiting, nystagmus, and postural instability) during attacks. There is usually a history of recurrent attacks but patients may initially present after or during a first attack. There are no clear triggers for these attacks, although symptoms may be exacerbated by head movement or position change during an attack. In the ED, these patients are generally asymptomatic at rest. Some patients with longer-duration episodes may have symptoms on presentation to the ED; in this situation, one would approach as an AVS and the true episodic nature may only be apparent in retrospect. Conceptually, this is no different from managing a patient presenting with focal neurological symptoms as stroke even though if the symptoms later spontaneously resolve and imaging is negative, in retrospect, one might diagnose a transient ischemic attack (TIA).

Transient episodic vestibular syndrome

A clinical syndrome of transient dizziness lasting seconds to minutes and generally including features suggestive of temporary, short-lived vestibular system dysfunction (e.g., nausea, nystagmus, and postural instability). There is usually a history of recurrent attacks but patients may initially present after a first attack. There are clear triggers for these attacks, most often movement of the head. These

include postural shifts, as when standing up or getting into bed or head motion related to turning over in bed or looking up toward a high shelf. In the ED, these patients are generally asymptomatic at rest, but symptoms can be readily provoked at the bedside by reproducing the patient's trigger.

“Isolated” dizziness

Vestibular symptoms may be characterized as “isolated” when the only associated symptoms or signs are nonlocalizing ones that routinely accompany vestibular pathology (especially malaise, nausea or vomiting, nystagmus, and postural instability). The presence of new focal neurological symptoms or signs (e.g., lateralizing weakness or numbness, dysarthria, diplopia, Horner's syndrome, or limb ataxia) accompanying the vestibular symptoms would make the syndrome “nonisolated” (as would other general medical symptoms such as chest pain or dyspnea). The presence of new hearing symptoms (e.g., tinnitus or hearing loss) in an otherwise isolated vestibular syndrome is called an isolated audiovestibular syndrome.

The differential diagnosis of dizziness is broad. Each timing and triggers category suggests a narrowed differential diagnosis (Table 1). In some patients, especially in those who present soon after symptom onset, it may not be possible to confidently place the patient into one of these three categories. The episodic nature may not yet be apparent and some patients with benign paroxysmal positional vertigo (BPPV) describe a vague but persistent dizziness or lightheadedness between episodes. Similarly, some early presenting patients with mild vestibular neuritis may have minimal symptoms at

rest but definite symptoms provoked by head motion, suggesting an episodic presentation.

Roughly half of ED patients with dizziness have various general medical conditions, 33% have otological or peripheral vestibular causes and 11% have neurological etiologies (of which a third are cerebrovascular).⁹

When seeing an acutely dizzy patient in the ED, it is important to avoid anchoring and cognitive bias.²⁵ There are numerous general medical conditions that can present with dizziness; however, emergency clinicians' typical clinical evaluation will usually identify these. Co-chief complaints such as dizziness *plus* new dyspnea, chest or abdominal pain, diarrhea, dysuria, or fever each suggest potential diagnoses. A history of a new medication might cause either side effects or drug–drug interactions resulting in dizziness. Vital sign assessment provides other clues. Fever, significant tachycardia or bradycardia, an irregular pulse, hypoxia or tachypnea, hypotension, or hypertension (with the caveat that ischemic stroke can be associated with compensatory hypertension) should always be explained and should alert clinicians to search for a general medical explanation. Physical examination findings such as dry mucous membranes, jugular venous distention, a new heart murmur, rales or wheezing, significant abdominal tenderness, or an acute rash would be clues of various general medical conditions.

In studies of ED patients with acute dizziness, only 3.2%–6% were found to have serious central causes, mostly ischemic stroke.^{6,26,27} Because peripheral causes of acute dizziness in the ED are far more common than central ones, and because many patients whose cause is a stroke are correctly diagnosed, the proportion of

TABLE 1 Differential diagnosis of acute dizziness based on the timing and triggers category^a

Vestibular syndrome	Common benign (non-life-threatening) causes	Key dangerous (potentially life-threatening) mimics	Important uncommon or less common causes
AVS (~30%)	<ul style="list-style-type: none"> Vestibular neuritis^b 	<ul style="list-style-type: none"> Posterior circulation ischemic stroke 	<ul style="list-style-type: none"> Posterior fossa hemorrhage Wernicke syndrome Labyrinthitis Multiple sclerosis Drug or medication toxicity
s-EVS (~40%)	<ul style="list-style-type: none"> Vestibular migraine 	<ul style="list-style-type: none"> Posterior circulation TIA 	<ul style="list-style-type: none"> Cardiac dysrhythmia Pulmonary embolism Panic attack Menière disease
t-EVS (~30%)	<ul style="list-style-type: none"> BPPV Orthostatic hypotension caused by non-life-threatening medical conditions 	<ul style="list-style-type: none"> Orthostatic hypotension caused by potentially life-threatening medical conditions CPPV from structural central lesions (e.g., posterior fossa mass lesion, stroke) 	<ul style="list-style-type: none"> Posterior circulation TIA due to vertebral artery compression syndrome Carotid sinus syndrome Postural orthostatic tachycardia syndrome

Abbreviations: AVS, acute vestibular syndrome; BPPV, benign paroxysmal positional vertigo; CPPV, central paroxysmal positional vertigo; s-EVS, spontaneous episodic vestibular syndrome; t-EVS, triggered episodic vestibular syndrome; TIA, transient ischemic attack.

^aThis list is not meant to be encyclopedic but rather focuses on the more common or important treatable uncommon causes of acute dizziness. The proportion of patients in each timing–trigger category refers to dizziness of presumed neurovestibular cause (i.e., not due to an obvious medical illness), which is about half of all acute dizziness.

^bVestibular neuritis is sometimes referred to as acute unilateral peripheral vestibulopathy. It is a presumed viral or postviral condition (unlike labyrinthitis, which may be bacterial).

ED patients who are discharged from the ED with a peripheral vestibular diagnosis and subsequently readmitted with an acute stroke is very low, ranging from 0.14%–0.5%.^{28–31}

However, 3.3% of the approximately 130 million ED patients (per year, in the United States) have dizziness (total $n \geq 4.3$ million).⁶ Of those, roughly 82% are discharged (total $n \geq 3.5$ million).⁶ Applying these very low proportions to this very large number suggests that ~5000–17,500 patients per year are discharged with a peripheral vestibular diagnosis then later return with a stroke, some of whom were misdiagnosed at the first visit. A recent study of medicolegal cases related to dizziness reported that of 69 cases of alleged malpractice, 50 (72.5%) occurred in the ED or primary care settings (in roughly equal proportion) related to missed or delayed diagnoses of central nervous system pathology in nearly all (92.8%).³²

Among the subset of dizzy patients with AVS, the most common causes are vestibular neuritis (also referred to as acute unilateral peripheral vestibulopathy) and posterior circulation ischemic stroke; labyrinthitis is an uncommon peripheral cause.^{33–40} Approximately 10%–25% of cases of AVS are due to stroke, the vast majority of which are ischemic.^{8,39} In a study of over 5500 ED patients with dizziness, 27% had a CT scan done and 3% had magnetic resonance imaging (MRI), presumably in an attempt to avoid missing a stroke.⁴¹ Importantly, the sensitivity of CT for early-presenting acute ischemic stroke has been shown to be as low as 10%.⁴²

This low prevalence of stroke among all-comers with acute dizziness, coupled with the very low sensitivity of CT for ischemic stroke, underscores the limited diagnostic utility of CT for patients presenting with dizziness.^{7,8,43–49} Although CT is far more sensitive for intracerebral hemorrhage (ICH), ICH is an uncommon cause of patients presenting with *isolated* dizziness.⁵⁰ In this study of 595 ICH cases, only 13 (2.2%) presented with dizziness and a NIHSS of <2. All 13 patients had focal or global neurological symptoms or signs. Viewed from the opposite perspective, a pooled analysis of 126 AVS patients reported that five (4%) had ICH as a cause but only two of them (1.6%) presented with *isolated* dizziness.³⁹ As discussed in the implementation considerations, CT may be logical if the dizziness is *not isolated* or is associated with severe headache. However, while a positive CT in that setting is useful, a negative CT should not be reassuring.

In practice, CT is used far more frequently than MRI in the ED to attempt to diagnose or exclude stroke,⁴¹ but the results are rarely helpful.^{12,43} This represents an important knowledge gap among emergency clinicians.⁵¹ Patients with dizziness diagnosed with a benign diagnosis and then discharged from the ED after a negative CT at the index visit were 2.3 times more likely to return with a stroke within 30 days compared to patients who did not have a CT, suggesting that physicians correctly risk stratified for stroke but then relied on CT (the wrong test) to exclude it.⁵² It is clear that some of these patients suffer serious morbidity and mortality from this misdiagnosis,⁵³ but the proportion of misdiagnosed patients who are harmed (due to extension of the initial stroke, developing a second stroke, or complications from posterior fossa edema) has not been systematically studied.

It is worth noting that a decision to order a CT scan (despite its low accuracy) has multiple potential influences.⁵⁴ Evidence from ED clinician surveys suggests that individuals who rely on the traditional dizziness “type” schema for diagnosis are more likely to also rely on CT to rule out stroke, reinforcing that this may partially be a knowledge gap.⁵¹ However, the decision to order neuroimaging is likely also driven by other factors such as overreliance on technology relative to bedside examination,⁵⁵ a culture of blame,⁵⁶ medicolegal fears,^{54,57} or patient preferences.^{54,58}

Although MRI is far more sensitive than CT for acute ischemic stroke,⁴² it, too, has limitations. A meta-analysis found that MRI with diffusion-weighted imaging (DWI) missed 6.8% of ischemic strokes (within the first 72 h) and MRI-DWI-negative strokes were five times more common in posterior circulation events.⁵⁹ In patients specifically presenting with an AVS, early DWI-MRI (within 48 h of symptom onset) misses 10%–22% of strokes.^{36,60–62} and 50% of small-volume posterior fossa strokes, half of which were due to large-vessel disease.⁶²

Thus, dizziness is common, and a nontrivial minority of cases are caused by ischemic stroke. Furthermore, CT (the common “go-to” test in the ED) has poor diagnostic sensitivity for ischemic stroke. Although neuroimaging has its limitations in the diagnostic evaluation of acutely dizzy patients, the bedside examination can be very helpful. In the hands of neuro-otologists, the physical examination can accurately distinguish peripheral from central causes of AVS.^{33,36,38} However, many EDs do not have access to these subspecialists, even via telemedicine. Although systematic reviews and single-institution experience report that emergency clinicians in routine practice do not use these bedside tools, use them in the wrong patients, or perform or interpret the testing incorrectly,^{63–65} accumulating evidence also shows that emergency clinicians can successfully learn and apply these techniques.^{2,3,66}

A critical message of this guideline is that a training program that demonstrates durable skill acquisition needs to be developed and disseminated at scale so that emergency clinicians can become proficient and confident in performing these bedside ocular motor tests. This curriculum will likely need to combine didactic learning with generous use of video examples and real-time observation and feedback on technique either in person or virtually. It is also possible that this could be aided by more routine use of video-oculography (VOG; see “Conclusions and research needs” section for Question 1).

Evidence also shows that emergency clinicians are not using best practices to treat patients with BPPV with bedside canalith repositioning maneuvers such as the Epley maneuver, as recommended by two different BPPV guidelines, by the American Academy of Neurology (Level A recommendation) and the American Academy of Otolaryngology–Head and Neck Surgery (strong recommendation).^{67,68} Not recognizing or properly treating these benign conditions can result in unnecessary resource utilization, falls, injuries, lost work, medication side effects, increased recurrent rate, and diminished effectiveness of delayed therapeutic maneuvers.^{67,69–76} Although less serious than missing a stroke diagnosis, the number of patients affected is far larger. Confidently diagnosing BPPV

essentially rules out a stroke, just as seeing an intrauterine pregnancy on ultrasound in a patient with first-trimester vaginal bleeding excludes an ectopic pregnancy (barring two simultaneous diagnoses in the first case and a heterotopic pregnancy in the second).

In ED patients with acute dizziness, it is the characteristics (not simply the presence or absence) of nystagmus that can be extremely helpful in making a confident diagnosis and yet studies show that emergency clinicians harbor misconceptions about how nystagmus informs the diagnostic process.^{14,56–58} Collectively, these studies show that when nystagmus is documented by front-line providers, the descriptions of the nystagmus are often inconsistent with the recorded diagnoses, suggesting that either the clinician was misinterpreting the type of nystagmus or they were misinterpreting its diagnostic significance, for example, diagnosing BPPV in a patient with spontaneous nystagmus. Furthermore, a recently completed clinical trial (AVERT NCT02483429) found nystagmus descriptions by emergency clinicians frequently did not match eye movements recorded contemporaneously in the ED by portable VOG (D.E. Newman-Toker, unpublished data). The details of nystagmus can be extremely helpful both in making a specific diagnosis of peripheral vestibular causes and in distinguishing peripheral from central ones (Table 2 and Figure 2).

Thus, use of a flawed symptom quality paradigm, knowledge gaps related to bedside diagnostic and therapeutic maneuvers, limitations of brain imaging, and inconsistent availability of MRI all contribute to non-evidence-based management.¹⁶ It is not surprising that emergency clinicians consistently select dizziness and vertigo as a high priority for a clinical decision rule for adult patients.^{77,78} It also helps explain the high misdiagnosis rate in patients with acute dizziness, with one study showing that emergency clinicians missed over a third of strokes presenting with dizziness (16 of 46 validated stroke or TIA cases were missed in the ED).²⁶ Figure 3 illustrates some of the factors related to misdiagnosis.

The objective of this guideline is to provide an evidence-based framework intended to support patients, clinicians, and other health care professionals in their decisions about the evaluation and management of adult ED patients with acute dizziness who do not have an obvious central cause with frank neurological findings or an obvious general medical one.

The important eye findings related to dizziness are dynamic. Seeing video clips of the various bedside techniques for diagnosis and treatment of acute dizziness is key to understanding them. Therefore, to maximize the impact of this guideline, the GRACE-3 committee have created a multimedia educational smartphone app

TABLE 2 Common nystagmus patterns useful for diagnosis of acutely dizzy patients.

Nystagmus pattern	Nystagmus characteristics	Common causes
<i>Peripheral vestibular</i>		
Positional	<ul style="list-style-type: none"> • Transient (lasts < 30s) upbeat-torsional nystagmus triggered by the Dix–Hallpike test • Transient (lasts < 90s) horizontal nystagmus triggered by the supine roll test and beating toward the lowermost ear (“geotropic”). In hc-BPPV, the nystagmus is seen no matter which side the head is turned 	<ul style="list-style-type: none"> • pc-BPPV • hc-BPPV
Persistent	<ul style="list-style-type: none"> • Horizontal spontaneous^a (present on primary gaze) nystagmus that is unidirectional (never changes direction with different gaze positions or positional tests [“direction-fixed”]) 	<ul style="list-style-type: none"> • Vestibular neuritis (<i>but can be seen in stroke</i>^b)
<i>Central vestibular</i>		
Positional	<ul style="list-style-type: none"> • Persistent positional downbeating vertical nystagmus • Positional horizontal nystagmus beating away from the lowermost ear [“apogeotropic”] that does not dampen over time 	<ul style="list-style-type: none"> • CPPV (<i>but can be seen in BPPV variants</i>^b) • Often due to apogeotropic hc-BPPV (<i>but is also seen in CPPV</i>)
Persistent	<ul style="list-style-type: none"> • Dominantly vertical (upbeating or downbeating) or dominantly/purely torsional spontaneous^a nystagmus • Gaze-evoked (direction changing) horizontal nystagmus (persistent left-beating nystagmus on leftward gaze and persistent right-beating nystagmus on rightward gaze)^c 	<ul style="list-style-type: none"> • Stroke, Wernicke syndrome, multiple sclerosis (or other structural central lesions), and medication side effects (e.g., anticonvulsants) or acute intoxication (e.g., alcohol)

^a“Spontaneous nystagmus” refers to nystagmus that is present on routine testing when the patient opens their eyes and looks straight ahead (also known as “primary gaze”). “Positional nystagmus” refers to nystagmus that is not present when the head is held still but is elicited on specific positional movements of the head (e.g., the Dix–Hallpike test).

^bSome findings can be seen in both peripheral and central causes. Spontaneous horizontal unidirectional (“direction-fixed”) nystagmus is typical of vestibular neuritis but can also be seen with strokes. Persistent positional nystagmus that is horizontal and beats away from the lowermost ear (“apogeotropic”) can be seen both in CPPV and with a hc-BPPV variant (cupulolithiasis). The more persistent the nystagmus, the greater the concern for CPPV.

^cPathologic gaze-evoked nystagmus must be differentiated from physiologic end-gaze nystagmus (sometimes called “end-point nystagmus”). The physiologic (normal) form is (a) present only on extreme lateral gaze, (b) of low amplitude, and (c) nonsustained (i.e., lasts just a few beats). While an occasional “normal” individual will have more prominent physiologic end-gaze nystagmus, it must generally be assumed in a patient with acute dizziness that sustained gaze-evoked nystagmus is pathologic, rather than physiologic, until proven otherwise.

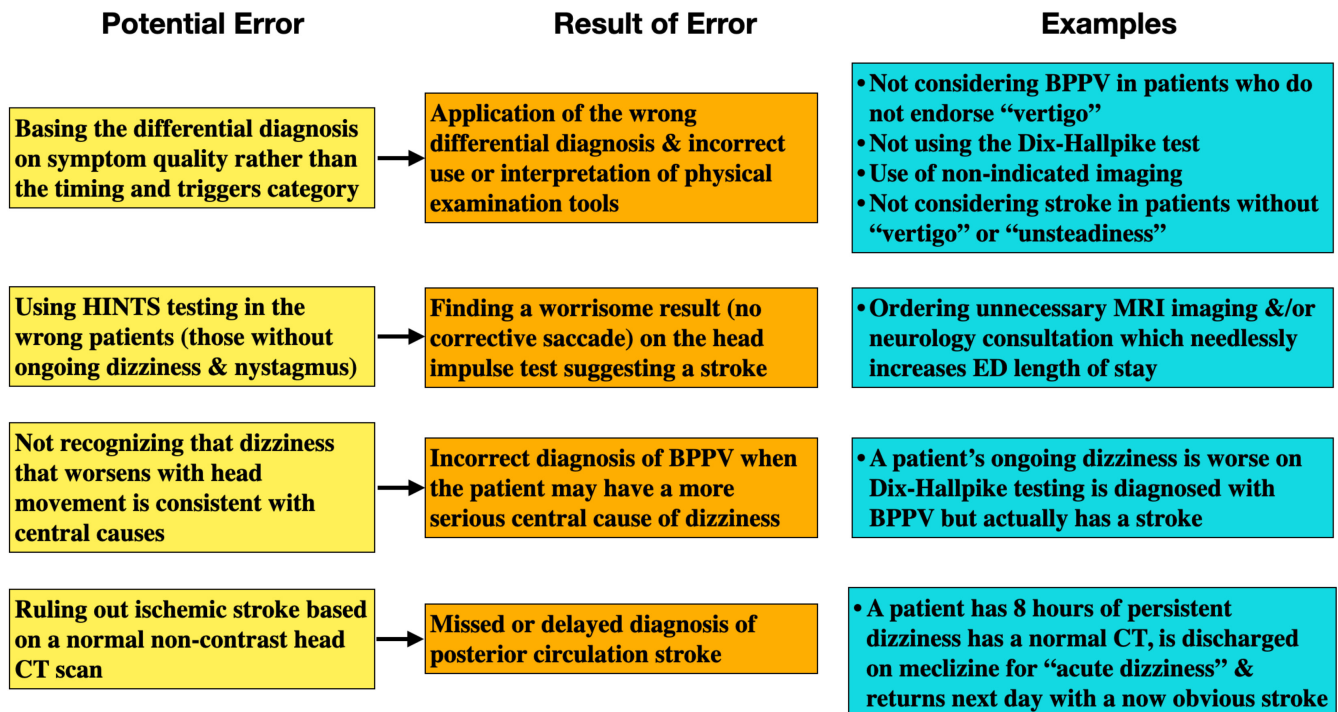


FIGURE 3 Common errors in the diagnosis of adult ED patients with acute dizziness. BPPV, benign paroxysmal positional vertigo; AVS, acute vestibular syndrome; BPPV, benign paroxysmal positional vertigo; CPPV, central paroxysmal positional vertigo; hc-BPPV, horizontal canal BPPV; s-EVS, spontaneous episodic vestibular syndrome; t-EVS, transient episodic vestibular syndrome.

that is hosted by Johns Hopkins to help close the current knowledge gaps (https://www.hopkinsmedicine.org/armstrong_institute/centers/center_for_diagnostic_excellence/resources.html).

SCOPE AND PURPOSE

The target audience includes practicing emergency clinicians (physicians and advanced nonphysician practitioners—physician assistants and nurse practitioners) responsible for the evaluation and management of adult patients presenting with acute dizziness in community and academic settings as well as health care systems and hospitals responsible for care pathways in this patient population. Since there are no current guidelines regarding the overall diagnosis and management of patients presenting with acute dizziness, the Society for Academic Emergency Medicine (SAEM) formed the Guidelines for Reasonable and Appropriate Care in the Emergency Department (GRACE-3) Writing Committee to collect and analyze the evidence for ED care of the acutely dizzy ED patient to create this guideline.

METHODS

Group composition

The GRACE-3 writing team included emergency physicians from geographically diverse sites in the United States, Canada, South America, and Europe, including those with research methodology expertise (all

of whom are also practicing clinicians) and content expertise in the diagnosis and treatment of acute dizziness as well as three patient representatives. Of the 18 members, five were female. The panel also included a board-certified neuro-otologist and an otoneurologist with advanced specialization in acute dizziness. Three patient representatives were identified who had lived experience with dizziness in the ED and who were active patient advocates. They received some orientation to the process and were active participants.⁷⁹ The SAEM supported the development of this guideline.

Group interaction and processes

From March 2021 until August 2022, the GRACE-3 writing committee met monthly using virtual conferencing. Committee members were selected based on their content expertise as well as for gender, geographical, and specialty diversity. Four subcommittees (three for the diagnostic questions [AVS, s-EVS, t-EVS] and one for the therapy questions [steroids for vestibular neuritis and the Epley maneuver for posterior canal BPPV {pc-BPPV}]) met at various intervals but no less than once per month to refine priority questions, discuss specific topics, review literature searches, and synthesize existing evidence to develop the GRACE-3 recommendations. A draft form of the document was sent out to external stakeholders including individual content experts from emergency medicine, neurology, and otolaryngology as well as relevant organizations for a 45-day review period. The writing committee evaluated the extensive comments that were received and revised the text as appropriate.

The group applied the Grading of Recommendations Assessment Development and Evaluation (GRADE) framework to assess literature identified through a systematic review process and to generate clinical recommendations.⁸⁰⁻⁸³ In brief, GRADE methodology for guideline development is a stepwise process that includes: (a) development of systematic reviews of priority questions; (b) assessment of certainty in the evidence at the outcome level by explicit consideration of the eight GRADE criteria (risk of bias, inconsistency, indirectness, imprecision, publication bias, effect size magnitude, dose response, and opposing biases and confounders); (c) development of recommendations using the GRADE evidence-to-decision (EtD) framework, which includes consideration of the certainty (quality) of evidence, the balance of benefits and potential harms, equity considerations including the values and preferences of stakeholders including patients and clinicians, resource utilization including cost and feasibility, and acceptability of recommendations to stakeholders. Recommendations are assigned direction (for, against, or either) and strength (strong or conditional/weak [the latter used interchangeably in GRADE]).⁸⁴

We used the direct costs for procedures and tests derived from Medicare data. We recognize that there are many indirect costs including the costs of training physicians/clinicians to learn new bedside evaluation and treatment techniques, time lost from work in patients with a diagnostic delay, those related to a subsequent stroke in patients who initially presented with a posterior circulation TIA, or costs related to falls and injuries due to untreated benign vestibular problems and others. However, due to the inherent difficulties in assigning specific numeric values, we used only the direct costs in our assessments of “cost-effectiveness.”

Training in GRADE methodology

The methodologists all received GRADE training, and all writing group members were encouraged to watch online video content describing the GRADE methodology and its application to GRACE-3 (<https://www.saem.org/publications/academic-emergency-medicine/grace>).

Declaration and management of competing interests

All group members disclosed conflicts of interest using SAEM's standard methods. All members were able to participate as a voting member with the following disclosures and management (see details at end of document).

Definitions of the intended patient population

The GRACE-3 writing group deliberated extensively about the population of interest for this clinical practice guideline and focused on definitions of the various acute presentations of adult ED patients with dizziness (AVS, s-EVS and t-EVS) as discussed above and depicted in Figures 1 and 4. Using these diagnostic categories is key in creating meaningful questions and in crafting the recommendations, because the evidence, the differential diagnosis, and clinical approach and the diagnostic test characteristics differ based on these presentations. Note that the use of the word “vestibular” does

Diagnostic Approach to the Acutely Dizzy Patient

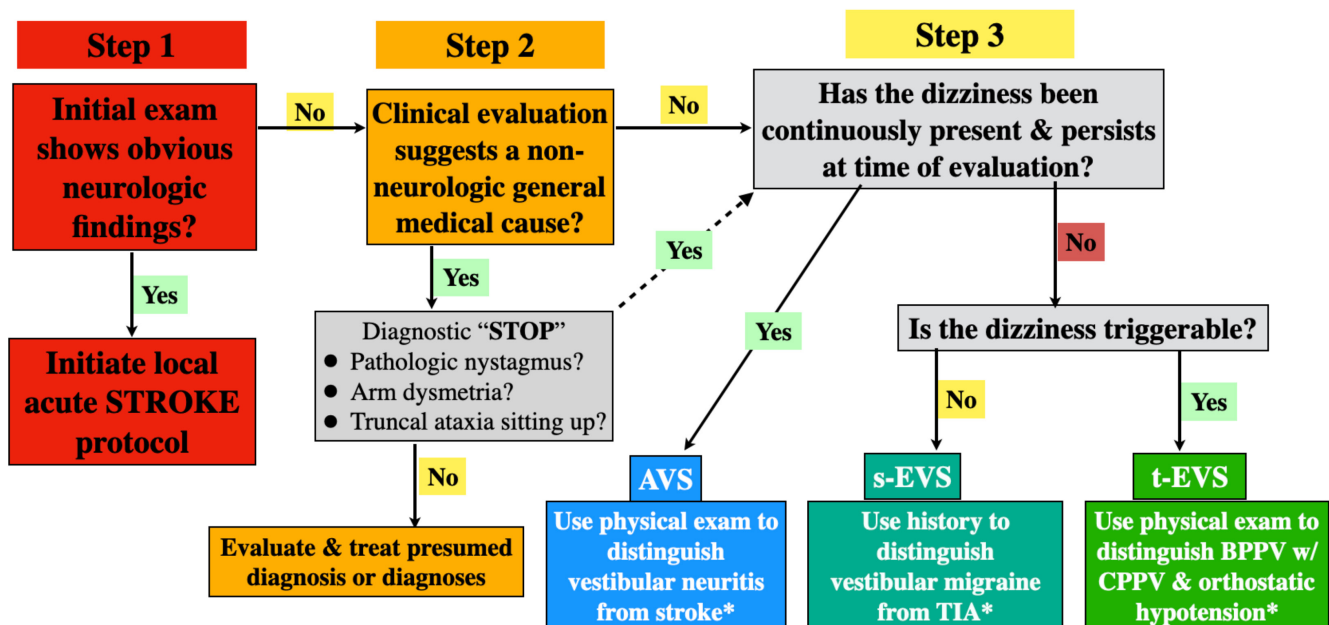


FIGURE 4 Diagnostic algorithm for approaching adult ED patients with acute dizziness. *For each vestibular syndrome, only the most important and common benign and central causes are listed. AVS, acute vestibular syndrome; BPPV, benign paroxysmal positional vertigo; CPPV, central paroxysmal positional vertigo; s-EVS, spontaneous episodic vestibular syndrome; t-EVS, transient episodic vestibular syndrome; TIA, transient ischemic attack.

not denote a peripheral cause; pathology affecting either central or peripheral vestibular structures can cause dizziness.

A diagnostic algorithm may help to conceptualize and direct the clinical approach to these patients (Figure 4). The first step is meant to rapidly identify patients whose dizziness is not isolated and who may be candidates for reperfusion or other time-sensitive treatments. Step 2 is intended to identify the roughly 50% of acutely dizzy patients with general medical causes. The final step poses questions to identify the patient's timing and triggers category (AVS, s-EVS, and t-EVS), which are the target groups around which the recommendations in this guideline are organized.

Selection of questions

The GRACE-3 writing group discussed the target population and considered the management challenges presented, while attempting to maintain the perspectives of treating clinicians, health systems, and patients. The GRACE-3 writing group generated a series of potential questions related to diagnosis, treatment, and disposition.

Because of the wide range of medical conditions that can present as acute dizziness (e.g., cardiac dysrhythmia, anemia, medication side effects, dehydration), the GRACE-3 writing group considered including these general medical causes in the search, but instead chose to focus on the subset of ED dizzy patients *without* an obvious medical or neurological cause. We specifically searched for literature that defined the three clinical syndromes previously specified, acknowledging that these distinctions are often lacking in the existing literature.

An important consideration for the GRACE-3 writing team was the feasibility of the guideline for emergency clinicians and patients in various practice settings. The GRACE-3 writing team openly discussed divergent intellectual biases among members of the group and attempted to account for them in crafting the recommendations. For example, disagreements about level of detail to include or use of jargon were resolved by group discussion followed by an open vote, with the final decision driven by the majority. The writing committee recognized that many emergency clinicians are unfamiliar with some of the diagnostic and therapeutic maneuvers that are useful in patients with acute dizziness, and therefore we included an important recommendation for clinician training. We included an algorithm to help clinicians better conceptualize the diagnostic flow of these patients. We also proposed language for emergency clinicians to use for discharge instructions (Appendix S9).

After several months of discussion, all GRACE-3 writing group members, including the patient representatives, had the opportunity to submit candidate questions and outcomes of interest, using the standard PICO (population, intervention, comparison, outcomes) format.⁸⁵ Candidate questions shared features such as patient-oriented benefits (improved diagnosis, symptom reduction, reduced radiation

risk, and cost) and impact on health system and societal resource utilization (rational use of imaging, accurate diagnosis and targeted treatment). The writing group chose to limit the questions to five based on available time and resources and prior experience from GRACE-1⁸⁶ and GRACE-2.⁸⁷ Box 2 details the final five key priority questions selected by the GRACE-3 writing group. Our questions were compound, resulting in multiple recommendations per question.

Box 2. PICO questions for GRACE-3

QUESTION 1: Should adult ED patients presenting with acute, continuous prolonged dizziness/vertigo (the acute vestibular syndrome [AVS]) undergo neuroimaging to diagnose stroke in the ED, or should they be diagnosed through bedside examination without neuroimaging? If yes to neuroimaging, what type of imaging? If no to neuroimaging, what type of bedside examination?

QUESTION 2: Should adult ED patients presenting with spontaneous episodes of dizziness/vertigo (the s-EVS) undergo neuroimaging to diagnose TIA in the ED, or should they be diagnosed through bedside examination without neuroimaging? If yes to neuroimaging, what type of imaging? If no to neuroimaging, what type of bedside examination?

QUESTION 3: Should adult ED patients presenting with triggered episodes of dizziness/vertigo (the t-EVS) undergo neuroimaging to diagnose stroke in the ED, or should they be diagnosed through bedside examination without neuroimaging? If yes to neuroimaging, what type of imaging? If no to neuroimaging, what type of bedside examination?

QUESTION 4: Should adult ED patients diagnosed with vestibular neuritis be treated with steroids?

QUESTION 5: Should adult ED patients diagnosed with pc-BPPV be treated with the Epley maneuver?

Abbreviations: AVS, acute vestibular syndrome; BPPV, benign paroxysmal positional vertigo; s-EVS, spontaneous episodic vestibular syndrome; TIA, transient ischemic attack; t-EVS, transient episodic vestibular syndrome.

Selection of outcomes of interest

Each subcommittee selected outcomes of interest from those judged to be of greatest importance by the writing group including the three patient representatives. For the three diagnostic questions, the outcomes related to accurate diagnosis. For the fourth and fifth questions on therapy, the outcomes focused on symptom relief and other markers of improvement.

Evidence synthesis and development of clinical recommendations

Systematic reviews

Each of the GRACE-3 subcommittees focused on its specific PICO questions. For the first three questions related to diagnostic accuracy, the Mayo Clinic Evidence Based Practice Center performed a comprehensive systematic review. With input from study investigators, who were physicians, medical reference librarians created and performed a comprehensive search strategy using search terms submitted by the writing group. Controlled vocabulary supplemented with keywords was used to search for neuroimaging and physical examination tests for adult ED patients with dizziness/vertigo. The databases were searched between 2000 and September 30, 2021, without any language restrictions. Databases included Ovid Medline (1946+, including Epub, ahead-of-print, in-process, and other nonindexed citations), Ovid Embase (1974+), Ovid EBM Reviews and Web of Science Core Collection (1975+), Ovid Cochrane Central Register of Controlled Trials, Ovid Cochrane Database of Systematic Reviews, and Scopus (1970+). All steps of the systematic review were done in duplicate including study selection, risk-of-bias assessment, and data extraction. Full manuscripts of the systematic review performed for this guideline are published separately.^{88,89}

For the question related to steroid use in vestibular neuritis, the GRACE-3 subcommittee performed an umbrella review (systematic review of systematic reviews).⁹⁰ Of the 149 titles retrieved, five systematic reviews were selected for quality assessment. Two were found to be of high methodological quality.^{91,92}

For the question on the use of the Epley maneuver for treatment of pc-BPPV, we performed another umbrella review. Of the 2228 abstracts reviewed in duplicate, we found 70 articles for full-text review. We sought systematic reviews of randomized controlled trials (RCTs) that evaluated the effects of Epley maneuver (intervention of interest) compared to placebo or sham procedure (comparison) in adult patients diagnosed with pc-BPPV (population). Seven systematic reviews were included in the qualitative synthesis, and one systematic review was of high methodological quality and was included in the quantitative assessment.⁹³

The full search strategies for the five PICO questions are available in Appendixes S1–S3. The individual subcommittee evidence synthesis documents were then circulated among the group in January 2022 for review and commentary.

Certainty of evidence

After synthesizing the available evidence in systematic reviews,^{88,89} certainty of evidence was assessed using GRADE.^{94,95} The GRADE methods provide a transparent approach to evaluate the certainty of evidence at the outcome level based on eight criteria including risk of bias (methodological flaws),^{96,97} inconsistency (heterogeneity across studies),^{98,99} indirectness (studies conducted in populations other than the intended ED population),^{97,100} imprecision (wide confidence intervals [CIs] resulting from underpowered studies/studies with small sample sizes), publication bias, effect size magnitude, dose–response effects, and opposing bias/confounders.^{99,101} A level of certainty in the evidence is assigned to each effect estimate evaluated (Figure 5). The GRADEpro Guideline Development Tool

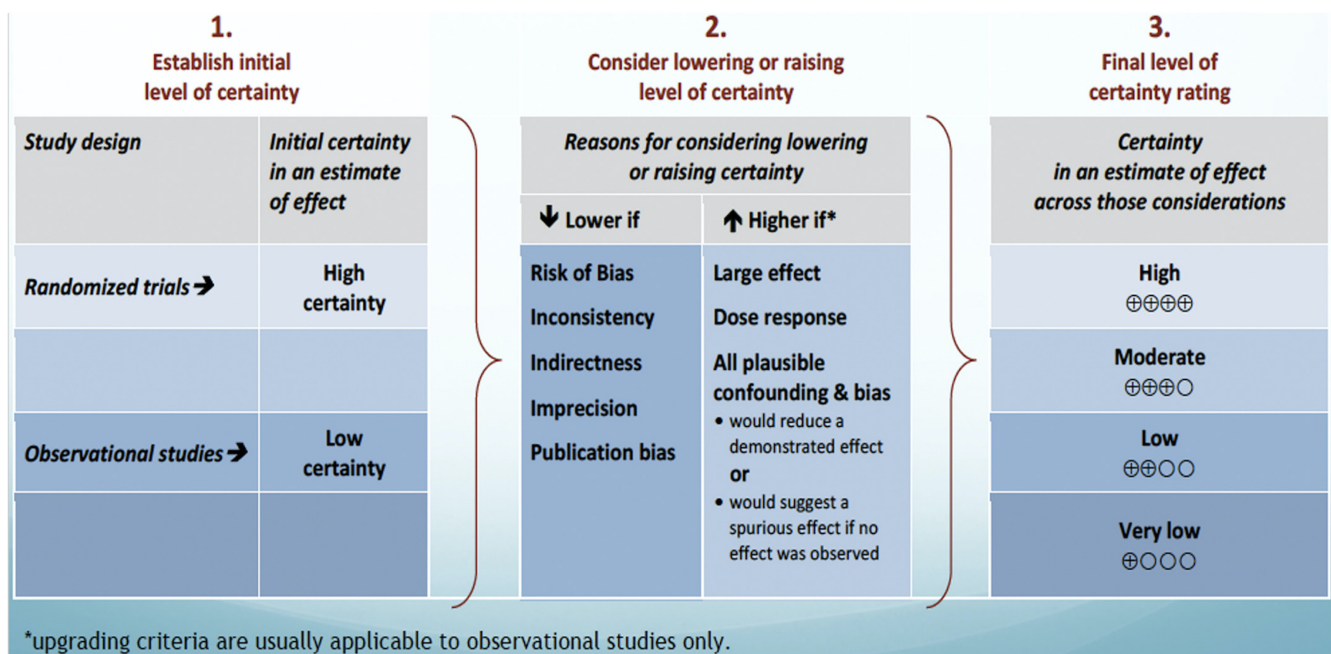


FIGURE 5 Rating the certainty in the evidence using the GRADE methodology. *Reproduced with permission by the U.S. GRADE Network.

(<https://gradepro.org/>) was used to generate summary tables and EtD frameworks. Ultimately, an overall certainty in the evidence was determined to accompany each recommendation.

EtD framework

The GRACE-3 writing group met virtually to discuss the evidence synthesis and recommendations using the GRADE EtD framework.^{80–83,102} For each PICO question, the group responsible for that question carried out extensive, structured group discussions (with input from at least one methodologist per group) of each EtD framework criteria including certainty of evidence, balance of benefits and harms (desirable and undesirable effects of the intervention, balance of effects), values, resources, acceptability, feasibility, and equity.⁸¹

Following discussion of all EtD framework criteria, the GRACE-3 writing group developed recommendations for each PICO question with a direction (for, against, or either) and a strength (strong or conditional/weak). Each recommendation also received an overall certainty of evidence level. Recommendations for which no evidence was found were assessed by indirect evidence and consensus. When applicable, we created “ungraded good practice statements” when recommending best practices related to history or physical examination as there are not studies comparing “good history/physical examination” versus “poor history/physical examination.” Good practice statements represent situations in which a large body of indirect evidence strongly supports the net benefit of the recommended action.^{103,104} Box 1 includes the recommendations of GRACE-3. The EtD sheets are available in the online appendix to this document.

Use of indirect evidence

GRADE methodology allows the use of indirect evidence.^{97,100} Lacking GRADE-specific recommendations to define “indirect evidence” or distinguish it from “direct evidence,” the GRACE-3 writing group decided a priori that “direct evidence” would match each element of the PICO question for AVS, t-EVS, and s-EVS, respectively.¹⁰⁵ If any element of the published research differed from the PICO question, that article was considered “indirect evidence.” The systematic reviews conducted to inform this guideline included studies of undifferentiated dizziness populations as well as studies that used the same categories (AVS, s-EVS, and t-EVS). Directness or indirectness of the evidence are denoted in each question. In the GRADE approach, serious concerns for indirectness downgrades the certainty in the evidence, limiting the strength of conclusions and recommendations that are drawn.^{97,100}

Indirect evidence was especially important for GRACE-3 since much of the research in acute dizziness was not done in the ED or interventions that were done in the ED were not always performed by emergency clinicians. Although indirect evidence typically leads

to downgrading of the certainty of evidence, the writing committee extensively debated how to best incorporate it. This is because some of the diagnostic maneuvers, for example, the HINTS examination and the Dix–Hallpike test, are heavily rooted in pathophysiology that is the same no matter *who* is performing these maneuvers as long as that individual is *trained in how* to perform them correctly. This impacted our recommendations including the recommendation for training. Another example relates to the sensitivity of CT for stroke in patients with the AVS, in which a substantial body of indirect evidence aligns in the same direction as the more limited direct evidence, leading to a high level of certainty of evidence for the recommendation.

Training recommendation (and online resources)

Although the writing committee did not include the issue of clinician training (in performing and interpreting these bedside diagnostic and therapeutic maneuvers) as a formal PICO question, the findings from the literature were clear and consistent that without training, emergency clinicians do not often use them properly,^{63,65,106} and that with training, their accuracy is excellent.^{2,3} Training is therefore a critical step in improving the care of ED patients with acute dizziness and we created a recommendation to address this.

Recommendation 1: Emergency clinicians should receive training in bedside physical examination techniques for patients with the AVS (HINTS) and diagnostic and therapeutic maneuvers for BPPV (Dix–Hallpike test and Epley maneuver), since untrained ED physicians do not reliably apply or accurately interpret results of this bedside eye movement examination [ungraded good practice statement].

The ACEP website (acep.org/dizzy) contains many open-access video clips that are very useful for clinicians unaccustomed to using these bedside techniques. Peter Johns also has educational videos about dizziness and vertigo on his channel (<https://www.youtube.com/c/peterjohns>). In addition, GRACE-3 committee members helped create a smartphone app on diagnosis and treatment of patients with acute dizziness that is hosted by Johns Hopkins University (https://www.hopkinsmedicine.org/armstrong_institute/centers/center_for_diagnostic_excellence/resources.html).

QUESTION 1: Should adult ED patients presenting with acute, continuous prolonged dizziness/vertigo (the AVS) undergo neuroimaging to diagnose stroke in the ED, or should they be diagnosed through bedside examination without neuroimaging? If yes to neuroimaging, what type of imaging? If no to neuroimaging, what type of bedside examination? [EtD decision frameworks are provided in Appendix S4].

Recommendation 2: In adult ED patients with AVS with nystagmus, we recommend routine use of the three-component HINTS examination for clinicians trained in its use to distinguish between central (stroke) and peripheral (inner ear, usually vestibular neuritis) diagnoses (strong recommendation, **FOR**) [high certainty of evidence].

Recommendation 3: In adult ED patients with AVS with nystagmus, we suggest assessing hearing at the bedside by finger rub to identify new unilateral hearing loss as an additional criterion to aid in the identification of stroke, even if the three-component HINTS examination result suggests a peripheral vestibular diagnosis (conditional recommendation, **FOR**) [moderate certainty of evidence].

Recommendation 4: In adult ED patients with AVS without nystagmus, we suggest assessing severity of gait unsteadiness to help distinguish between central (stroke) and peripheral (inner ear, usually vestibular neuritis) diagnoses (conditional recommendation, **FOR**) [moderate certainty of evidence].

Recommendation 5: In adult ED patients with AVS with or without nystagmus, we recommend against routine use of noncontrast CT or CTA to help distinguish between central (stroke) and peripheral (inner ear, usually vestibular neuritis) diagnoses (strong recommendation, **AGAINST**; see “Implementation considerations”) [high certainty of evidence].

Recommendation 6: In adult ED patients with AVS with or without nystagmus, in situations where a clinician trained in HINTS is available, we recommend against routine use of MRI or MRA as the first-line diagnostic test (prior to physical examination) to help distinguish between central (stroke) and peripheral (inner ear, usually vestibular neuritis) diagnoses (strong recommendation, **AGAINST**; see “Implementation considerations”) [high certainty of evidence].

Recommendation 7: In adult ED patients with AVS with nystagmus and central or equivocal HINTS results, we recommend use of stroke protocol MRI-DWI and MRA to further help distinguish between central (stroke) and peripheral (inner ear, usually vestibular neuritis) diagnoses (strong recommendation **FOR**; see “Implementation considerations” regarding timing of MRI) [high certainty of evidence].

Summary of evidence

The key differential diagnosis in AVS is between stroke (central) and vestibular neuritis (peripheral). Patients with AVS generally remain symptomatic at the time of ED assessment, so physical examination has the potential to aid diagnosis, and structural neuroimaging has the potential to “rule out” stroke. The systematic review found

direct evidence of diagnostic accuracy for both physical examination elements (general neurological examination, HINTS, and gait/limb ataxia) and neuroimaging (CT, CTA, and MRI) in the evaluation of adult ED patients with AVS.^{88,89} This evidence supports a strong recommendation for use of HINTS followed by MRI-DWI to confirm stroke when eye signs appear central and use of MRI-DWI to confirm stroke when eye findings are consistent with a peripheral cause but the patient is unable to stand independently. Emergency clinicians should also examine for the “deadly Ds”—diplopia, dysarthria, dysphagia, dysphonia, dysmetria, and dysesthesia any of which suggest a central cause for the dizziness.¹⁰⁷ Conversely, it also supports a strong recommendation for diagnosis of vestibular neuritis without neuroimaging when HINTS eye signs are all peripheral appearing, hearing loss is absent, and patients can stand unaided.

Because our PICO question did not include specific elements of the past history, we did not make a formal recommendation about identifying vascular risk factors. However, the presence of vascular risk factors increases the likelihood of a stroke in patients presenting with acute dizziness.^{61,108-111} These studies reported that various individual or combinations of vascular risk factors predicted a cerebrovascular cause of acute dizziness. Importantly, all but one¹¹⁰ used vascular risk factors *in combination* with other clinical findings of symptoms referable to the central nervous system or physical findings that localize to the central nervous system, including a central pattern of nystagmus.^{111,112}

However, although vascular risk factors are associated with stroke due to large-vessel atherosclerosis, small-vessel disease, and cardioembolism, they are often absent in patients with vertebral artery dissection. A prospective observational study of 302 patients with a spontaneous vertebral artery dissection (mean age of 42 years) found relatively low percentages of patients with hypertension (23.3%), diabetes (3.3%), current smoking (36%), past smoking (13.2%), and hypercholesterolemia (54.5%).¹¹³ Although vertebral artery dissections are an uncommon cause of acute dizziness in the ED, in a study of 1008 young stroke patients (aged 15–49), 15% were due to a cervical artery dissection.¹¹⁴ Therefore, clinicians may factor the presence of vascular risk factors (including the ABCD² score) into their decision making, but *their absence does not exclude* cerebrovascular causes of dizziness.

Direct and indirect evidence

General neurological examination

The systematic review that focused on the clinical examination⁸⁸ identified articles with data related to the general neurological examination,¹¹⁵⁻¹¹⁹ cranial nerve testing,¹²⁰⁻¹²² limb weakness,^{36,112,120,121,123,124} dysarthria assessment,^{112,121} presence of spontaneous nystagmus,^{3,119,122,125} truncal or gait ataxia,^{36,115,116,120,126-128} tandem gait assessment,^{120,126} limb ataxia,^{36,115} any cerebellar sign (unspecified dysmetria, finger to nose, heel to shin, and rapid alternating movement),^{112,120,121,126}

TABLE 3 Assessment of gait unsteadiness (adapted from Carmona et al.¹³²).

Severity of gait unsteadiness	Definition	Positive predictive value of ataxia grade for stroke ¹³¹
Grade 0	Normal	0% (n=0/5) with no unsteadiness had stroke
Grade 1	Mild to moderate imbalance with walking independently	7% (n=3/42) with Grade 1 unsteadiness had stroke
Grade 2	Severe imbalance when standing or cannot walk without support	28% (n=11/39) with Grade 2 unsteadiness had stroke
Grade 3	Falling at upright posture/inability to stand unaided	100% (n=28/28) with Grade 3 unsteadiness had stroke

and hearing loss.^{112,120,127} Nearly all of the studies were judged to have moderate to high risk of bias. For the most part, these studies reported a low sensitivity but high specificity for stroke or other central cause if the findings were present, which is expected given that if a central finding is present, the causative pathology is central.

The two studies (n=154) that recorded diagnostic test accuracy when performed by emergency clinicians (although the specific elements of the examinations performed were not described) reported sensitivities ranging from 40.0% to 72.7% and specificities 66.7% to 100%.^{117,119} Additionally, it is important to note that indirect evidence demonstrates that some patients with acute ischemic posterior circulation strokes have a NIHSS of 0.¹²⁹ A recently completed clinical trial (AVERT NCT02483429) found that, among 130 ED patients randomized with dizziness and either pathologic nystagmus or pathologic ataxia, there were 14 strokes (nine ischemic strokes, four TIAs, and one hemorrhage)—these all had NIHSS scores of 0 (minimum) to 4 (maximum), with an interquartile range of 0 to 1.¹³⁰

Spontaneous nystagmus

The presence of spontaneous nystagmus (six studies, 621 patients) had a sensitivity (for a central cause) of 52.3% (95% CI 29.8%–74.0%, moderate certainty) and specificity of 42.0% (95% CI 15.5%–74.1%, moderate certainty).^{3,119,122,124,125,131} Of the five studies that reported the specialty of the examiner, emergency clinicians performed the examinations in four (n=531). In the largest study that had a low risk of bias, in which emergency clinicians used Frenzel lenses (n=342), the sensitivity for a central cause was 45.0 and the specificity was 77.6.³ Use of Frenzel lenses is rare in emergency medicine practice. Because nearly all patients with vestibular neuritis have spontaneous nystagmus and about half of patients with cerebellar stroke do, the mere presence of spontaneous nystagmus (without further specifying its characteristics), is not helpful in distinguishing central from peripheral causes.^{22,34}

Type of nystagmus

In patients with an AVS, nystagmus that is vertical, torsional, or gaze-evoked direction-changing (i.e., right-beating on rightward

gaze and left-beating on leftward gaze) indicates a central cause. The systematic review identified 16 studies (n=1366) reporting data on the type of nystagmus.^{33,36,61,111,112,120,127,131–139} In a pooled analysis of the 16 studies, sensitivity of nystagmus type was 50.7% (95% CI 41.1%–60.2%, moderate certainty) and specificity was 98.5% (95% CI 91.7%–99.7%, moderate certainty). In a sensitivity analysis including patients with AVS (14 studies), there was similar sensitivity and specificity.

In the one study in which only emergency clinicians' examinations were reported, the sensitivity and specificity were 20.0% and 75.7%.¹²⁰ In three studies with a low risk of bias, the specificities were 97%,¹¹¹ and 100%.^{36,136} The examiners in each of these three studies were neurologists or neurology subspecialists. It is important to understand that if a central pattern (vertical, torsional or gaze-evoked direction-changing) nystagmus is found, the lesion is central, no matter what the results of the other components of the HINTS test show. Furthermore, nystagmus *in combination* with other findings, such as presence of vascular risk factors or severe gait imbalance, is highly predictive of stroke. In one study of 85 patients, all of the stroke patients had either a central pattern of nystagmus or an ABCD² score of ≥4 (the combination being 100% sensitive for stroke).¹¹¹ A larger study of 272 patients with nystagmus or imbalance reported similar findings with respect to a central pattern of nystagmus.¹¹² In a third study of 114 patients with the AVS, the combination of severe (Grade 2 or 3—see Table 3) gait instability plus a central pattern of nystagmus was also 100% sensitive for stroke.¹³²

Test of skew

Test of skew, in which the examiner uses the alternate cover test to detect vertical skew deviation, is a finding that strongly suggests a central cause of a patient's dizziness. The systematic review identified 15 studies (14 of which were restricted to an AVS presentation) that evaluated this finding.^{33,36,61,112,120,122,127,131–134,137,139–141} A pooled analysis showed a sensitivity of 23.4% (95% CI 15.0%–35.6%, moderate certainty) and a specificity of 97.6% (95% CI 96.1%–98.6%, moderate certainty).⁸⁸ The one study that reported on examinations done by emergency clinicians found a lower sensitivity (0%, 95% CI 0%–12%) but an unchanged specificity (98.6%).¹²⁰

Gait and truncal ataxia assessment

Ten studies (1810 patients) reported data on gait assessment and truncal ataxia. Increasing severity of truncal ataxia had an increasing specificity for central etiology.^{2,36,115,116,120,126–128,132,133} Pooled sensitivity was 69.7% (43.3%–87.9%, low certainty) and specificity 83.7% (52.1%–96.0%, low certainty). In the three studies that reported an emergency clinician performing the examination, the sensitivity was 74.2% (95% CI 55.9%–86.7%) and specificity was 82.2% (95% CI 57.1%–94.1%).⁸⁸ When evaluating the five studies in an AVS population, pooled estimates did not significantly differ.⁸⁸ A study of 114 patients with an AVS (judged to have moderate risk of bias because gait assessment was done by neurology residents) graded the severity of gait unsteadiness (see Table 3).¹³² They found that Grade 2 or 3 ataxia was 93% sensitive and 61% specific for stroke, while Grade 3 ataxia was 67% sensitive and 100% specific for stroke.¹³² Additional indirect evidence found that in a study of 92 consecutive patients with posterior circulation strokes, 88 (95.6%) had gait ataxia, further supporting the importance of gait assessment.¹⁴² The presence of Grade 2 or 3 ataxia, *plus* any one of the three components of HINTS being positive, had 100% sensitivity for a central cause of dizziness.

Limb ataxia

The systematic review identified four studies ($n=1135$) reporting the presence of limb ataxia findings, defined as finger-to-nose testing (two), unspecified dysmetria (one), and combination of dysmetria and/or dysdiadochokinesia (one).^{112,119,120,126} The pooled sensitivity for limb ataxia was 24.6% (95% CI 15.6%–36.5%, moderate certainty) and specificity was 97.8% (95% CI 94.4%–99.2%, moderate certainty). In the one study performed by emergency clinicians, the sensitivities/specificities for finger to nose, heel to shin and rapid alternating movements were 25%/99.5%, 0%/100%, and 0%/99.7%, respectively.¹²⁰

A more recent single-center Japanese study not included in the systematic review reported on two cohorts (one retrospective and one prospective).¹⁴³ Emergency medicine residents performed the examinations for finger-to-nose testing. The study included 357 patients (both cohorts combined) with isolated dizziness, of which 31 had a final diagnosis of a cerebrovascular cause of symptoms. Abnormal finger-to-nose testing was strongly associated with a central cause (OR 25.3, 95% CI 7.3–88.2, $p<0.001$).¹⁴³

HINTS and HINTS plus examination

The HINTS (head impulse, nystagmus, test of skew) examination is a combination of three bedside ocular motor tests (Table 4) first described in 2009. When performed by vestibular experts, the diagnostic accuracy of the HINTS examination is high (98% sensitivity and >92% specificity).^{36,38,132,136} A limitation is that some these studies

enrolled patients with at least one stroke risk factor (rather than an all-comer AVS population), which could impact the results.^{36,136} The head impulse test component should only be used in patients with ongoing dizziness who also have spontaneous nystagmus. Use in other dizzy patients results in increased and unnecessary neuroimaging. For example, if a patient with anemia as a cause had persistent dizziness without nystagmus, the clinical findings (bilaterally normal head impulse tests) would falsely suggest stroke. However, it bears repeating that if any one component of the HINTS test is consistent with a central cause, then the patient is considered to have a central cause, no matter what the results of the other components are.

Fourteen studies including 1781 patients evaluated HINTS.^{2,61,63,111,112,121,132–137,139,144} Pooled sensitivity was 92.9% (95% CI 79.1%–97.9%, high certainty) and specificity was 83.4% (95% CI 69.6%–91.7%, moderate certainty). In the 10 studies of patients with AVS, sensitivity was 93.1% (95% CI 86.2%–96.7%).⁸⁸ Two studies evaluated HINTS performed by ED providers. Dmitriew et al.⁶³ did not identify any central cases, and thus sensitivity could not be calculated; specificity was 64.3% in an AVS population and 96.4% in a mixed population. In Gerlier et al.,² emergency clinicians were provided with 4 h of individual lectures and 2 h of workshop training. Sensitivity for stroke identification was 97.9% and specificity was 64.5% in a mixed population (i.e., not restricted to AVS).

In 2013, “HINTS plus” was introduced (Table 4), which is simply the addition of a fourth examination component—bedside test of hearing by finger rub. After ensuring that the external ear canal is clear of cerumen, hearing loss was judged to be present when bedside examination (finger rubbing) detected a clear right–left asymmetry and the patient confirmed the deficit to be new.¹³⁶

New unilateral hearing loss helps identify patients with anterior inferior cerebellar artery (AICA) territory stroke, a vascular distribution that accounts for nearly all of the false-positive HINTS cases (HINTS results show a peripheral cause, but the true cause is central).¹³⁶ This occurs in two situations. The first is a stroke of the labyrinthine artery (an AICA branch), thus infarcting the peripheral structures. The second is an AICA territory stroke involving central structures (such as the lateral pons), the site where the vestibular nerve enters the brainstem. In both cases, HINTS results may falsely indicate a peripheral lesion, but the cause is a central, cerebrovascular one.

Five studies (342 patients) utilized the HINTS plus with pooled sensitivity of 99.0% (95% CI 73.6%–100%, high certainty) and specificity of 84.8% (95% CI 70.1%–93.0%, high certainty).^{116,133,134,136,137} No studies reported the HINTS plus performed by emergency clinicians.

The systematic review identified seven studies ($n=955$) evaluating hearing loss (apart from HINTS plus) and found a pooled sensitivity of 4.3% (95% CI 1.1%–15.5%, high certainty) and specificity of 95.0% (95% CI 85.2%–98.4%, high certainty).^{112,120,127,133,134,137,145} The two studies in which the hearing test was administered by emergency clinicians also found sensitivities of 97% (all AVS patients)¹²⁰ and 91.8% (vestibular syndrome unspecified).¹⁴⁵ Collectively, these findings underscore the fact that in patients presenting with

TABLE 4 Components of the HINTS and HINTS plus examinations (from Kattah et al.³⁶ and Newman-Toker et al.¹³⁶).

HINTS examination component	Usual finding ^a in vestibular neuritis	Usual finding ^a in stroke	Considerations
Head impulse test	Presence of a corrective saccade when head is rotated rapidly toward the affected side (the corrective saccade is toward the same side as the fast phase of nystagmus)	Bilateral absence of a corrective saccade	Can be falsely reassuring in patients with AICA or labyrinthine infarcts. Has only been validated in AVS patients with nystagmus.
Nystagmus testing	Unidirectional horizontal (sometimes with a slight torsional component) nystagmus, always beating to same side with gaze	Pure vertical, torsional, or direction-changing horizontal, gaze-evoked nystagmus (beats right when looking right and beats left when looking left)	Central cases can mimic the nystagmus of vestibular neuritis closely. It is especially true that cases with unilateral gaze-evoked nystagmus and none looking straight or to the other side could be peripheral or central.
Test of skew	Vertical refixation (shift in eye position) absent	Vertical refixation (shift in eye position) present	Horizontal shifts of the eyes with alternate cover testing are common in the general population and do not represent "skew" deviation. Diagonal refixation would count as a worrisome finding.
<i>HINTS plus</i>			
Hearing test by finger rub ^b	Hearing intact	New unilateral hearing loss	Helps to identify AICA or labyrinthine infarcts.

Abbreviations: AICA, anterior inferior cerebellar artery; AVS, acute vestibular syndrome.

^aNone of the component tests is 100% sensitive as a stand-alone test. The head impulse test has the highest sensitivity, but all four benign findings (direction-fixed nystagmus, unilateral corrective saccade that moves toward the same side as the fast phase of nystagmus, no skew, no hearing loss) must be present to confidently diagnose vestibular neuritis in AVS.

^bHearing testing is not part of the original three-component HINTS examination but was added later and is referred to as HINTS plus (HINTS plus) to add sensitivity for strokes.

dizziness plus acute ipsilateral hearing loss, stroke is probably more common than labyrinthitis.

It is clear that when applied in routine practice by emergency clinicians without special training, HINTS testing is inaccurate, partly due to use in the wrong patients and partly due to issues with its interpretation.^{63,146} On the other hand, emergency clinicians trained in the proper application and use of HINTS in a mixed population of ED patients with dizziness were found to have 97.9% sensitivity and 64.5% specificity for stroke with a 99.4% negative predictive value.² The training in this study was 6 h (four of lectures and two of workshop) and was repeated 7 months later. The training included not only the HINTS examination but also the maneuvers for diagnosing and treating both pc-BPPV and horizontal canal BPPV (hc-BPPV).² Another study of trained emergency clinicians found similar excellent results for components of the HINTS examination (details described below in STANDING section).³

STANDING algorithm

The systematic review identified three articles ($n=750$) that studied the STANDING algorithm (Figure 6).^{2,3,66} This algorithm was

developed in an ED population and the interventions were performed by trained emergency clinicians. The training in the original study included a 6-h workshop, 4 h of lecture, and a 2-hour demonstration on normal volunteers followed by 10 proctored examinations on ED patients. The training included some elements of the HINTS examination as well as diagnostic and therapeutic maneuvers for pc- and hc-BPPV.³ One study published subsequent to our systematic review (and thus did not contribute to our recommendations) showed that family medicine and emergency medicine interns could be trained to effectively use the STANDING algorithm with 4 h of didactic training, observation of one examination performed by the principal investigator and one proctored examination.¹⁴⁷

The STANDING algorithm deliberately skips the step of classifying the patient as AVS, s-EVS, or t-EVS and jumps straight to an algorithmic combination of nystagmus testing (including positional testing), the head impulse test (when appropriate), and gait assessment. Because our PICO questions were structured around AVS, s-EVS, and t-EVS, STANDING was not ultimately included in the final recommendations. Nevertheless, its overall structure (application of bedside diagnostic maneuvers) and logic (attempt to distinguish peripheral from central causes) make it a practical algorithm. The four-step STANDING protocol is more inclusive than HINTS in that

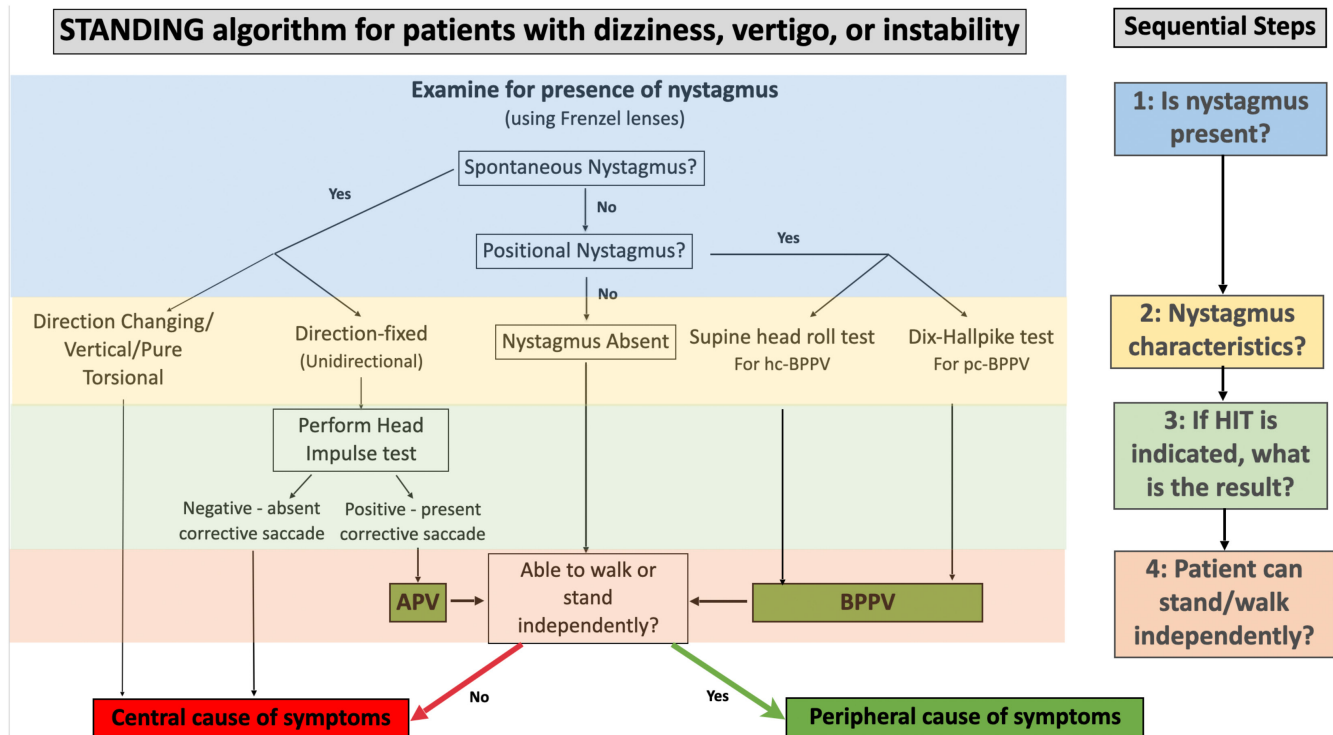


FIGURE 6 STANDING Algorithm. APV, acute peripheral vestibulopathy (usually vestibular neuritis); BPPV, benign paroxysmal positional vertigo; hc-BPPV, horizontal canal BPPV; HIT, head impulse test; pc-BPPV, posterior canal BPPV. Figure 6 is adapted from Vanni et al.^{3,149}

positional nystagmus testing is part of the initial assessment of nystagmus so its use is not restricted to patients with an AVS.

The STANDING protocol may be especially useful in patients whose histories are vague making it difficult to place them neatly into one of the timing and triggers categories. Clinicians would not normally perform a Dix-Hallpike test in patients with a clear-cut AVS nor the HINTS examination in patients with a clear-cut t-EVS. However, very early in the course of BPPV, some patients describe lingering interictal symptoms probably due to longer lasting nausea or anxiety about moving the head normally, superficially mimicking an AVS. In such patients, assuming there is no spontaneous or direction-changing gaze-evoked nystagmus, it is reasonable to perform the Dix-Hallpike test.¹⁴⁸ In this situation, it is important to strictly interpret the Dix-Hallpike test results—a positive being the reproduction of symptoms *plus* transient, crescendo–decrescendo, upbeat–torsional nystagmus with torsion toward the affected ear on one side only. Similarly, some patients with mild vestibular neuritis may be minimally symptomatic at rest but become symptomatic with head movements, superficially mimicking a t-EVS.

These are situations in which the STANDING protocol might clarify the diagnosis despite an ambiguous history with respect to timing and triggers. Furthermore, the STANDING protocol has been internally³ and externally² validated. The protocol is a focused physical examination aimed at differentiating central from peripheral causes of dizziness (and specifically making the diagnosis of pc- and hc-BPPV) in four steps. Step 1 (blue in Figure 6) is to define the presence or absence of nystagmus and Step 2 (yellow) is to assess the characteristics of the nystagmus. Step 3 (green) is to perform the

head impulse test in those patients with spontaneous direction-fixed nystagmus. The final step (orange) is to assess gait unsteadiness.¹⁴⁹ The sensitivity for identifying a central cause of the dizziness (mostly strokes) ranged from 93.4% to 100% and the specificities from 71.8% to 94.3%.^{2,3,149} Note that the STANDING protocol does not include the test of skew (part of HINTS) or test of hearing (part of HINTS plus). The average time needed for emergency physicians to perform the STANDING protocol is less than 3 min.¹⁵⁰

CT scan

Because of its availability, speed for time-sensitive decisions and familiarity, CT is commonly used in the ED as the initial neuroimaging modality for patients with neurologic presentations. The systematic review identified six studies (771 patients) reporting on CT sensitivity in adult ED patients with acute dizziness.^{44,118,124,145,151,152} None of these studies specified vestibular syndromes but rather reported on a mix of ED patients with acute vertigo or dizziness. The reference standard used was MRI in four studies and clinical follow-up in the other two. Three studies evaluated the outcome of stroke, with sensitivity ranging from 6.7% to 75.0% and specificity ranging from 77.3% to 99.0%.⁸⁹ Three studies evaluated the outcome of all central causes, with sensitivity ranging from 21.4% to 43.4% and specificity ranging from 90% to 100%. In the meta-analysis, pooled sensitivity was 28.5% (95% CI 14.4%–48.5%), with specificity of 98.9% (95% CI 93.4%–99.8%), positive likelihood ratio (LR) of 26.2 (95% CI 5.6–123.4), and negative LR of 0.72 (95% CI 0.58–0.91).⁸⁹ Sensitivity

analysis of the four studies that used MRI as the reference standard had similar sensitivity and specificity. Not all the studies systematically obtained both CT and MRI in all patients with dizziness to search for strokes; MRIs as the reference standard in some studies were obtained because of clinical suspicion of stroke. This necessarily biases results toward larger, more obvious strokes and favors CT sensitivity. Thus, the pooled estimate of sensitivity for CT here is almost certainly a ceiling, rather than a floor estimate.

The systematic reviewers graded the pooled estimates of sensitivity and specificity for CT to have moderate level of certainty due to concerns for risk of bias. However, there was a large body of concordant direct and indirect evidence all showing that CT is very inaccurate in identifying posterior circulation ischemic strokes among patients with AVS. Therefore, after vigorous debate, the guideline panel's judgment of certainty of evidence for CT being an inaccurate test in this situation was deemed as high. In patients with AVS, if we apply the average pretest probability of stroke at 25%,³⁹ a negative CT will only decrease the posttest probability to 19.4%, which is far above the threshold that emergency clinicians have indicated as acceptable when "ruling out" stroke among patients presenting with acute dizziness (<0.5% posttest probability of stroke).¹⁵³ Table 5 illustrates the impact of different clinical and imaging diagnostic modalities on the posttest probability of stroke among adult ED patients with the AVS and shows poor performance of CT, better performance of elements of the neurological examination and gait, very good performance of MRI, and excellent test characteristics of the STANDING and HINTS plus examination.

Early CT is less sensitive than later CT to diagnose acute ischemic stroke. In a study of 356 consecutive ED patients with possible stroke, CT had an overall sensitivity of 15% (95% CI 12%–23%).⁴² Importantly, this study included all strokes, so likely the majority of strokes detected were larger anterior circulation infarcts which would be expected to be more visible on brain imaging. In ED patients with posterior circulation infarct, CT sensitivity for infarction, compared to MRI, ranged from 10% to 41%.^{45,46} In the study reporting 41%, the average time from symptom onset to imaging was 12h.⁴⁵ Only patients who underwent MRI were eligible for the study (thus identifying patients with more severe disease). This spectrum bias would therefore overestimate the sensitivity of CT.¹⁵⁴

Studies analyzing the diagnostic yield of CT in ED patients presenting with dizziness or vertigo have reported that finding a causative brain lesions ranged from <1% to 7%.^{43,47,48} The study with the 7% finding was a small study ($n=72$) and although the patients were seen in an ED, all of those scanned had been seen by a neurologist, suggesting a skewed population.⁴⁸ In the largest study ($n=1681$) clinicians decided to CT 810 of them, of whom six (0.74%) had clinically relevant findings.⁴³ All six had nonisolated dizziness. Over time, the diagnostic yield of CT in ED patients with dizziness is decreasing due to rising rates of CT with stable rates of pathology detectable in the broader ED dizzy population and is associated with longer ED length of stays.¹² An important adverse effect of a CT is the false reassurance of a negative study.^{16,52}

Furthermore, although CT is an excellent test for acute ICH, ICH rarely presents with isolated dizziness. In one study of 595 patients

with ICH, only 13 (2.2%) had dizziness as the primary chief complaint and a NIHSS of <3.⁵⁰ All 13 patients had some other neurological finding on examination.

CTA

Our systematic review identified a single retrospective study of 153 patients with undifferentiated dizziness, in whom the attending physician decided (for unspecified reasons) to perform a head and neck CTA. The CTA showed findings in five patients but only two of them (2/153, 1.3%) had findings that were causing their dizziness.⁴⁴ Indirect evidence of CTA is consistent with this finding. In a study of 228 patients (ED and outpatient) with acute dizziness who had a CTA, only three (1.3%) found a lesion that changed management.¹⁵⁵ In addition to providing false reassurance, other costs of CTA include radiation exposure with associated cancer risk, contrast-associated anaphylactoid reactions and nephropathy, and financial costs. However, if the clinician believes the patient has a central cause (based on physical examination findings), then a CTA may help define a vascular mechanism.

MRI scanning

The systematic review identified five studies of MRI ($n=943$).^{36,137,152,156} One study was in patients with AVS, one in patients with AVS symptoms that had resolved within 24h, and three studies in undifferentiated dizziness. The reference standard was delayed MRI in three studies and follow-up diagnosis in two. Pooled sensitivity was 79.8% (95% CI 71.4%–86.2%), specificity 98.8% (95% CI 96.2%–100%), and negative LR 0.20 (95% CI 0.14–0.30). There were no false-positive examinations. Certainty in the sensitivity and specificity estimates was high.⁸⁹

This is consistent with other data showing that small posterior circulation infarcts are five times more likely to be DWI-MRI negative than those in the anterior circulation.⁵⁹ In patients presenting with an AVS, compared to the criterion standard of delayed MRI beyond 72h from symptom onset, early MRI sensitivity for stroke presenting with acute dizziness is roughly 80%–90%.^{36,60,62,156} This is also consistent with the data showing that DWI-MRI is time dependent for strokes in any arterial distribution⁴² and specifically in the posterior circulation.¹⁵⁷ Taken together, these data show that MRI scanning, when done within 48 hours of symptom onset, is less accurate than the HINTS examination, when performed by either a vestibular specialist or a trained emergency physician.

Benefits

If HINTS testing were used by appropriately trained emergency clinicians, accurate diagnosis and treatment would be faster and both less dependent on and more accurate than emergent imaging.

TABLE 5 Pretest and posttest probabilities of stroke using different tests in adult ED patients with AVS.

Pretest probability of stroke in different scenarios	Posttest probability of stroke following a negative test		
	Lower bound of 95% CI of NLR	Pooled point estimate of NLR	Upper bound of 95% CI of NLR
CT (sensitivity 28.5; specificity 98.9%) ⁸⁹ NLR 0.72 (95% CI 0.58–0.91)			
10% (low)	6.1%	7.4%	9.2%
25% (average) (38)	16.2%	19.4%	23.3%
50% (high)	36.7%	41.9%	47.6%
General neurological examination (sensitivity 46.8%; specificity 92.8%) ⁸⁸ NLR 0.57 (95% CI 0.45–0.73)			
10% (low)	4.8%	6%	7.5%
25% (average) (38)	13%	16%	19.6%
50% (high)	31%	36.3%	42.2%
Assessment of truncal/gait ataxia (sensitivity 69.7%; specificity 83.7%) ⁸⁸ NLR 0.36 (95% CI 0.20–0.67)			
10% (low)	2.2%	3.8%	6.9%
25% (average) (38)	6.3%	10.7%	18.3%
50% (high)	16.7%	26.5%	40.1%
MRI (sensitivity 79.8%; specificity 98.8%) ⁸⁹ NLR 0.20 (95% CI 0.14–0.30)			
10% (low)	1.5%	2.2%	3.2%
25% (average) (38)	4.5%	6.3%	9.1%
50% (high)	12.3%	16.7%	23.1%
HINTS battery (sensitivity 92.9%; specificity 83.4%) ⁸⁸ NLR 0.08 (95% CI 0.03–0.27)			
10% (low)	0.3%	0.9%	2.9%
25% (average) (38)	1%	2.6%	8.3%
50% (high)	2.9%	7.4%	21.3%
STANDING algorithm (sensitivity 95%; specificity 87%) ³ NLR 0.06 (95% CI 0.01–0.22)			
10% (low)	0.1%	0.7%	2.4%
25% (average) (38)	0.3%	2%	6.8%
50% (high)	1%	5.7%	18%
HINTS plus battery (sensitivity 99%; specificity 84.8%) ⁸⁸ NLR 0.01 (95% CI 0–0.40)			
10% (low)	Noncalculable	0.1%	4.3%
25% (average) (38)	Noncalculable	0.3%	11.8%
50% (high)	Noncalculable	1%	28.6%

Note: Estimates of diagnostic accuracy were extracted from published systematic reviews.^{3,88,89} Cells highlighted in light green fall below the 0.5% threshold identified by emergency physicians to rule out stroke.¹⁵³

Abbreviations: MRI-DWI, magnetic resonance imaging (with diffusion-weighted imaging); NLR, negative likelihood ratio.

Furthermore, more widespread use of HINTS testing would eliminate many very low-value CT scans as well as some MRI scans in patients diagnosed with a peripheral cause. The potential benefits of accurate and timely diagnosis of posterior circulation stroke in patients with an AVS include more reperfusion treatment (if indicated), rapid initiation of secondary prevention measures, finding and

treating the underlying vascular lesion, and monitoring and treating complications from posterior fossa edema.

Patients with ischemic posterior circulation minor strokes may be at higher risk of a subsequent stroke than those with anterior circulation strokes,¹⁵⁸ in part due to the incidence of vertebral artery stenosis.^{159,160} Regarding reperfusion with intravenous alteplase,

there are fewer data specific to patients with posterior circulation strokes compared to those with anterior circulation strokes; in the third International Stroke Trial (IST-3), only 246 of 3035 (8.1%) had posterior circulation strokes and the proportion of those presenting with dizziness or isolated dizziness was not reported.¹⁶¹ Two studies that analyzed intravenous thrombolysis in posterior circulation strokes both found similar outcomes to strokes of the anterior circulation, but neither reported the proportion of patients presenting with an AVS.^{162,163} A recent study of thrombolytic therapy that compared vascular territories also demonstrated that overall neurologic outcomes were similar, but also showed that the risk of brain hemorrhage in posterior circulation stroke was half that in anterior circulation stroke.¹⁶⁴

Although many patients with minor strokes presenting with the AVS will not be candidates for thrombolysis, nearly all are candidates for antiplatelet treatment with either aspirin monotherapy for low-risk patients (usually defined as ABCD² score <4) or with dual antiplatelet therapy (DAPT), usually with aspirin plus clopidogrel for high-risk patients (usually defined as ABCD² score ≥4). Because of the increased risk of hemorrhage in patients treated with DAPT, the clopidogrel should be prescribed for more than 21 days.¹⁶⁵ A pooled analysis of 10,051 patients comparing with clopidogrel plus aspirin to aspirin alone found that DAPT had a reduced risk of major ischemic events at 90 days compared to aspirin monotherapy (hazard ratio 0.70; 95% CI 0.61–0.81, $p < 0.001$).¹⁶⁵ Although both of the pooled studies excluded TIA patients with isolated dizziness, other studies clearly show that episodes of isolated dizziness occur within the 90 days prior to posterior circulation stroke in 8% (23/275 patients)¹⁶⁶ and 12% (55/447) patients.¹⁶⁷ Therefore, DAPT may apply those high-risk patients whose qualifying symptom is isolated dizziness. Use of DAPT in patients with high-risk TIA or minor stroke has been incorporated into recent American Heart Association and the European Stroke Organization recommendations.^{168,169}

Early diagnosis can lead to more rapid identification of the stroke mechanism allowing for earlier intervention when appropriate, for example, a vertebral dissection or stenosis or a cardioembolic source of clot. Anticoagulation is recommended for patients with atrial fibrillation.¹⁷⁰ For patients with vertebral artery dissection, two treatment trials reported conflicting data regarding the relative therapeutic benefit of antiplatelet agents versus full anticoagulation.^{171,172} There are few data about medical versus interventional treatment for vertebral artery atherosclerotic stenosis.

Finally, early diagnosis will lead to earlier initiation of monitoring for complications of posterior fossa edema, which tends to peak in the days following a cerebellar stroke.¹⁷³ Some of these patients will need ventriculostomy for acute hydrocephalus or suboccipital craniectomy for posterior fossa edema causing brainstem compression or near herniation.¹⁷⁴

Harms and burden

Missing posterior circulation strokes in patients with an AVS has potential adverse outcomes that are the converse of the benefits mentioned in the last paragraph and also include the ability to more quickly manage complications of cerebellar strokes such as cerebral edema.¹⁷³ The current diagnostic tools available each have unique harms in addition to cost and increasing ED length of stay. CT involves ionizing radiation; for CTA, contrast administration.^{175,176} MRI can cause anxiety and claustrophobia and is often unavailable.¹⁷⁷ The general neurologic examination is not accurate enough to satisfy emergency clinicians' desire for sensitivity for a serious diagnosis.¹⁵³

Without training, inaccuracy of the HINTS examination can increase risk of misdiagnosis. This last point is not trivial. The ideal program for training front-line clinicians how and when to perform HINTS testing and how to interpret the results is not yet developed and will require time and effort to implement at scale. Such a program would include didactic content including generous use of video examples but also hands-on experience with performing these bedside ocular motor tests (as well as positional maneuvers for diagnosis and treatment of BPPV). The frequency with which this training module would need to be repeated (if any) is not defined.

Decision criteria and additional considerations

The writing committee felt that the data for the HINTS examination were robust but with the important caveat that most clinicians will need to undergo training for how and when to perform it and how to interpret the results. Current evidence shows that there is a significant knowledge gap^{63,65} but also that this gap can be closed with training.^{2,3} A number of issues about training need to be addressed. Who will provide it? At what level(s) of the trainees' experience should the training occur? Will medical schools, emergency medicine residency programs or credentialing organizations embrace it? How much will it cost and who will pay for it? These issues remain to be fully defined.

Equity in health care delivery

As the training issues are resolved, implementation of HINTS by emergency clinicians should improve equity for patients with the AVS because emergency clinicians will be able to more accurately diagnose a peripheral cause, usually vestibular neuritis, with a bedside examination, thereby making expensive and often unavailable neuroimaging unnecessary. More accurate early diagnosis may also reduce some hospitalizations.

Conclusions and research needs

The HINTS examination is the most appropriate, accurate, and probably cost-effective tool for appropriately trained emergency clinicians in the assessment of patients with an AVS. Ultimately, cost-effectiveness will depend on the balance between cost of training and the resources saved by its use. It is clear that emergency clinicians can learn to use these techniques effectively.^{2,3} These two studies inform how much training has worked but more research is needed to define ideal training methods that confer proficiency, duration, quality assurance, and need for periodic updates. Future studies should also investigate the minimum examination necessary for distinction between central and peripheral causes of dizziness, including direct comparisons of the STANDING protocol to the HINTS examination and evaluation of HINTS components combined with other clinical elements such as vascular risk factor profile, gait assessment, or others.

The role for VOG is another fertile area for research. Current VOG devices are similar to a pair of swimming goggles with embedded sensors, which record the eye movements of the HINTS examination as well as in positional maneuvers for patients with a t-EVS. The recordings can be interpreted by a remote specialist or a computer. Use of VOG not only helps with diagnosis but also can facilitate and enhance clinician education, calibration (does the VOG confirm what the clinician thought they saw?), and quality assurance (similar to a point-of-care ultrasound image later reviewed by the ultrasound director).¹⁷⁸ Although routine ED use of VOG may seem far off, it was not that long ago that cardiologists routinely overread all electrocardiograms performed in the ED, a skill that is now firmly within the scope of emergency medicine. Early feasibility studies of VOG in the ED show promise^{61,179-182} and could become standard over time.

We used the gait assessment scale from an international study of 114 AVS patients.¹³² There are other tools that are sometimes used but the writing committee is unaware of comparative studies and felt that this scale was the most pragmatic and intuitive for emergency clinicians to use. Future studies may elucidate the most accurate gait assessment.

QUESTION 2: Should adult ED patients presenting with spontaneous episodes of dizziness/vertigo (the s-EVS) undergo neuroimaging to diagnose stroke or TIA in the ED, or should they be diagnosed through bedside examination without neuroimaging? If yes to neuroimaging, what type of imaging? If no to neuroimaging, what type of bedside examination?

[EtD frameworks are provided in Appendix S5].

Recommendation 8: In adult ED patients with s-EVS, emergency clinicians should perform a history and physical examination with emphasis on cranial nerves including visual fields, eye movements, limb coordination, and gait assessment to help distinguish between central (TIA) and peripheral (vestibular migraine, Menière disease) diagnoses [ungraded good practice statement]

Recommendation 9: In adult ED patients with s-EVS, we recommend against routine use of CT to help distinguish between central (TIA), benign central (vestibular migraine), and peripheral (Menière disease) diagnoses (strong recommendation, **AGAINST**) [moderate certainty of evidence]

Recommendation 10: In adult ED patients with s-EVS and concern for TIA, we suggest use of CTA or MRA to rule out posterior circulation vascular pathology (conditional recommendation, **FOR**) [moderate certainty of evidence].

Summary of evidence

The key differential diagnosis in s-EVS is between TIA (central) and vestibular migraine (benign central) or Menière disease (peripheral). Over the past 15 years, the definition of a TIA has shifted from a time-based (i.e., patients whose symptoms resolve in less than 24 h) to a tissue-based (i.e., patients with a transient episodes of neurological dysfunction “without acute infarction” by imaging) definition.¹⁸³ Since MRI is not usually done in the ED in the first hours of care, we will use the familiar term TIA but readers should understand the important concept that true ischemic TIA (without infarction) and minor stroke with transient symptoms are simply different manifestations of the same cerebrovascular disease process.

Patients with s-EVS are asymptomatic between episodes. In patients with vestibular migraine, 24% reported a duration of episodes between 4 h and 3 days.¹⁸⁴ If a patient is symptomatic on arrival, then one would proceed as if the patient has an AVS. This is no different conceptually from patients with focal neurological deficits being managed as an acute stroke, even though later spontaneous symptom resolution (and negative imaging) would make TIA the correct diagnosis *in retrospect*.

Patients with a s-EVS who are asymptomatic at the time of presentation cannot, by definition, have their symptoms triggered/reproduced at the bedside. Therefore, neither physical examination nor structural neuroimaging are likely to be as helpful compared to patients with AVS or t-EVS. Clinically, diagnosis usually relies largely on careful history-taking and risk assessment for the diagnoses of TIA and vestibular migraine. The systematic reviews found limited direct evidence of diagnostic accuracy for some history elements and some neuroimaging (MRI) in the evaluation of adult ED patients with s-EVS.^{88,89} Additional indirect evidence was identified to help support the final guideline recommendations.

Direct evidence suggests that routine neuroimaging in unselected s-EVS patients is unlikely to prove cost-effective. However, the aggregated evidence supports as a good clinical practice recommendation for use of focused history-taking to identify suspected TIAs when episodes of dizziness are not isolated, occur over a shorter period of time (<6 months), lack reassuring features (e.g., clear migraine features like photophobia), or are associated with vascular

risk factors. Common symptoms that suggest TIA are sometimes collectively known as the deadly Ds (diplopia, dysarthria, dysphagia, dysphonia, dysmetria, and dysesthesia).¹⁰⁷ Conversely, episodes suggest a diagnosis of vestibular migraine or Menière disease (without the need for neuroimaging) when symptoms meet international specialty consensus diagnostic criteria (see Box 3).^{185,186} These consensus criteria ensure that symptoms are recurrent and frequently accompanied by specific symptom patterns that are unusual among patients with TIA (e.g., presence of clear migraine headache features with more than half of the isolated vestibular spells). Overall, brief episodes of isolated dizziness are less likely to be a TIA compared to other causes; in fact, the Canadian TIA study found that isolated dizziness made a TIA diagnosis less likely.¹⁸⁷

Direct and indirect evidence

Direct evidence found two recent studies reporting the percentages of s-EVS to be 32.1% ($n=136/424$) in one study⁶¹ and 16.6% ($n=101/610$) in the other¹¹⁸ among ED patients presenting with vertigo or dizziness. Nham et al.⁶¹ was a prospective observational study of a convenience sample of 539 ED patients with dizziness. A structured history was taken to capture whether the episode of vertigo was first ever; its duration; its spontaneous or positional nature; the presence of aural (tinnitus, fullness or hearing loss), migrainous (headache, visual aura, photo- or phonophobia), or neurological (diplopia, dysarthria, or numbness) symptoms; and the presence of vascular risk factors.⁶¹ Of the 136 patients with a s-EVS, any migraine-related symptom correlated with a diagnosis of vestibular migraine (OR 39.7, 95% CI 3.2–490.8) compared to Menière disease and conversely, the presence of unilateral auditory symptoms increased the likelihood of Menière disease (OR 140.3, 95% CI 9.8–2015).⁶¹ Interestingly, in this study, TIA was very rare in the s-EVS group, but accounted for half (16/32) of patients who had a single episode of transient (lasted < 24 h) dizziness. Machner et al.¹¹⁸ included 610 patients who presented with vertigo, dizziness, and imbalance (101 with an s-EVS) and evaluated the diagnostic test accuracy of general neurological examination compared to the criterion standard of DWI-MRI. In this study, on multivariate analysis, transient symptoms were associated with a reduced likelihood of a central cause (OR 0.3, 95% CI 0.1–0.6).

Although neither vestibular migraine nor Menière disease are diagnoses that emergency clinicians need to make in the ED, clinicians should be aware of vestibular migraine, as it is the most common cause of the s-EVS.¹⁸⁸ Because the duration of vestibular migraine is variable,¹⁸⁴ some patients will present while still symptomatic but without nystagmus. In those patients, the approach will be the same as that for the AVS and the diagnosis is only made in retrospect.⁶¹ However, 90% of the vestibular migraine patients in that same study had a prior history of migraine; in the other 10%, headache followed a first episode of dizziness. In patients with isolated dizziness, knowledge of vestibular migraine and its diagnostic criteria opens the door to identifying these patients and referring them for

specialist outpatient care (Box 3). Awareness of vestibular migraine not only facilitates better outpatient care but may also reduce subsequent ED visits, overall resource utilization, and patient anxiety.

Box 3. Diagnostic criteria for vestibular migraine (adapted from Lempert et al.¹⁸⁵)

Vestibular migraine

- A At least five episodes with vestibular symptoms of moderate or severe intensity, lasting 5 min to 72 h.
- B Current or previous history of migraine with or without aura according to the International Classification of Headache Disorders (ICHD-3).
- C One or more migraine features with at least 50% of the vestibular episodes:

Headache with at least two of the following characteristics:

- one sided location,
- pulsating quality,
- moderate or severe pain intensity,
- aggravation by routine physical activity

Photophobia and phonophobia,

Visual aura

- D Not better accounted for by another vestibular or ICHD diagnosis.

Probable vestibular migraine

- A At least five episodes with vestibular symptoms of moderate or severe intensity, lasting 5 min to 72 h.
- B Only one of the Criteria B and C for vestibular migraine is fulfilled (migraine history or migraine features during the episode).
- C Not better accounted for by another vestibular or ICHD diagnosis.

The most serious cause of the s-EVS is posterior circulation TIA and minor stroke with transient symptoms, although ischemia is an uncommon cause in ED patients presenting with transient episodes of dizziness. One retrospective cohort study of ED patients with dizziness reported a TIA diagnosis in just 1% (9/907) of patients.²⁷ Another population-based study of 1666 adult ED patients with dizziness found that of patients with isolated dizziness, 0.7% were diagnosed with stroke or TIA (the breakdown of the two diagnoses was not reported for isolated dizziness, although the overall cohort had 3.2% attributed to stroke and the ratio of strokes to TIAs was about 2:1).²⁶ The systematic review identified two studies that addressed posterior circulation TIA in patients with a single episode of dizziness that lasted less than 24 h.^{61,116} One convenience sample study of ED patients found that half (16/32) of such patients with a single episode of dizziness that had resolved were diagnosed with a TIA.⁶¹ The other study reported that of 63 such patients, 11 (17%) had strokes and nine (14%) had

cerebellar TIA.¹¹⁶ The fact that they were unable to make any diagnosis in the other 43 (68%) patients, even after neurologic consultation, conventional and perfusion MRI, underscores the degree of diagnostic difficulty in this group.

Regarding posterior circulation TIA, most evidence was indirect, often in studies that combined TIA and minor ischemic stroke (again, different parts of the spectrum of acute cerebrovascular disease). Patients presenting to the ED with acute neurological symptoms should undergo a careful neurological physical examination, but it is a normal examination that supports a TIA diagnosis.¹⁸⁹⁻¹⁹¹ In two different studies comparing emergency physician TIA diagnosis with the "criterion standard" of neurologist final diagnosis, between 36% and 44% of cases, the diagnoses were discordant.^{192,193} However, this criterion standard is problematic because another study that compared TIA diagnosis from actual ED cases by three fellowship trained vascular neurologists found considerable discrepancies among the three subjects.¹⁹⁴

Dizziness is the most common symptom of posterior circulation ischemia,^{195,196} and isolated dizziness is the most common antecedent TIA symptom leading up to a posterior circulation infarction.¹⁶⁶ In one case series of 407 adult patients, 47% reported dizziness.¹⁹⁶ The ABCD² score is less sensitive for posterior circulation TIA compared to anterior events, which is expected since the "C" in ABCD² relates to hemispheric symptoms.¹⁹⁷⁻¹⁹⁹ Because the "A" is for age > 60 years, the ABCD² is also lower in most patients with vertebral dissections, who had a mean age of 42 years in one study ($n=302$)¹¹³ and 46.5 in another systematic review ($n=1972$).²⁰⁰ These patients often lack traditional vascular risk factors. In fact, the ABCD² score's sensitivity overall was lower for patients less than 60 years of age in one study.¹³⁶ Furthermore, posterior circulation TIAs tend to be very short,^{167,201} further lowering the score (the "D" in ABCD²), although one large study reported that half of these events presenting as isolated vertigo lasted longer than 60 minutes.¹⁶⁶ Although as a general rule, the duration of TIA is shorter than vestibular migraine, there is considerable overlap.

In a prospective population incidence study of 1141 acute ischemic stroke patients, isolated episodes of dizziness within the 48 h prior to the stroke were described in 9% of the 275 patients with posterior circulation stroke, compared to less than 1% with anterior circulation stroke (OR 35.8, 95% CI 8-153).¹⁶⁶ In another prospective

multicenter study of 447 patients with posterior circulation stroke, brief transient vestibular symptoms were reported in 12% of the patients in the 30 days prior to the stroke.¹⁶⁷

On the other hand, two other studies showed that the presence of isolated episodes of dizziness or vertigo tracked with emergency clinician *misdiagnosis* of TIA (compared to the criterion standard of the neurologists' diagnosis).^{192,193} This disconnect is likely due to the fact that other causes of episodic dizziness such as vestibular migraine and BPPV are so much more common than TIA that the "noise" (of migraine and BPPV) drowns out the "signal" (of central causes). Two expert reviews suggest that multiple episodes of isolated dizziness occurring over more than 3 weeks²⁰² or over 6 months²⁰³ are rarely due to posterior circulation TIA. In one retrospective review of 339 patients referred to an outpatient stroke clinic, subjects who had fewer than five episodes of vertigo per week were more likely to receive a diagnosis of definite or probable cerebrovascular cause.²⁰⁴ With the important caveat that no single clinical factor can perfectly distinguish vestibular migraine from TIA, Table 6 offers some guidance.

In a systematic review of stroke outcomes following posterior versus anterior TIA, in the population-based studies identified, the risk of stroke was higher in patients with posterior events (OR 1.48, 95% CI 1.1-2.0).¹⁵⁸ The proportion of patients who presented with isolated dizziness was not reported. Therefore, identifying these patients is important. We do not recommend using the ABCD² score in isolation because it is inaccurate in predicting acute outcomes in individual TIA patients in general^{205,206} and to identify those due to posterior circulation ischemia in particular.¹⁹⁷⁻¹⁹⁹ Despite these limitations of the ABCD² score, it is often used to dichotomize TIA patients into "low risk" (ABCD² < 4) and "high risk" (ABCD² ≥ 4) to drive choice of antiplatelet therapy. These caveats notwithstanding, it is still important to consider risk factors for and symptoms of vertebral artery dissection, especially in younger patients.

Neuroimaging

Due to the evolution in the definition of TIA,¹⁸³ assessing diagnostic accuracy of neuroimaging for TIA is terminologically complicated and methodologically problematic. Using these modern definitions

TABLE 6 Factors that may help distinguish vestibular migraine from posterior circulation TIA.

Clinical factor	Vestibular migraine	TIA
Age	Younger	Older
Duration	Longer (usually >1 h)	Shorter (usually <1 h)
Onset	May be sudden or gradual	Usually sudden
Prior migraine history	Very common	Less common
Multiple attacks	Common and occurring over a longer period of time	Less likely (usually over a shorter period of time if they occur)
Vascular risk factors	Fewer	More
Concurrent headache	Very common	Much less common ^a

Abbreviation: TIA, transient ischemic attack.

^aNeck pain may accompany vertebral dissection causing a TIA.

of TIA and minor stroke, it is not possible to “confirm” TIA using neuroimaging but only to confirm “minor stroke in a patient with transient neurological symptoms” or “suspected TIA in a patient with a high-risk vascular lesion on imaging.” Nevertheless, it is still possible to draw reasonable inferences based on the low prevalence (pretest probability) of TIA among those with isolated dizziness combined with the low sensitivity of CT for completed stroke in the posterior fossa. We examined evidence for three types of brain imaging—CT, MRI, and CTA. The relative frequencies of vestibular migraine and posterior circulation TIA make indiscriminate imaging very unlikely to be cost-effective.

CT scan

CT is insensitive for TIA in general, with one study of 322 patients reporting that in 1.2% of patients a nonvascular cause was found (e.g., a subdural hematoma), and in 4%, an infarct was seen.²⁰⁷ One would expect lower sensitivities for posterior circulation TIA given the intrinsic limitations of bony artifact and smaller lesion size. The data about CT sensitivity for patients with dizziness in general (described in Question 1) showing poor sensitivity even in patients with ongoing dizziness combined with empiric evidence²⁰⁷ adds to the certainty that CT is unlikely to be useful to diagnose stroke among patients with the s-EVS.

MRI

The studies assessing MRI in the systematic review did not relate to TIA but to stroke. To some extent, this distinction is artificial since the two exist on the same spectrum of acute ischemic cerebrovascular events. However, since some studies labeled patients with negative DWI MRI as “TIA” rather than “stroke,” sensitivity of MRI for posterior circulation TIA presenting as an s-EVS could not be calculated. It is reasonable to perform MRI when a clinical diagnosis of TIA is suspected, in search of either a minor stroke or a high-risk vascular lesion. The AHA recommends MRI as the “preferred” imaging modality for patients with TIA.¹⁸³ However, it would not be cost-effective to use MRI to indiscriminately search for minor stroke in all s-EVS cases.

Vascular imaging

Our systematic review sought studies evaluating cerebrovascular imaging using ultrasound, CT, CTA, and MRA.⁸⁹ The three studies ($n=258$) that evaluated ultrasound were all related to stroke not TIA. The reference standard was MRI.^{133,145,208} The sensitivities for ultrasound ranged from 30% to 53.6% and specificity 94.9%–100% suggesting that ultrasound *in isolation* should not be relied upon to diagnose a large-vessel mechanism for a TIA.⁸⁹

The single study identified by our systematic review of CTA in an “all-comer” ED population of 153 patients with isolated dizziness found a very low diagnostic yield for causative posterior circulation large vessel pathology (2/153, or 1.3%).⁴⁴ Indirect evidence also showed a retrospective study of 228 ED patients with acute dizziness whose attending physician chose to perform a CTA; only five (2.2%) had findings that changed clinical management.¹⁵⁵ Because the study evaluated a skewed population (of patients selected to have CTA), the number of positive CTA in TIA patients would be expected to be much lower. The systematic review of neuroimaging did not find any studies directly related to s-EVS.⁸⁹

It is important to realize, however, that among TIA patients, large-vessel disease is an important factor leading to a subsequent acute stroke. Both CTA and MRA are very sensitive in identifying vertebral artery stenosis >50% and both are better than ultrasound.²⁰⁹ Furthermore, a large prospective study showed that in 359 patients with posterior circulation minor stroke or TIA, the presence of a vertebrobasilar stenosis (diagnosed mostly by MRA and some by CTA) significantly increased the risk of a second stroke (OR 4.2, 95% CI 2.1–8.6).²¹⁰

Benefits

There are two major benefits to accurate diagnosis in patients with the s-EVS. Correct diagnosis and treatment of TIA can reduce the short-term outcome of stroke by 80% (an important patient-centered and societally relevant outcome),^{211,212} which is durable at 5 years after index TIA.²¹³ Starting an antiplatelet agent is an important secondary prevention strategy.²¹⁴ In addition, improved awareness and diagnosis of vestibular migraine by emergency clinicians as an extremely common cause of the s-EVS will facilitate outpatient follow-up with an appropriate specialist, initiation of treatment and better patient education about their condition. The included studies did not directly address these benefits.

Harms and burden

The major harm of missing a TIA is that, untreated, 5% of TIA patients have a stroke in the days following the TIA,²¹⁵ and some data suggest that short-term stroke risk is higher in patients with posterior circulation TIA.¹⁵⁸ Potential harms of missed vestibular migraine diagnosis include more ED visits for persistent symptoms, falls, and injuries.^{216,217} CT is associated with economic (cost), health (radiation exposure), and logistical (longer ED length of stay) harms without adding much value.^{12,41,43,48} Our patient representatives highly valued accurate diagnosis (even for non-TIA diagnoses) based on preventable recurrence, ED visits, and earlier initiation of treatment. They initially expressed reassurance by having a CT scan; however, when educated about the lack of utility of CT, they changed to the opinion that CT was not a valuable test.

Decision criteria and additional considerations

Consideration of local resources and economic realities may affect the pattern of follow-up. Although patients should be referred back to their primary care physician, some of these providers may not be aware of diagnoses such as vestibular migraine and referral to a specialist (neurologist, ENT, or neuro-otologist/oto-neurologist) may be valuable for some patients. Shared decision making can only be properly done when the important, patient-relevant information is shared with the patient.²¹⁸ This is particularly important when there is equipoise or uncertainty. In a situation where a path of action or intervention is clear, the discussion would be very different. Clinicians should understand the lack of utility of CT scans in this setting.

Conclusions and research needs

There is a dearth of direct evidence about the emergency clinician awareness and diagnosis of vestibular migraine. Improved awareness should help to get the patient the correct follow-up faster. Emergency clinicians' history taking should target features that help to distinguish migraine (multiple episodes over longer time and a history of migraine) or Menière disease (multiple episodes over a longer time with hearing loss) with TIA (fewer episodes but sometimes with associated deadly Ds symptoms—diplopia, dysarthria, dysphagia, dysphonia, dysmetria, and dysesthesia occurring over a shorter time period). Regarding posterior circulation TIA, better prospective studies of ED patients presenting with the s-EVS may help with identification of those with TIA. Once a TIA diagnosis is made, the management can largely be extrapolated from the management of TIA in general.

QUESTION 3: Should adult ED patients presenting with triggered episodes of dizziness/vertigo (the t-EVS) undergo neuroimaging to exclude stroke in the ED, or should they be diagnosed through bedside examination without neuroimaging? If yes to neuroimaging, what type of imaging? If no to neuroimaging, what type of bedside examination?

[EtD frameworks in provided in Appendix S6].

Recommendation 11: In adult ED patients with t-EVS, we recommend routine use of the Dix–Hallpike test to diagnose pc-BPPV (strong recommendation, **FOR**) [moderate certainty of evidence].

Recommendation 12: In adult ED patients with t-EVS, we recommend against routine use of CT or CTA (strong recommendation, **AGAINST**) [moderate certainty of evidence].

Recommendation 13: In adult ED patients with t-EVS diagnosed with typical pc-BPPV by a positive Dix–Hallpike test with the characteristic nystagmus, we suggest against routine use of MRI or MRA (conditional recommendation, **AGAINST**) [moderate certainty of evidence].

Summary of evidence

The key differential diagnosis in t-EVS is between the relatively rare central paroxysmal positional vertigo (CPPV) and the very common BPPV (peripheral). Patients with t-EVS are usually asymptomatic at rest in the ED but, by definition, their symptoms can be triggered/reproduced at the bedside with positional testing. Thus, physical examination has the potential to make a confident specific diagnosis. The systematic review found evidence of diagnostic accuracy for the physical examination (Dix–Hallpike test) in the evaluation of adult ED patients with t-EVS, but not every study identified in the systematic review met every criterion in the PICO question. Additional indirect evidence was identified to help support the final guideline recommendations. Aggregated evidence supports a strong recommendation for use of the Dix–Hallpike test to diagnose pc-BPPV when the triggered and transient upbeat torsional nystagmus is seen. Conversely, it supports a conditional recommendation for use of MRI in cases with atypical nystagmus or lack of response to canalith repositioning treatments, although other variants of BPPV are also diagnostic possibilities.

While orthostatic hypotension is also a cause of t-EVS and has both dangerous and benign causes, emergency clinicians are quite familiar with diagnosis of orthostatic hypotension. BPPV can sometimes be mistaken for orthostatic hypotension, since some patients with BPPV complain of lightheadedness on arising.²¹⁹ However, careful history-taking readily separates those with BPPV, since symptoms in BPPV usually also occur on reclining or when rolling over in bed.²²⁰ Similarly, episodes that occur during sleep strongly suggest the diagnosis of BPPV.^{220,221} Furthermore, patients with orthostatic hypotension rarely have nystagmus on positional testing unless the hypotension is profound.²²²

Direct and indirect evidence

Our systematic review identified four studies of moderate to high risk of bias.^{118,121,122,125,223} In one study all patients with a central etiology had a negative Dix–Hallpike test.²²³ One study of patients with an unclear type of dizziness that required hospital admission to a neurology floor had two patients with atypical nystagmus on Dix–Hallpike testing that had a central cause. This study excluded an unknown number of BPPV patients discharged home after successful treatment in the ED.¹¹⁸

Of critical importance, however, is that three of these studies^{118,121,223} reported that among dizzy ED patients with a central etiology, 100% of them had a negative Dix–Hallpike test. However, in clinical practice, a *positive* Dix–Hallpike test is used to rule in pc-BPPV as opposed to a *negative* test ruling in a central cause. The Dix–Hallpike test is considered the criterion standard diagnostic test for pc-BPPV,^{67,68,224} so the test's sensitivity for pc-BPPV cannot properly be assessed (i.e., incorporation bias renders a 100%).¹⁵⁴ Routine use of the Dix–Hallpike test by emergency clinicians is very low,^{70,71,75,106} and incorrect interpretation

of nystagmus findings is common.^{181,225} It is important to note that the Dix–Hallpike test is the preferred test for pc-BPPV and not for other types of BPPV; however, some patients with hc-BPPV will have horizontal nystagmus with Dix–Hallpike testing.¹⁴⁸ Nystagmus on Dix–Hallpike testing can also be negative in patients with hc-BPPV and in patients with so-called “subjective” BPPV (i.e., positional vestibular symptoms without nystagmus). Experimental evidence suggests that since visual fixation can partially suppress nystagmus, apparently “subjective” BPPV will be more common if special goggles (Frenzel lenses or VOG) are not used to block visual fixation.^{226,227}

Indirect evidence shows that emergency clinicians can successfully use the Dix–Hallpike test to diagnose pc-BPPV,^{2,3,71,149,228–230} resulting in decreased imaging, hospitalization and total costs of care,²³⁰ excellent diagnostic accuracy,^{2,3,149} and increased physician satisfaction with the process of care.²³¹ Given the frequency of BPPV, the minimal time required to perform the Dix–Hallpike test, and the resultant improved efficiency of care, the writing committee members, including the patient representatives, felt that emergency clinician adoption of the Dix–Hallpike test was important to improve patient-centered outcomes (Figure 7).

For this strategy to work, once again, effective training of a large number of clinicians about when and how to perform the Dix–Hallpike test and how to interpret the results is required. When performed in the correct patients (t-EVS without spontaneous or gaze-evoked nystagmus) a unilaterally positive Dix–Hallpike test, with the characteristic triggered, transient upbeat–torsional nystagmus beating toward the lowermost ear is the criterion standard for diagnosing pc-BPPV.^{67,68}

CT scan

The evidence for the diagnostic accuracy and utility of CT is mostly related to patients with an AVS or all suspected neurovestibular dizziness, not a t-EVS population, per se. CT scans are used frequently in ED patients eventually diagnosed as BPPV.²⁴ Overall, the diagnostic yield of CT for important structural causes in dizzy patients is very low.^{12,44,47,155} In one study of patients with an unclear type of dizziness that required hospital admission to a neurology floor, none of the 10 CT scans obtained clinically in those with typical BPPV nystagmus revealed clinically important findings; in contrast, two of 34 scans obtained in those with atypical or no nystagmus had acute brain lesions (not further described for these particular patients).¹¹⁸ The most recent BPPV-specific otolaryngology guideline also recommends against routine imaging in the presence of typical nystagmus and adequate therapeutic response to repositioning treatments.⁶⁷

MRI scan

We did not find any direct evidence relating to this question in ED populations and, as above, imaging in typical BPPV cases is not

recommended.^{67,68} However, there may be clinical clues in patients with a t-EVS that suggest a central mimic of BPPV (i.e., CPPV), in which cases MRI with gadolinium would be the preferred follow-up test (over CT). These clues include atypical nystagmus, especially persistent downbeating or apogeotropic-type horizontal nystagmus, any other central nervous system findings on examination, or lack of response to canalith repositioning maneuvers.^{118,233–235} Clinicians who are familiar with anterior canal BPPV (who have transient downbeating nystagmus) and patients with the apogeotropic variant of hc-BPPV (who have transient apogeotropic horizontal nystagmus) may treat with the appropriate therapeutic maneuver, but a lack of response would be worrisome. This underscores the importance of a careful history and neurological examination as well as supporting attempting a canalith repositioning maneuver, since a successful “therapeutic” maneuver helps to clinch the diagnosis.

Many of the causes of CPPV are not acute emergencies. A single retrospective study ordered follow-up MRI on 500 patients with a diagnosis of typical pc-BPPV and who were treated with canalith repositioning maneuvers.²³⁶ The MRIs were performed after the index visit for the BPPV. Two canalith repositioning maneuvers were successful in curing 98.2% (491/500) of the patients. Only three of 500 (0.6%) required an immediate referral to specialists as a result of their (delayed) MRI. Thus, the consensus of our group of experts was that MRI is unnecessary in patients with t-EVS with a classic BPPV presentation and Dix–Hallpike test findings who respond to canalith repositioning maneuver treatments.

Benefits

The Dix–Hallpike test is a simple and rapid maneuver to diagnose pc-BPPV in patients with the t-EVS. Evidence shows that the Dix–Hallpike test can be utilized appropriately in the ED to correctly diagnose BPPV.^{2,3,71,149,230} There is evidence from the ED to suggest that imaging (particularly CT) is overutilized in BPPV,⁴⁷ despite the fact that CT is generally unhelpful in ED dizziness. In addition to more rapid diagnosis, the Dix–Hallpike test, when positive, avoids unnecessary imaging, resulting in a large cost savings,^{10,230} a reduction in unnecessary radiation exposure, and a reduction in ED length of stay.

Harms and burden

There are few documented harms to performing the Dix–Hallpike test in patients with t-EVS. Theoretically, instability of the cervical spine or atherosclerotic disease of the vertebrobasilar system could lead to complications when performing the Dix–Hallpike test.⁶⁷ Practically speaking, this risk is negligible. More germane would be the risk of improperly interpreting the results of the Dix–Hallpike test and ascribing a benign cause (i.e., pc-BPPV) to a patient with a serious one (i.e., CPPV). The main burden is the time, effort, and cost required for *training* emergency clinicians in proper use, application, and interpretation of the Dix–Hallpike test. This is also

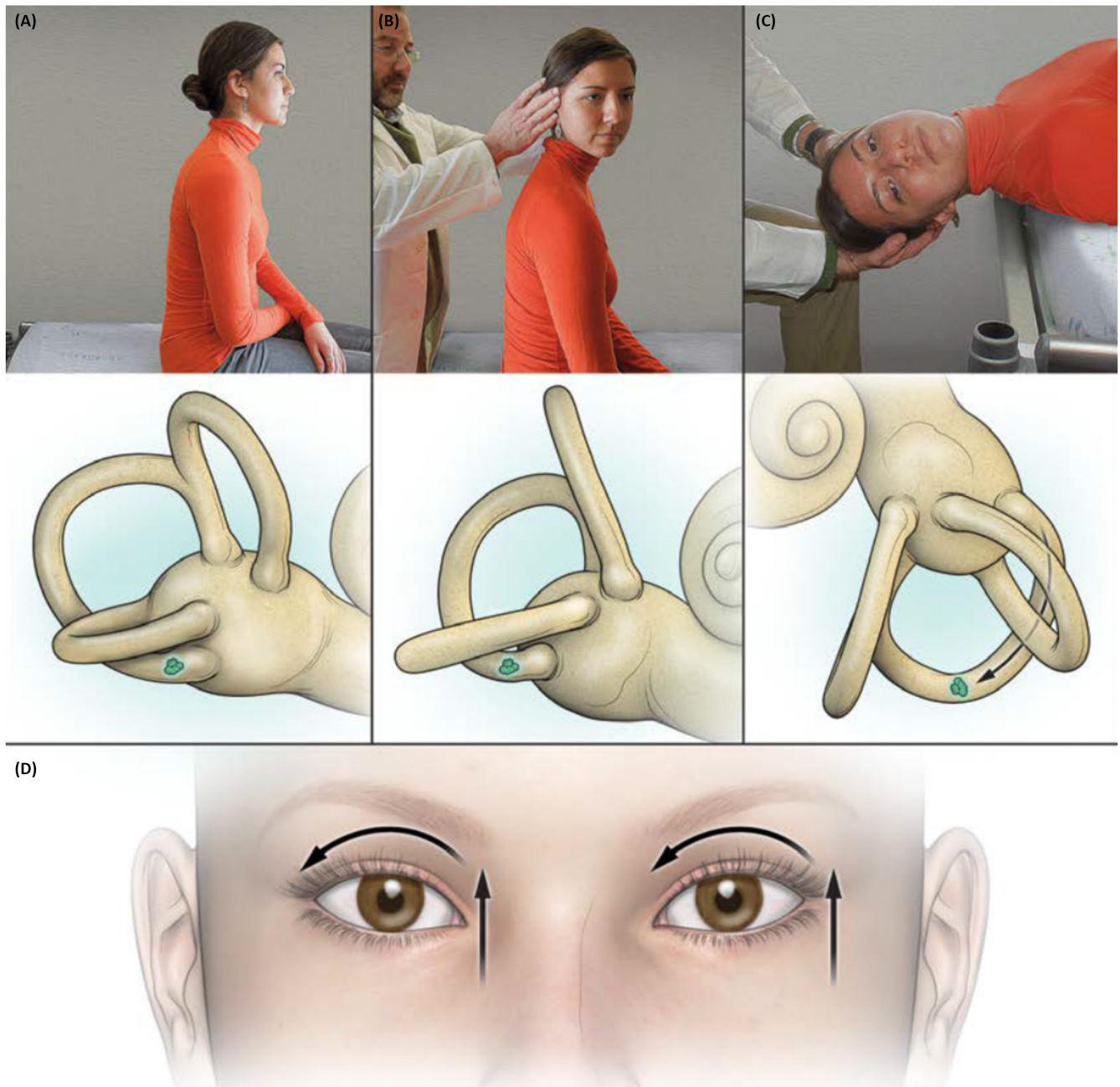


FIGURE 7 Dix-Hallpike test. Shown is a right Dix-Hallpike test. With the patient sitting upright (A), the head is turned 45° to the patient's right (B). The patient is then moved from the sitting position to the supine position with the head hanging below the top of the examination table at an angle of approximately 20° (C). The resulting nystagmus in right pc-BPPV is upbeating and torsional, with the top (12 o'clock) poles of the eyes beating toward the lowermost (right) ear for the torsional component (D). A left Dix-Hallpike test is performed similarly, but with a head turn 45° to the left; the resulting nystagmus of left pc-BPPV is also mixed upbeating and torsional, but the torsional component beats toward the left ear (Reproduced with permission of the *New England Journal of Medicine* ©2000.²³²)

true for training in canalith repositioning maneuvers like the Epley maneuver, since successful treatment aids in correct diagnosis.

Decision criteria and additional considerations

Decision criteria are based on substantial indirect evidence supporting the role of Dix-Hallpike test in diagnosis of BPPV and the lack of utility of imaging. Consideration needs to be given to the

fact that the existing literature on diagnosis of t-EVS and BPPV assumes proficiency in performance and interpretation of the Dix-Hallpike test. Our group recognizes and acknowledges that many emergency clinicians have limited experience or are uncomfortable diagnosing and treating different BPPV variants based on the nature of nystagmus elicited by the Dix-Hallpike test or other positional tests.

Another consideration our group acknowledges is that there may be limited access to specialty care or telemedicine with VOG,

depending on the practice setting. Nonetheless, establishing some follow-up care for patients with t-EVS is important. As noted previously, in some settings, a physical therapist with advanced vestibular training may be the most qualified clinician available locally or within a reasonable time frame, so that may be the only referral choice in such environments.

After a lengthy debate about hc-BPPV, the writing committee made a conscious decision to simplify our recommendations and to restrict them to pc-BPPV (the most common type). Some committee members felt that a recommendation for hc-BPPV should have been included because this variant constitutes an important minority of total BPPV patients, especially in acutely presenting patients in an ED population,²³⁷ because hc-BPPV patients are often more severely symptomatic than patients with pc-BPPV.²³⁸

In a study of 352 consecutive ED patients with acute dizziness (not restricted to BPPV), hc-BPPV accounted for 20% of the total patients.³ The recently completed AVERT trial (NCT02483429), which used the most rigorous diagnostic methods in any ED-based trial to date, found that among 43 BPPV patients, 20 had pc-BPPV, 16 had hc-BPPV, and seven had other variant forms (including multicanal BPPV).¹⁸¹ We encourage clinicians to consider hc-BPPV in patients whose histories suggest BPPV but whose Dix–Hallpike test is either negative or shows horizontal nystagmus.¹⁴⁸ The specific diagnostic maneuver for hc-BPPV is the supine roll test and the corresponding therapeutic maneuver is the Lempert (barbeque) roll.⁶⁷ An alternative therapeutic technique is the Gufoni maneuver.^{67,239}

Conclusions and research needs

Direct evidence from the ED regarding the role of Dix–Hallpike test and/or imaging in the setting of t-EVS is limited. The Dix–Hallpike test is the criterion standard maneuver to diagnose pc-BPPV. The available data suggest that proper use of the Dix–Hallpike test should be disseminated more widely and that there should be a very limited role for brain imaging in t-EVS patients. When patients have nystagmus that is not typical for posterior or hc-BPPV or who fail to respond to canalith repositioning maneuver treatments, MRI could be considered, although the incidence of central causes of positional vertigo (other than vestibular migraine) is rare. Most of these patients will have other forms of BPPV and clinicians should also consider referring to a vestibular specialist or, if not available, a physical therapist with advanced vestibular training, if the interval between the ED visit and the follow-up visit is not too long. CT should not be performed.

Future work should focus on education and training of ED providers on appropriate application and interpretation of Dix–Hallpike test and treatment of BPPV. In addition, as providers become more familiar with pc-BPPV and if subsequent data confirm recent studies suggesting that hc-BPPV is more common in an early-presenting population than previously thought,^{3,61,181,182,237} learning about

other variants, especially geotropic and apogeotropic hc-BPPV, will allow correct management of a much larger proportion of BPPV patients (and thus, of all patients with acute dizziness).

QUESTION 4: Should adult ED patients diagnosed with vestibular neuritis be treated with steroids? [EtD frameworks are presented in Appendix S7].

Recommendation 14: In adult ED patients with a clinical diagnosis of vestibular neuritis, we suggest shared decision making with patients to weigh risks and benefits of short-term steroid treatment for those presenting within 3 days of symptom onset (conditional recommendation, **FOR**) [very low certainty of evidence].

Summary of evidence

Patients confirmed by bedside examination to have an acute unilateral peripheral vestibulopathy (usually vestibular neuritis) may benefit from acute treatment with steroids. The systematic review found mixed results, with some direct randomized trial evidence of efficacy on improved physiologic function but no evidence of symptomatic benefit or improved health-related quality of life with steroids. Given that loss of vestibular function may be well compensated in the short term but create a state of less balance “reserve” in the longer term (e.g., as the patient ages and loses the ability to compensate for the loss), the group felt that the evidence supported a conditional recommendation for shared decision making with patients around steroid treatments. Regardless of treatment choice, the group supported postdischarge referral for vestibular rehabilitation therapy, which is supported by systematic review evidence of efficacy.²⁴⁰

Direct and indirect evidence

Two types of outcome measures were reported at various time intervals—patient reported (vertigo symptoms and the Dizziness Handicap Inventory score) and physiologic (laboratory testing of caloric function). There was no difference in patient-reported vertigo at 24 h (two studies, $n=60$, 53% vs. 87%, RR 0.39, 95% CI 0.04–3.57, very low certainty of evidence).^{91,92} Measured at 1 month, there was no difference in the Dizziness Handicap Inventory score with steroids compared to either placebo or vestibular exercises (one study, $n=30$, 20.9 vs. 15.8 points, 73.3% vs. 80.0% with persistent symptoms, respectively, very low certainty of evidence). Different studies used different steroid protocols.

For laboratory outcomes, the steroid group had a higher rate of caloric recovery at 1 month (two studies, $n=50$, RR 2.81, 95% CI 1.32–6.00, low certainty of evidence), and the rate of caloric

lateralization was decreased at 1 month post-symptom onset (two studies, $n=80$, mean difference -8.33 , 95% CI -16.33 to -0.32 , very low certainty of evidence).²⁴¹

The writing committee including our patient representatives placed greater value on the patient-reported outcomes than on the physiologic ones. However, the committee also considered the hypothesis that initially well-compensated, asymptomatic reductions in vestibular function might become important later in life, if a patient had a second vestibular insult or age-related decreases in vestibular function.²⁴² This may be analogous to small, asymptomatic decreases in left ventricular ejection fraction from delayed treatment of a myocardial infarction. For example, a patient may not perceive a drop from 65% to 50%, but a second cardiac event that further reduces the ejection fraction to 35% might become symptomatic. There was no difference in serious adverse effects (2.9% vs. 0%), although there were higher rates of minor adverse events in the steroid group (range 5.9 to 22.9% vs. 0%).²⁴¹

Benefits

In patients with vestibular neuritis, improvement in dizziness is an important outcome. Because the pathophysiology of acute vestibular neuritis (inflammation of the vestibular component of the eighth cranial nerve) is thought to be similar to that of seventh cranial nerve in Bell's palsy, many specialists routinely prescribe corticosteroids. Given the very low certainty of the evidence for this intervention, we feel that clinicians should weigh the pros and cons of steroid treatment in patients with vestibular neuritis and engage patients in shared decision making.²⁴³ Relative contraindications (e.g., history of poorly controlled diabetes or bipolar disorder with mania) or a patient's concerns about steroid use should factor into this discussion.

Harms and burden

The harms of steroids are well known. Our umbrella review found one case of gastrointestinal bleeding that required intervention and several cases of hyperglycemia.²⁴¹

Decision criteria and additional considerations

Emergency clinicians commonly use "vestibular suppressants" (such as benzodiazepines, anticholinergics such as scopolamine, and antihistamines such as meclizine) for patients with acute dizziness. Meclizine is the most commonly administered medication for dizziness in the United States.²⁴ Given the lack of current high-quality evidence addressing their use in vestibular neuritis, a formal evidence-based recommendation cannot be made at this time. However, content experts on the committee felt that for patients

with vestibular neuritis, it is reasonable to use these medications for a very short period of time (several days) to reduce acute symptoms. Longer use beyond several days is discouraged, in part because it inhibits the physiological compensation²⁴⁴ and in part due to side effects.²⁴⁵ The American Geriatric Society recommends *against* using meclizine in older individuals due to its anticholinergic side effects.²⁴⁶

Conclusions and research needs

Research needs to be done in sufficient numbers of patients with vestibular neuritis to test the hypothesis that earlier treatment with corticosteroids (e.g., within 2–3 days of onset) shows a signal for efficacy compared to later treatment.²⁴⁷

QUESTION 5: Should ED adult patients diagnosed with BPPV be treated with the Epley maneuver? [ETD frameworks are provided in Appendix S8].

Recommendation 15: In adult ED patients with pc-BPPV diagnosed by a positive Dix–Hallpike test, we recommend the Epley canalith repositioning maneuver be performed at the time of diagnosis (strong recommendation, **FOR**) [moderate certainty of evidence]

Summary of evidence

Patients confirmed by bedside examination to have pc-BPPV may benefit from acute treatment with the Epley maneuver. The evidence supported a strong recommendation for treatment with the Epley canalith repositioning maneuver, which is consistent with other guidelines.^{67,68}

Direct and indirect evidence

There were two outcomes of interest—symptom resolution and conversion of a positive Dix–Hallpike test to a negative Dix–Hallpike test. For the outcome of complete symptom resolution, there was a significant difference in favor of the treatment group observed in each trial. We extracted the data of all RCTs that reported 7-day outcomes and complete resolution of symptoms was favorable for the intervention (four RCTs, $n=251$, OR 5.32, 95% CI 2.95–9.59, low certainty).^{248–250} Conversion to a negative Dix–Hallpike test was also favorable for patients who received canalith repositioning maneuvers (three RCTs, $n=195$, OR 5.96, 95% CI 3.10–11.47, low certainty).^{248–251} These studies were not on ED patients. Longer time intervals were also assessed (and also favored the intervention); however, we chose the 7-day outcome

intentionally since over time, patients with BPPV will resolve spontaneously, which would dilute positive short-term outcomes. Sensitivity analysis including observational studies and outcomes at 30 days demonstrated a similar positive effect of the intervention (canal repositioning maneuvers; please see [Figures 2–5](#) in [Appendix S8](#)).

In the two studies, all patients received an “active treatment” (either medication or postural restriction exercises) and then randomized half the patients to receive the Epley maneuver, and the outcomes were reported as a composite measure of symptom resolution and Dix–Hallpike test result.^{252,253} For the purposes of analysis, this has been rationalized to a dichotomous variable of “cured” versus “persisting symptoms.” There was a statistically significant effect of treatment in each trial at 7 days, favoring the group that also received an Epley treatment in each case: OR 12.35 (95% CI 1.51–101.36)²⁵² and OR 41.73 (95% CI 12.29–141.65).²⁵³

Both neurology and otolaryngology society guidelines on BPPV recommend performing the Epley maneuver for pc-BPPV.^{67,68} The 2008 neurology practice parameter reported the number needed to treat (NNT) from individual studies ranging from 2 to 4.⁶⁸ Most of the data on the efficacy of the Epley maneuver comes from specialty clinics, but one prospective, single-blind placebo-controlled trial of 22 consecutively enrolled ED patients with BPPV randomized to have the Epley performed by emergency clinicians or a placebo maneuver reported significant reduction of patient-reported symptoms treated with the Epley (median decrease in 10-point visual analog score of six [Epley] vs. one [placebo]).¹ Therefore, all of the evidence points in the same direction.

Benefits

BPPV is the most common vestibular disorder, with a population-level lifetime prevalence of 2.4%, 1-year prevalence of 1.6% and a lifetime cumulative incidence of nearly 10%.²⁵⁴ It is associated with significant reductions in quality of life,²⁵⁵ but has highly effective, rapid bedside treatments. Prompt treatment of BPPV improves health-related quality of life,^{256–258} while failure to treat BPPV doubles the recurrence rate (46% vs. 20%, $p=0.002$)⁷⁴ and increases the odds of falls 6.5-fold,²⁵⁹ thereby increasing risk of fractures.²⁶⁰

The benefits of treating patients with pc-BPPV with a bedside therapeutic maneuver are large given the very small NNT. The primary benefits are decreased patient symptoms with potential subsequent fall and injury reduction.^{261,262} In addition, earlier treatment with an Epley maneuver in the ED may be more effective than later treatment that would result from referral,⁷⁶ and reduce the frequency of recurrences,⁷⁴ further supporting performing the Epley maneuver in the ED at the time of diagnosis. Diagnosing and treating this common condition should result in fewer consults, less imaging, and shorter ED lengths of stay. Patients with persistent pc-BPPV,

whose Dix–Hallpike test is still positive after a correctly performed Epley maneuver, can have the procedure repeated.^{148,263} If the symptoms persist after repeated properly performed canalith repositioning maneuvers, clinicians should question the diagnosis and consider hc-BPPV or central causes.

Harms and burden

Other than transient patient discomfort and occasional vomiting during the Epley maneuver (which, when effectively performed, will reproduce the patient's symptoms), there are no harms of performing the Epley maneuver. Both discomfort and vomiting can be mitigated with adequate patient coaching and prophylactic antiemetics, although the latter do not need to be used routinely. The only “burden” is the necessary training for emergency clinicians to learn how to do the procedure.

Decision criteria and additional considerations

Emergency clinicians commonly use “vestibular suppressants” (such as benzodiazepines, anticholinergics such as scopolamine, and antihistamines such as meclizine) for patients with acute dizziness. Given the lack of current high-quality evidence addressing use of suppressants in BPPV, a formal evidence-based recommendation cannot be made at this time. Meclizine is the most commonly administered medication for dizziness in the United States, even for BPPV, which should generally be treated instead by using highly effective canalith repositioning maneuvers (e.g., Epley maneuver).²⁴

However, with regard to using vestibular suppressants in patients with BPPV, we agree with both the 2008 American Academy of Neurology and the 2017 American Academy of Otolaryngology–Head and Neck Surgery guidelines that discourage the use of these medications.^{67,68} In select patients who have residual mild symptoms after a successfully administered Epley (or other canalith repositioning) maneuver, as evidenced by conversion of the Dix–Hallpike test from positive to negative, a few days of vestibular suppressants may help reduce symptoms but should not be used for longer periods of time. Earlier treatment with an Epley maneuver is more effective than later treatment⁷⁶ and can reduce the incidence of falls.^{259,261,262} A systematic review on this subject *recommends against using vestibular suppressants*.²⁶⁴ If one were to use a vestibular suppressant, a recent systematic review found that single-dose antihistamines were more effective than single-dose benzodiazepines at reducing vertigo at 2 h after administration.²⁶⁵ However, we do not recommend use of these medications as the primary treatment for patients with BPPV. As discussed, we encourage clinicians to consider hc-BPPV in patients whose histories suggest BPPV but whose Dix–Hallpike test either is negative or shows horizontal nystagmus; if properly trained and

comfortable with the diagnosis, clinicians should treat hc-BPPV in the ED.¹⁴⁸

Conclusions and research needs

Focused training is key for treating pc-BPPV with an Epley maneuver. Although the precise duration and components of that training remain to be fully determined, the ability to watch one of many easily accessible web-based video examples prior to performing the procedure should mitigate the lack of familiarity with this procedure and minimize the time required for training. Approaching this procedure with the same deliberate practice as other high-yield procedures in emergency medicine will improve patient outcomes and health.

GENERAL ISSUES NECESSARY FOR CORRECT INTERPRETATION AND IMPLEMENTATION OF RECOMMENDATIONS

Limitations

The largest limitation is that the majority of the studies that we found included either ED patients with unspecified acute dizziness (i.e., without specifying vestibular syndromes) or a cohort of patients with AVS. Very few studies evaluated patients with spontaneous or t-EVS, and physical examination maneuvers were not always performed by emergency clinicians. However, because the diagnostic maneuvers we analyzed are heavily rooted in basic neurophysiology, there is no biologically plausible reason that they would not work if performed in an ED population by trained emergency clinicians. The crucial caveat is that emergency clinicians must learn to perform the maneuvers and interpret results effectively and, currently, no validated training program exists. Creation of such a program with validated content, methods, and duration that result in proficiency should be a priority for emergency medicine.²⁶⁶

Assumed values and preferences

Our three patient representatives played an active role in this domain, but there are no systematic data about patient preferences on a large scale. When discussing issues related to communication in the ED, although patients initially expressed a sense of relief upon hearing that a CT scan was normal, once they understood the lack of utility of a CT in the vast majority of acutely dizzy patients, they placed less value on having a “negative test” that, in reality, added little to their care and may have actually conferred some harm from radiation⁵² and false reassurance. Our patient representatives are active with patient advocacy and

educational organizations and related that many patients with recurrent episode of dizziness avoid the ED because of prior negative experiences.

These discussions highlight two points. First, the patient representatives felt that they had received care that was not as nuanced as it should be—both with regard to diagnosis (e.g., indiscriminate use of CT) and to treatment (e.g., indiscriminate use of meclizine). The second relates to doctor–patient communication. The patient representatives placed high value on clear communication in terms of both the diagnosis and uncertainty. They also saw value in receiving discharge instructions that at least opened the door to options beyond, “see your PCP” (see sample discharge instruction sheet in the online appendix).

Similarly, the physicians on the writing committee placed great value on making a specific diagnosis, especially in confidently diagnosing or excluding acute stroke. Again, this underscores the critical importance of developing a mechanism by which emergency clinicians in routine practice can become trained and/or certified in physical examination elements with which most are not currently familiar or not comfortable. This training coupled with better knowledge about limitations of imaging in these patients can lead to more nuanced and informative shared decision-making conversations.

Implementation considerations

Guidelines can inform management decisions for many patients. However, in real-world practice, mitigating factors or nuanced, variable presentations often result in logical reasons to deviate from a recommendation and employ alternative strategies. These may be due to biological diversity (e.g., a patient with isolated dizziness but with a severe acute-onset headache), situational realities (e.g., a rural ED without emergency clinicians trained in some of the bedside maneuvers, no MRI or consultant availability), or patient-specific factors (e.g., difficulty in obtaining a detailed history or contraindications to MRI). In Box 4, we have listed some of these factors that may affect the implementation of these guidelines in specific situations.

Planning for updating these guidelines

These guidelines are current as of the literature review done in December 2021. As new evidence accumulates, this guideline may need to be revised. Adoption of these guidelines should be tailored to local policies and practices and availability of specialists and telemedicine and video-oculography, which may differ in different locations. As with any guideline, clinician judgment and the implementation considerations above need to be factored into the management of any individual patient.

Box 4. Implementation considerations

Situation Implementation consideration

Question 1: Diagnosis of patients with the AVS

Unavailability of a clinician trained in the HINTS examination

For emergency clinicians who are not adequately trained in performance and interpretation of HINTS, either consultation with an appropriately trained specialist should be obtained to perform HINTS testing or neuroimaging by MRI should be used to aid in differentiating stroke from non-stroke cases, assuming the availability of consultants and/or MRI.

Potential solutions: Training emergency clinicians is the main fix to this problem but is a long-term one. Some clinicians may develop expertise in portions of the HINTS examination, especially nystagmus evaluation, which, by themselves (if a central pattern) or in combination with vascular risk factor profile or gait instability, can be useful without performing all three HINTS components. In some environments including some EDs, physical therapists with advanced vestibular training may be more available or more rapidly available than a physician. Use of VOG may also help facilitate access to specialists remotely.

For emergency clinicians who are not adequately trained in performance and interpretation of HINTS and who also lack routine access to MRI neuroimaging, CT (with or without CTA) is insufficient to “rule out” ischemic stroke.

Potential solutions: Several options exist to help maximize patient safety including hospital admission for observation, transfer to a facility that has MRI, empirically initiating aspirin or other appropriate prophylaxis if there is a high suspicion for stroke, or arranging an urgent outpatient MRI.

Optimal timing of MRI

The sensitivity of MRI for stroke causing an AVS evolves with elapsed time. Overall sensitivity is approximately 80%–90% in the first 48 h (using a criterion standard of delayed MRI > 72 h from symptom onset).

Potential solutions: In patients with a central or equivocal HINTS examination or when a clinician trained in HINTS is unavailable, this relationship between time and sensitivity should be factored into the decision about when to perform MRI and how to interpret an early-performed MRI.

Possible candidate for thrombolysis, reperfusion, or other time-sensitive interventions

In adult ED patients with AVS who are *potential candidates* for reperfusion therapies (or other treatments that must be applied rapidly such as ventriculostomy for hydrocephalus or decompressive suboccipital craniectomy for brain stem compression or impending herniation), which may require definitive exclusion of intracranial hemorrhage prior to initiation, CT is generally much faster than MRI in most EDs and is preferable if MRI instead would delay acute treatments for ischemic stroke.

Potential solutions: Consider the possibility of an acute stroke. These patients will usually have other clinical findings. Using thrombolysis for a patient with a very low NIH stroke score is a judgment call, but if it is a possible action, obtaining a CT first will facilitate the intervention. If reperfusion therapy is indicated, CT/CTA or CT/CTP should also be obtained to optimize acute stroke interventions. Consider activating local stroke guidelines.

Symptoms or signs strongly suggestive of ICH

In adult ED patients with AVS *and* neurological symptoms or signs strongly suggesting the possibility of intracranial hemorrhage (e.g., severe headache, lethargy/confusion/mental status abnormality, hemiparesis, inability to maintain upright posture sitting or standing), and especially those patients who may require urgent neurosurgical intervention (e.g., ventriculostomy, posterior fossa decompression, or anticoagulation reversal), waiting for an MRI will delay treatments.

Potential solutions: If other symptoms or signs suggest the possibility of an ICH, obtaining a CT first may facilitate treatment. Almost all ICH patients presenting with dizziness will have other clinical findings beyond isolated dizziness.

Absolute contraindication to MRI

In adult ED patients with AVS *and* central signs (including central HINTS examination findings) who have absolute contraindications to MRI (e.g., non-MRI-safe metallic implants), CT/CTA plus CT/CTP should be performed. (Note: CT/CTA should be performed first to be able to complete both tests without a second contrast dye load.)

Potential solutions: Some patients can be pretreated to prevent or minimize an anaphylactoid reaction to contrast but this will delay the MRI. Some patients with pacemakers can undergo MRI after cardiology consultation. If the MRI absolutely cannot be done, manage the patient understanding the intrinsic limitations of CT-based tests.

Box 4. Continued**Situation Implementation consideration***Relative contraindication to MRI*

In adult ED patients with AVS and central signs (including central HINTS examination findings) who have relative contraindications to MRI (e.g., severe claustrophobia, unstable cardiac/medical status), MRI may or may not be possible.

Potential solutions: Most relative contraindications can be mitigated by medications (severe anxiety or claustrophobia) or intubation (for altered mental status). (Note: If CT-based testing is done in place of MRI, the CT/CTA should be performed first to be able to complete both tests without a second contrast dye load.)

Unavailability of MRI at your facility

In some EDs, MRI may not be available or not available in a timely fashion.

Potential solutions: Patients in whom the decision to perform the MRI is because of specific findings, such as a central-pattern HINTS, can be admitted and have the MRI done later, as an inpatient. In situations where the MRI result is going to determine hospital admission versus not, then these patients may need to be transferred to a hospital with MRI capability.

Question 2: Diagnosis of patients with the s-EVS*Probable vestibular migraine diagnosis*

In adult ED patients with s-EVS whose presentation suggests a vestibular migraine or Menière diagnosis referral both to the primary care physician and to a neurologist, otolaryngologist, or vestibular specialist should be considered if available.

Potential solutions: None required; be aware that vestibular migraine is a very common condition.

Possible TIA diagnosis

In adult ED patients with s-EVS, no specific decision rules currently exist to guide who should receive advanced neuroimaging; however, the Canadian TIA score may help clinicians estimate short-term risk.

Potential solutions: None required; however, understand that risk stratification tools have intrinsic limitations and the Canadian rule in particular subtracts points for a history of vertigo. In older patients, consider vascular risk factors, and in younger patients, consider the possibility of a vertebral artery dissection. In all patients, consider BPPV and vestibular migraine as potential TIA mimics.

Question 3: Diagnosis of patients with the t-EVS*When to consider hc-BPPV*

pc-BPPV is the most common type. In adult ED patients who present with a suggestive history of BPPV but have a negative Dix-Hallpike test (or one that elicits horizontal nystagmus), consider testing for hc-BPPV with a supine roll test. Newer data suggest that hc-BPPV is more common in ED populations than has been reported in outpatient referral clinics.

Potential solutions: Educational programs for emergency clinicians will ideally result in proficiency in diagnosis and treatment of hc-BPPV as well as pc-BPPV. Note that the direction of nystagmus determines both the affected canal and the appropriate canalith repositioning maneuver treatment, even if the nystagmus was elicited by the “wrong” positional testing maneuver (e.g., if Dix-Hallpike test elicits horizontal nystagmus, it is not pc-BPPV and it is likely hc-BPPV; likewise, if the supine roll test elicits upbeat-torsional nystagmus it is not hc-BPPV and it is likely pc-BPPV).

When to consider CPPV

In adult ED patients with t-EVS who have additional neurological symptoms or signs (e.g., acute headache, visual disturbance, unilateral hearing loss, diplopia, new inability to walk independently), that are not seen in typical BPPV, consider CPPV.

Potential solutions: CPPV is very uncommon in an all-comer ED population but can be suspected based on additional neurologic symptoms or atypical nystagmus patterns for BPPV (see text). In those with nystagmus that is atypical for BPPV, consider MRI to diagnose central causes. Clinicians familiar with BPPV variants (including apogeotropic hc-BPPV or anterior canal BPPV) may elect to try bedside maneuvers to treat those variants or refer to a specialist without performing MRI.

Box 4. Continued

Situation Implementation consideration

Question 4: Steroid treatment for patients with vestibular neuritis

Clinical diagnosis of vestibular neuritis and timing of initiation of steroid treatment

In adult ED patients diagnosed with vestibular neuritis, data suggest that earlier initiation of steroids is more effective than later treatment and should ideally be applied within 72 h of symptom onset.

Potential solutions: In patients diagnosed with vestibular neuritis, if you have decided with the patients that steroids are to be given, start them in the ED or on the same day as the ED visit. Shared decision making with the patient and a discussion with a specialist about starting steroids in the ED should be considered rather than referring and delaying a treatment decision.

Question 5: Treatment of patients clinically diagnosed with BPPV

"Wrong" nystagmus

Presentation suggests BPPV but the Dix–Hallpike test does not show the expected nystagmus (upbeat–torsional).

Potential solutions: In this situation, first consider performing the supine roll test for hc-BPPV. If brisk geotropic horizontal nystagmus is found, consider treating the patient for hc-BPPV with a canalith repositioning maneuver (e.g., Lempert [barbecue] roll or Gufoni maneuver). If no nystagmus is found but the patient is symptomatic on one side only ("subjective" BPPV), block fixation if you can (e.g., Frenzel lenses). If not, consider attempting the canalith repositioning maneuver for the symptomatic side even without the confirmatory nystagmus (e.g., if right-sided Dix–Hallpike test provokes typical symptoms but left Dix–Hallpike test left does not, treat with right Epley as if the Dix–Hallpike test had shown the nystagmus [which may be less apparent if you do not have special lenses to block visual fixation]).

Epley does not work

Epley or other canalith repositioning maneuver does not result in resolution of symptoms.

Potential solutions: Most commonly this is because the diagnosis is incorrect (either the wrong canal is being treated or it is not BPPV). In this situation, consider performing a supine roll test and, if positive, treating the patient for hc-BPPV with either a Lempert (barbecue) roll or Gufoni maneuver. If the diagnosis of pc-BPPV is correct, the most common cause for a treatment failure is suboptimal technique in performing the Epley. The most common mistake is not hanging the head far enough over the edge of the bed during the rotation. Also, treating more than once with good technique increases the chances of treatment success. Most specialists will repeat the maneuver until the patient is asymptomatic during the Dix–Hallpike test and then finish with one final Epley; it is not uncommon for specialists to treat two to four times with the Epley. If the patient remains symptomatic despite multiple properly performed canalith repositioning maneuvers, consider obtaining MRI to exclude a structural cause. Those with a typical presentation and findings of pc-BPPV can be referred to a vestibular specialist or, if that is not available, a physical therapist with advanced vestibular training, without an MRI being ordered.

AUTHOR CONTRIBUTIONS

All authors participated in the writing and review of this manuscript.

CONFLICT OF INTEREST STATEMENT

All group members disclosed conflicts of interest using SAEM's standard methods. All members were able to participate as a voting member with the following disclosures and management. Dr. Bellolio receives funding from AHRQ for the study of diagnostic errors, NIH, FDA, and Kern Center for palliative and geriatric care related research. Dr. Carpenter is the Deputy Editor-in-Chief *Academic Emergency Medicine*; Associate Editor, *Annals of Internal Medicine's* ACP Journal Club; and Associate Editor, *Journal of the American Geriatrics Society*. Dr. Carpenter serves on the American College of Emergency Physicians Clinical Policy Committee and the American Board of Emergency Medicine and the MyEMCert Editor. Dr. Carpenter's involvement with the ACEP Clinical Policy Committee as a member of the "Acute Stroke" writing team was disclosed to

the GRACE-3 Writing Team, *Academic Emergency Medicine* Editorial Board, and Society for Academic Emergency Medicine Board of Directors in writing and verbally on multiple occasions during the course of developing GRACE-3. To minimize the potential for divergent recommendations between the ACEP "Acute Stroke" Clinical Policy and GRACE-3, the GRACE-3 PICO questions and emerging direction of recommendations were discussed repeatedly with both the Clinical Policy Committee and the GRACE-3 Writing Team over the course of 12 months as both documents were being developed. Dr. Edlow is a compensated Section Editor for UpToDate and a compensated reviewer for both defense and plaintiff medical malpractice cases, some of which are related to dizziness and stroke. Dr. Kline's spouse, Anne Messman, MD, is an emergency medicine physician uninvolved in the writing of GRACE-3. Anne Messman is on the ACGME transitional year residency review committee. Dr. Marcolini is an Assistant Editor to *American Journal of Emergency Medicine* and a compensated reviewer for both defense

and plaintiff medical malpractice cases, some of which are related to dizziness and stroke. Dr. Meurer is an Associate Editor to *Annals of Emergency Medicine* and Senior Editor of *Trials*. Dr. Meurer provides medicolegal consulting via Meurer Consulting, LLC, without compensation in any cases of isolated acute or episodic vestibular syndrome. Dr. Meurer is a former compensated reviewer of legal cases pertaining to stroke. Mr. Morrill is a VeDA (Vestibular Disorders Association) patient ambassador. Dr. Naples is the Editor-in-Chief for Decker Med Publisher—*Otolaryngology Weekly Curriculum* in which he participates in designing online curriculum content for ENT. Dr. Naples is the Editor of *Ear & Hearing Journal*, serves on the Editorial Board of *Otolaryngology Head & Neck Surgery*, and is a voting member of the Otolaryngology & Neurotology Education Committee. Dr. Naples develops curriculum for *Otolaryngology & Neurotology* section of the American Academy of Otolaryngology. Dr. Newman-Toker conducts research related to diagnosis of dizziness and stroke as well as diagnostic error. He serves as the principal investigator for multiple grants and contracts on these topics, including the NIH-sponsored AVERT clinical trial (NIDCD U01 DC013778, [ClinicalTrials.gov #NCT02483429](https://clinicaltrials.gov/ct2/show/study/NCT02483429)). Johns Hopkins has been loaned research equipment (video-oculography [VOG] systems) by two companies for use in Dr. Newman-Toker's research; one of these companies has also provided funding for research on diagnostic algorithm development related to dizziness, inner ear diseases, and stroke. Dr. Newman-Toker has no other financial interest in these or any other companies. Dr. Newman-Toker is an inventor on a provisional patent (U.S. No. 62/883,373) for smartphone-based stroke diagnosis in patients with dizziness. He gives frequent academic lectures on these topics and occasionally serves as a medicolegal consultant for both plaintiff and defense in cases related to dizziness, stroke, and diagnostic error. Ms. Sundberg is VeDA (Vestibular Disorders Association) patient ambassador. Ms. Tartt is the founder of Clear Spirit & Mind. Dr. Upadhye is a Decision Editor for the *Canadian Journal of Emergency Medicine* (CJEM), is part of the Canadian Association of Emergency Physicians (CAEP) Choosing Wisely Canada (CWC) Working Group, and is Co-Chair of the Best Evidence in Emergency Medicine (BEEM) course, which produces and presents CME events annually. Dr. Upadhye is also the creator of Emergency Medicine Guidelines Website. Management: Recused from decisions on GRACE-3 distribution. The other authors declare no conflicts of interest.

ORCID

Jonathan A. Edlow [ID](https://orcid.org/0000-0001-6855-0912)
 Christopher Carpenter [ID](https://orcid.org/0000-0002-2603-7157)
 Murtaza Akhter [ID](https://orcid.org/0000-0001-9693-6871)
 Danya Khoujah [ID](https://orcid.org/0000-0002-0373-606X)
 Evie Marcolini [ID](https://orcid.org/0000-0002-1166-1045)
 William J. Meurer [ID](https://orcid.org/0000-0002-1158-5302)
 James G. Naples [ID](https://orcid.org/0000-0002-6676-6418)
 Robert Ohle [ID](https://orcid.org/0000-0001-8263-0556)
 Rodney Omron [ID](https://orcid.org/0000-0002-6981-2846)
 Sameer Sharif [ID](https://orcid.org/0000-0002-3346-0308)

Matt Siket [ID](https://orcid.org/0000-0003-0018-1019)
 Suneel Upadhye [ID](https://orcid.org/0000-0002-6380-161X)
 Lucas Oliveira J. e Silva [ID](https://orcid.org/0000-0001-5388-9163)
 Simone Vanni [ID](https://orcid.org/0000-0002-1201-5715)
 David E. Newman-Toker [ID](https://orcid.org/0000-0003-2789-4115)
 Fernanda Bellolio [ID](https://orcid.org/0000-0002-1632-4750)

REFERENCES

- Chang AK, Schoeman G, Hill M. A randomized clinical trial to assess the efficacy of the Epley maneuver in the treatment of acute benign positional vertigo. *Acad Emerg Med*. 2004;11:918-924.
- Gerlier C, Hoarau M, Fels A, et al. Differentiating central from peripheral causes of acute vertigo in an emergency setting with the HINTS, STANDING, and ABCD2 tests: a diagnostic cohort study. *Acad Emerg Med*. 2021;28:1368-1378.
- Vanni S, Pecci R, Edlow JA, et al. Differential diagnosis of vertigo in the emergency department: a prospective validation study of the STANDING algorithm. *Front Neurol*. 2017;8:590.
- Epley JM. The canalith repositioning procedure: for treatment of benign paroxysmal positional vertigo. *Otolaryngol Head Neck Surg*. 1992;107:399-404.
- Hunt WT, Zimmermann EF, Hilton MP. Modifications of the Epley (canalith repositioning) manoeuvre for posterior canal benign paroxysmal positional vertigo (BPPV). *Cochrane Database Syst Rev*. 2012;CD008675.
- Newman-Toker DE, Hsieh YH, Camargo CA Jr, Pelletier AJ, Butchy GT, Edlow JA. Spectrum of dizziness visits to US emergency departments: cross-sectional analysis from a nationally representative sample. *Mayo Clin Proc*. 2008;83:765-775.
- Cheung CS, Mak PS, Manley KV, et al. Predictors of important neurological causes of dizziness among patients presenting to the emergency department. *Emerg Med J*. 2010;27:517-521.
- Idil H, Ozbay Yenice G, Kilic TY, Eyley Y, Duman AO. The incidence of central neurological disorders among patients with isolated dizziness and the diagnostic yield of neuroimaging studies. *Neurologist*. 2020;25:85-88.
- Kerber KA, Meurer WJ, West BT, Fendrick AM. Dizziness presentations in U.S. emergency departments, 1995–2004. *Acad Emerg Med*. 2008;15:744-750.
- Ljunggren M, Persson J, Salzer J. Dizziness and the acute vestibular syndrome at the emergency department: a population-based descriptive study. *Eur Neurol*. 2018;79:5-12.
- Newman-Toker DE. Missed stroke in acute vertigo and dizziness: it is time for action, not debate. *Ann Neurol*. 2016;79:27-31.
- Saber Tehrani AS, Coughlan D, Hsieh YH, et al. Rising annual costs of dizziness presentations to U.S. emergency departments. *Acad Emerg Med*. 2013;20:689-696.
- Kerber KA, Schweigler L, West BT, Fendrick AM, Morgenstern LB. Value of computed tomography scans in ED dizziness visits: analysis from a nationally representative sample. *Am J Emerg Med*. 2010;28:1030-1036.
- Drachman DA, Hart CW. An approach to the dizzy patient. *Neurology*. 1972;22:323-334.
- Edlow JA. The timing-and-triggers approach to the patient with acute dizziness. *Emerg Med Pract*. 2019;21:1-24.
- Kerber KA, Newman-Toker DE. Misdiagnosing dizzy patients: common pitfalls in clinical practice. *Neurol Clin*. 2015;33:565-575.
- Bisdorff A, Staab J, Newman-Toker D. Overview of the international classification of vestibular disorders. *Neurol Clin*. 2015;33:541-550.
- Kerber KA, Callaghan BC, Telian SA, et al. Dizziness symptom type prevalence and overlap: a US nationally representative survey. *Am J Med*. 2017;130:1465.e1-1465.e9.

19. Newman-Toker DE, Cannon LM, Stofferahn ME, Rothman RE, Hsieh YH, Zee DS. Imprecision in patient reports of dizziness symptom quality: a cross-sectional study conducted in an acute care setting. *Mayo Clin Proc.* 2007;82:1329-1340.
20. Edlow JA. Diagnosing dizziness: we are teaching the wrong paradigm! *Acad Emerg Med.* 2013;20:1064-1066.
21. Edlow JA, Gurley KL, Newman-Toker DE. A new diagnostic approach to the adult patient with acute dizziness. *J Emerg Med.* 2018;54:469-483.
22. Edlow JA, Newman-Toker D. Using the physical examination to diagnose patients with acute dizziness and vertigo. *J Emerg Med.* 2016;50:617-628.
23. Newman-Toker DE. Charted records of dizzy patients suggest emergency physicians emphasize symptom quality in diagnostic assessment. *Ann Emerg Med.* 2007;50:204-205.
24. Newman-Toker DE, Camargo CA Jr, Hsieh YH, Pelletier AJ, Edlow JA. Disconnect between charted vestibular diagnoses and emergency department management decisions: a cross-sectional analysis from a nationally representative sample. *Acad Emerg Med.* 2009;16:970-977.
25. Kane B, Carpenter C. Cognition and decision-making. In: Fondahn E, Lane M, Vannucci P, eds. *Washington University Manual of Patient Safety and Quality.* Lippincott Williams and Wilkins; 2016:195-209.
26. Kerber KA, Brown DL, Lisabeth LD, Smith MA, Morgenstern LB. Stroke among patients with dizziness, vertigo, and imbalance in the emergency department: a population-based study. *Stroke.* 2006;37:2484-2487.
27. Navi BB, Kamel H, Shah MP, et al. Rate and predictors of serious neurologic causes of dizziness in the emergency department. *Mayo Clin Proc.* 2012;87:1080-1088.
28. Atzema CL, Grewal K, Lu H, Kapral MK, Kulkarni G, Austin PC. Outcomes among patients discharged from the emergency department with a diagnosis of peripheral vertigo. *Ann Neurol.* 2016;79(1):32-41.
29. Kerber KA, Zahuranec DB, Brown DL, et al. Stroke risk after nonstroke emergency department dizziness presentations: a population-based cohort study. *Ann Neurol.* 2014;75:899-907.
30. Kim AS, Fullerton HJ, Johnston SC. Risk of vascular events in emergency department patients discharged home with diagnosis of dizziness or vertigo. *Ann Emerg Med.* 2011;57:34-41.
31. Lee CC, Ho HC, Su YC, et al. Increased risk of vascular events in emergency room patients discharged home with diagnosis of dizziness or vertigo: a 3-year follow-up study. *PLoS One.* 2012;7:e35923.
32. Ghaith S, Voleti SS, Bellolio F, Edlow JA, Lindor RA. Dizziness as a missed symptom of central nervous system pathology: a review of malpractice cases. *Acad Emerg Med.* 2022. doi:10.1111/acem.14627
33. Cnyrim CD, Newman-Toker D, Karch C, Brandt T, Strupp M. Bedside differentiation of vestibular neuritis from central "vestibular pseudoneuritis". *J Neurol Neurosurg Psychiatry.* 2008;79:458-460.
34. Edlow JA. Diagnosing patients with acute-onset persistent dizziness. *Ann Emerg Med.* 2018;71:625-631.
35. Edlow JA, Newman-Toker DE. Medical and nonstroke neurologic causes of acute, continuous vestibular symptoms. *Neurol Clin.* 2015;33:699-716, xi.
36. Kattah JC, Talkad AV, Wang DZ, Hsieh YH, Newman-Toker DE. HINTS to diagnose stroke in the acute vestibular syndrome: three-step bedside oculomotor examination more sensitive than early MRI diffusion-weighted imaging. *Stroke.* 2009;40:3504-3510.
37. Kerber KA. Acute vestibular syndrome. *Semin Neurol.* 2020;40:59-66.
38. Newman-Toker DE, Kattah JC, Alvernia JE, Wang DZ. Normal head impulse test differentiates acute cerebellar strokes from vestibular neuritis. *Neurology.* 2008;70:2378-2385.
39. Tarnutzer AA, Berkowitz AL, Robinson KA, Hsieh YH, Newman-Toker DE. Does my dizzy patient have a stroke? A systematic review of bedside diagnosis in acute vestibular syndrome. *CMAJ.* 2011;183:E571-E592.
40. Strupp M, Bisdorff A, Furman JM, et al. Acute unilateral vestibulopathy/vestibular neuritis: Diagnostic criteria. *J Vestib Res.* 2022;e-published June 11, 2022 (currently in-press);32:389-406.
41. Kim AS, Sidney S, Klingman JG, Johnston SC. Practice variation in neuroimaging to evaluate dizziness in the ED. *Am J Emerg Med.* 2012;30:665-672.
42. Chalela JA, Kidwell CS, Nentwich LM, et al. Magnetic resonance imaging and computed tomography in emergency assessment of patients with suspected acute stroke: a prospective comparison. *Lancet.* 2007;369:293-298.
43. Ahsan SF, Syamal MN, Yaremchuk K, Peterson E, Seidman M. The costs and utility of imaging in evaluating dizzy patients in the emergency room. *Laryngoscope.* 2013;123:2250-2253.
44. Guarnizo A, Farah K, Lelli DA, Tse D, Zakhari N. Limited usefulness of routine head and neck CT angiogram in the imaging assessment of dizziness in the emergency department. *Neuroradiol J.* 2021;34:335-340.
45. Hwang DY, Silva GS, Furie KL, Greer DM. Comparative sensitivity of computed tomography vs. magnetic resonance imaging for detecting acute posterior fossa infarct. *J Emerg Med.* 2012;42:559-565.
46. Kabra R, Robbie H, Connor SE. Diagnostic yield and impact of MRI for acute ischaemic stroke in patients presenting with dizziness and vertigo. *Clin Radiol.* 2015;70:736-742.
47. Lawhn-Heath C, Buckle C, Christoforidis G, Straus C. Utility of head CT in the evaluation of vertigo/dizziness in the emergency department. *Emerg Radiol.* 2013;20:45-49.
48. Pavlovic T, Milosevic M, Trtica S, Budincevic H. Value of head CT scan in the emergency Department in Patients with vertigo without focal neurological abnormalities. *Open Access Maced J Med Sci.* 2018;6:1664-1667.
49. Wasay M, Dubey N, Bakshi R. Dizziness and yield of emergency head CT scan: is it cost effective? *Emerg Med J.* 2005;22:312.
50. Kerber KA, Burke JF, Brown DL, et al. Does intracerebral haemorrhage mimic benign dizziness presentations? A population based study. *Emerg Med J.* 2011;29:43-46.
51. Stanton VA, Hsieh YH, Camargo CA Jr, et al. Overreliance on symptom quality in diagnosing dizziness: results of a multicenter survey of emergency physicians. *Mayo Clin Proc.* 2007;82:1319-1328.
52. Grewal K, Austin PC, Kapral MK, Lu H, Atzema CL. Missed strokes using computed tomography imaging in patients with vertigo: population-based cohort study. *Stroke.* 2015;46:108-113.
53. Savitz SI, Caplan LR, Edlow JA. Pitfalls in the diagnosis of cerebellar infarction. *Acad Emerg Med.* 2007;14:63-68.
54. Newton EH. Addressing overuse in emergency medicine: evidence of a role for greater patient engagement. *Clin Exp Emerg Med.* 2017;4:189-200.
55. Fatovich DM. The inverted U curve and emergency medicine: Overdiagnosis and the law of unintended consequences. *Emerg Med Australas.* 2016;28:480-482.
56. Hoffman JR, Kanzaria HK. Intolerance of error and culture of blame drive medical excess. *BMJ.* 2014;349:g5702.
57. Kachalia A, Gandhi TK, Puopolo AL, et al. Missed and delayed diagnoses in the emergency department: a study of closed malpractice claims from 4 liability insurers. *Ann Emerg Med.* 2007;49:196-205.
58. Lateef F. Patient expectations and the paradigm shift of care in emergency medicine. *J Emerg Trauma Shock.* 2011;4:163-167.
59. Edlow BL, Hurwitz S, Edlow JA. Diagnosis of DWI-negative acute ischemic stroke: a meta-analysis. *Neurology.* 2017;89:256-262.
60. Choi JH, Kim HW, Choi KD, et al. Isolated vestibular syndrome in posterior circulation stroke: frequency and involved structures. *Neurol Clin Pract.* 2014;4:410-418.

61. Nham B, Reid N, Bein K, et al. Capturing vertigo in the emergency room: three tools to double the rate of diagnosis. *J Neurol*. 2022;269:294-306.
62. Saber Tehrani AS, Kattah JC, Mantokoudis G, et al. Small strokes causing severe vertigo: frequency of false-negative MRIs and non-lacunar mechanisms. *Neurology*. 2014;83:169-173.
63. Dmitriev C, Regis A, Bodunde O, et al. Diagnostic accuracy of the HINTS exam in an emergency department: a retrospective chart review. *Acad Emerg Med*. 2021;28:387-393.
64. McDowell T, Moore F. The under-utilization of the head impulse test in the emergency department. *Can J Neurol Sci*. 2016;43:398-401.
65. Ohle R, Montpellier RA, Marchadier V, et al. Can emergency physicians accurately rule out a central cause of vertigo using the HINTS examination? A systematic review and meta-analysis. *Acad Emerg Med*. 2020;27:887-896.
66. Vanni S, Nazerian P, Casati C, et al. Can emergency physicians accurately and reliably assess acute vertigo in the emergency department? *Emerg Med Australas*. 2015;27:126-131.
67. Bhattacharyya N, Gubbels SP, Schwartz SR, et al. Clinical practice guideline: benign paroxysmal positional vertigo (update). *Otolaryngol Head Neck Surg*. 2017;156:S1-S47.
68. Fife TD, Iverson DJ, Lempert T, et al. Practice parameter: therapies for benign paroxysmal positional vertigo (an evidence-based review): report of the quality standards Subcommittee of the American Academy of neurology. *Neurology*. 2008;70:2067-2074.
69. Abbott J, Tomassen S, Lane L, Bishop K, Thomas N. Assessment for benign paroxysmal positional vertigo in medical patients admitted with falls in a district general hospital. *Clin Med (Lond)*. 2016;16:335-338.
70. Bashir K, Abid AR, Felaya A, Masood M, Ahmad HA, Cameron P. Continuing lack of the diagnosis of benign paroxysmal positional vertigo in a tertiary care emergency department. *Emerg Med Australas*. 2015;27:378-379.
71. Kerber KA, Damschroder L, McLaughlin T, et al. Implementation of evidence-based practice for benign paroxysmal positional vertigo in the emergency department: a stepped-wedge randomized trial. *Ann Emerg Med*. 2020;75:459-470.
72. Kerber KA, Helmchen C. Benign paroxysmal positional vertigo: new opportunities but still old challenges. *Neurology*. 2012;78:154-156.
73. Polensek SH, Tusa R. Unnecessary diagnostic tests often obtained for benign paroxysmal positional vertigo. *Med Sci Monit*. 2009;15:MT89-MT94.
74. Do YK, Kim J, Park CY, Chung MH, Moon IS, Yang HS. The effect of early canalith repositioning on benign paroxysmal positional vertigo on recurrence. *Clin Exp Otorhinolaryngol*. 2011;4:113-117.
75. Neely P, Patel H, Wellings T. Benign paroxysmal positional vertigo in the emergency department: an observational study of an Australian regional hospital's acute clinical practice. *Emerg Med Australas*. 2021;33:1082-1087.
76. Li D, Cheng D, Yang W, et al. Current therapies in patients with posterior Semicircular Canal BPPV, a systematic review and network meta-analysis. *Otol Neurotol*. 2022;43:421-428.
77. Eagles D, Stiell IG, Clement CM, et al. International survey of emergency physicians' priorities for clinical decision rules. *Acad Emerg Med*. 2008;15:177-182.
78. Finnerty NM, Rodriguez RM, Carpenter CR, et al. Clinical decision rules for diagnostic imaging in the emergency department: a research agenda. *Acad Emerg Med*. 2015;22:1406-1416.
79. Carpenter CR, Morrill DM, Sundberg E, Tartt K, Upadhye S. Nothing about me without me: GRACE-fully partnering with patients to derive clinical practice guidelines. *Acad Emerg Med*. Forthcoming 2022. doi: 10.1111/acem.14623
80. Alonso-Coello P, Oxman AD, Moberg J, et al. GRADE evidence to decision (EtD) frameworks: a systematic and transparent approach to making well informed healthcare choices. 2: clinical practice guidelines. *BMJ*. 2016;353:i2089.
81. Alonso-Coello P, Schunemann HJ, Moberg J, et al. GRADE evidence to decision (EtD) frameworks: a systematic and transparent approach to making well informed healthcare choices. 1: Introduction. *BMJ*. 2016;353:i2016.
82. Andrews J, Guyatt G, Oxman AD, et al. GRADE guidelines: 14. Going from evidence to recommendations: the significance and presentation of recommendations. *J Clin Epidemiol*. 2013;66:719-725.
83. Andrews JC, Schunemann HJ, Oxman AD, et al. GRADE guidelines: 15. Going from evidence to recommendation-determinants of a recommendation's direction and strength. *J Clin Epidemiol*. 2013;66:726-735.
84. Carpenter CR, Bellolio MF, Upadhye S, Kline JA. Navigating uncertainty with GRACE: Society for Academic Emergency Medicine's guidelines for reasonable and appropriate care in the emergency department. *Acad Emerg Med*. 2021;28:821-825.
85. Richardson WS, Wilson MC, Nishikawa J, Hayward RS. The well-built clinical question: a key to evidence-based decisions. *ACP J Club*. 1995;123:A12-A13.
86. Musey PI Jr, Bellolio F, Upadhye S, et al. Guidelines for reasonable and appropriate care in the emergency department (GRACE): recurrent, low-risk chest pain in the emergency department. *Acad Emerg Med*. 2021;28:718-744.
87. Broder JS, Oliveira JESL, Bellolio F, et al. Guidelines for reasonable and appropriate Care in the Emergency Department 2 (GRACE-2): low-risk, recurrent abdominal pain in the emergency department. *Acad Emerg Med*. 2022;29:526-560.
88. Shah V, Silva LOJ, Farah W, et al. Diagnostic accuracy of physical exam and neuroimaging for dizziness in the emergency department. *Acad Emerg Med*. Forthcoming 2023. doi: 10.1111/acem.14630
89. Shah VP, Oliveira JESL, Farah W, et al. Diagnostic accuracy of neuroimaging in emergency department patients with acute vertigo or dizziness: a systematic review and meta-analysis for the guidelines for reasonable and appropriate care in the emergency department. *Acad Emerg Med*. Forthcoming 2023. doi: 10.1111/acem.14561
90. Oliveira J e Silva L, Khoujah D, Naples J, et al. Corticosteroids for patients with acute vestibular neuritis: an evidence synthesis for guidelines for reasonable and appropriate care in the emergency department. *Acad Emerg Med*. Forthcoming 2022. doi: 10.1111/acem.14583
91. Fishman JM, Burgess C, Waddell A. Corticosteroids for the treatment of idiopathic acute vestibular dysfunction (vestibular neuritis). *Cochrane Database Syst Rev*. 2011;CD008607.
92. Leong KJ, Lau T, Stewart V, Canetti EFD. Systematic review and meta-analysis: effectiveness of corticosteroids in treating adults with acute vestibular neuritis. *Otolaryngol Head Neck Surg*. 2021;165:255-266.
93. Hilton MP, Pinder DK. The Epley (canalith repositioning) manoeuvre for benign paroxysmal positional vertigo. *Cochrane Database Syst Rev*. 2014;CD003162.
94. Balshem H, Helfand M, Schunemann HJ, et al. GRADE guidelines: 3. Rating the quality of evidence. *J Clin Epidemiol*. 2011;64:401-406.
95. Guyatt G, Oxman AD, Akl EA, et al. GRADE guidelines: 1. Introduction-GRADE evidence profiles and summary of findings tables. *J Clin Epidemiol*. 2011;64:383-394.
96. Guyatt GH, Oxman AD, Vist G, et al. GRADE guidelines: 4. Rating the quality of evidence—study limitations (risk of bias). *J Clin Epidemiol*. 2011;64:407-415.
97. Schunemann HJ, Mustafa RA, Brozek J, et al. GRADE guidelines: 21 part 1. Study design, risk of bias, and indirectness in rating the certainty across a body of evidence for test accuracy. *J Clin Epidemiol*. 2020;122:129-141.

98. Guyatt GH, Oxman AD, Kunz R, et al. GRADE guidelines: 7. Rating the quality of evidence—inconsistency. *J Clin Epidemiol*. 2011;64:1294-1302.
99. Schunemann HJ, Mustafa RA, Brozek J, et al. GRADE guidelines: 21 part 2. Test accuracy: inconsistency, imprecision, publication bias, and other domains for rating the certainty of evidence and presenting it in evidence profiles and summary of findings tables. *J Clin Epidemiol*. 2020;122:142-152.
100. Guyatt GH, Oxman AD, Kunz R, et al. GRADE guidelines: 8. Rating the quality of evidence—indirectness. *J Clin Epidemiol*. 2011;64:1303-1310.
101. Guyatt GH, Oxman AD, Sultan S, et al. GRADE guidelines: 9. Rating up the quality of evidence. *J Clin Epidemiol*. 2011;64:1311-1316.
102. Schunemann HJ, Mustafa R, Brozek J, et al. GRADE guidelines: 16. GRADE evidence to decision frameworks for tests in clinical practice and public health. *J Clin Epidemiol*. 2016;76:89-98.
103. Guyatt GH, Alonso-Coello P, Schunemann HJ, et al. Guideline panels should seldom make good practice statements: guidance from the GRADE working group. *J Clin Epidemiol*. 2016;80:3-7.
104. Guyatt GH, Schunemann HJ, Djulbegovic B, Akl EA. Guideline panels should not GRADE good practice statements. *J Clin Epidemiol*. 2015;68:597-600.
105. Carpenter CR, e Silva LOJ, Upadhye S, Broder JS, Bellolio F. A candle in the dark: the role of indirect evidence in emergency medicine clinical practice guidelines. *Acad Emerg Med*. 2022;29:674-677.
106. Dmitriev C, Bodunde O, Regis A, et al. The use and misuse of the dix-Hallpike test in the emergency department. *CJEM*. 2021;23:613-616.
107. Newman-Toker DE. Symptoms and signs of neuro-otologic disorders. *Continuum (Minneapolis Minn)*. 2012;18:1016-1040.
108. Bi Y, Cao F. A dynamic nomogram to predict the risk of stroke in emergency department patients with acute dizziness. *Front Neurol*. 2022;13:839042.
109. Chen K, Schneider AL, Llinas RH, Marsh EB. Keep it simple: vascular risk factors and focal exam findings correctly identify posterior circulation ischemia in “dizzy” patients. *BMC Emerg Med*. 2016;16:37.
110. Navi BB, Kamel H, Shah MP, et al. Application of the ABCD2 score to identify cerebrovascular causes of dizziness in the emergency department. *Stroke*. 2012;43:1484-1489.
111. Wang W, Zhang Y, Pan Q, et al. Central nystagmus plus ABCD(2) identifying stroke in acute dizziness presentations. *Acad Emerg Med*. 2021;28:1118-1123.
112. Kerber KA, Meurer WJ, Brown DL, et al. Stroke risk stratification in acute dizziness presentations: a prospective imaging-based study. *Neurology*. 2015;85:1869-1878.
113. von Babo M, De Marchis GM, Sarikaya H, et al. Differences and similarities between spontaneous dissections of the internal carotid artery and the vertebral artery. *Stroke*. 2013;44:1537-1542.
114. Putaala J, Metso AJ, Metso TM, et al. Analysis of 1008 consecutive patients aged 15 to 49 with first-ever ischemic stroke: the Helsinki young stroke registry. *Stroke*. 2009;40:1195-1203.
115. Ammar H, Govindu R, Fouda R, Zohdy W, Supsupin E. Dizziness in a community hospital: central neurological causes, clinical predictors, and diagnostic yield and cost of neuroimaging studies. *J Community Hosp Intern Med Perspect*. 2017;7:73-78.
116. Choi JH, Park MG, Choi SY, et al. Acute transient vestibular syndrome: prevalence of stroke and efficacy of bedside evaluation. *Stroke*. 2017;48:556-562.
117. Lam JM, Siu WS, Lam TS, Cheung NK, Graham CA, Rainer TH. The epidemiology of patients with dizziness in an emergency department. *Hong Kong J Emerg Med*. 2006;13:133-139.
118. Machner B, Choi JH, Trillenber P, Heide W, Helmchen C. Risk of acute brain lesions in dizzy patients presenting to the emergency room: who needs imaging and who does not? *J Neurol*. 2020;267:126-135.
119. Ozakin E, Coskun F, Sarac S, Karli Oguz K, Bozkurt S. Value of magnetic resonance imaging and audiology in the emergency department differential diagnosis of peripheral and central vertigo. *Turk Klin J Med Sci*. 2012;32:1-6.
120. Limapichart T, Techawantochande A. Incidence and predicting factors of cerebellar stroke in patients with acute vestibular syndrome in Songklanagarind emergency department: a preliminary study. *J Med Assoc Thailand*. 2018;101:371-381.
121. Mandge V, Palaodimos L, Lai Q, et al. Predictors of vertigo in the emergency department: the preved study. *J Stroke Cerebrovasc Dis*. 2020;29:105043.
122. Thabet E. Evaluation of patients with acute vestibular syndrome. *Eur Arch Otorhinolaryngol*. 2008;265:341-349.
123. Ling X, Sang W, Shen B, Li K, Si L, Yang X. Diagnostic value of eye movement and vestibular function tests in patients with posterior circulation infarction. *Acta Otolaryngol*. 2019;139:135-145.
124. Ozono Y, Kitahara T, Fukushima M, et al. Differential diagnosis of vertigo and dizziness in the emergency department. *Acta Otolaryngol*. 2014;134:140-145.
125. Pavlin-Premrl D, Waterston J, McGuigan S, et al. Importance of spontaneous nystagmus detection in the differential diagnosis of acute vertigo. *J Clin Neurosci*. 2014;22:504-507.
126. Jo S, Jeong T, Lee JB, Jin Y, Yoon J, Park B. Incidence of acute cerebral infarction or space occupying lesion among patients with isolated dizziness and the role of D-dimer. *PLoS One*. 2019;14:e0214661.
127. Nam GS, Shin HJ, Kang JJ, Lee NR, Oh SY. Clinical implication of corrective saccades in the video head impulse test for the diagnosis of posterior inferior cerebellar artery infarction. *Front Neurol*. 2021;12:605040.
128. Perloff MD, Patel NS, Kase CS, Oza AU, Voetsch B, Romero JR. Cerebellar stroke presenting with isolated dizziness: brain MRI in 136 patients. *Am J Emerg Med*. 2017;35:1724-1729.
129. Martin-Schild S, Albright KC, Tanksley J, et al. Zero on the NIHSS does not equal the absence of stroke. *Ann Emerg Med*. 2011;57:42-45.
130. Badihian S, Zee DS, Carey JP, et al. Ataxia Is more Sensitive for Stroke than ABCD2 Vasular Risk or NIH Stroke Scale in Acute Vertigo; 2022.
131. Calic Z, Nham B, Bradshaw AP, et al. Separating posterior-circulation stroke from vestibular neuritis with quantitative vestibular testing. *Clin Neurophysiol*. 2020;131:2047-2055.
132. Carmona S, Martinez C, Zalazar G, et al. The diagnostic accuracy of truncal ataxia and HINTS as cardinal signs for acute vestibular syndrome. *Front Neurol*. 2016;7:125.
133. Chen L, Lee W, Chambers BR, Dewey HM. Diagnostic accuracy of acute vestibular syndrome at the bedside in a stroke unit. *J Neurol*. 2011;258:855-861.
134. Lemos J, Martins AI, Duque C, Pimentel S, Nunes C, Goncalves AF. Positional testing in acute vestibular syndrome: a transversal and longitudinal study. *Otol Neurotol*. 2019;40:e119-e129.
135. Mantokoudis G, Korda A, Zee DS, et al. Bruns' nystagmus revisited: a sign of stroke in patients with the acute vestibular syndrome. *Eur J Neurol*. 2021;28:2971-2979.
136. Newman-Toker DE, Kerber KA, Hsieh YH, et al. HINTS outperforms ABCD2 to screen for stroke in acute continuous vertigo and dizziness. *Acad Emerg Med*. 2013;20:986-996.
137. Sankalia D, Kothari S, Phalgune DS. Diagnosing stroke in acute vertigo: sensitivity and specificity of HINTS battery in Indian population. *Neurol India*. 2021;69:97-101.
138. Okada M, Nakagawa Y, Inokuchi S. Out-of-hospital scaling to recognize central vertigo. *Tokai J Exp Clin Med*. 2012;37:71-74.
139. Batuecas-Caletrio A, Yanez-Gonzalez R, Sanchez-Blanco C, et al. Peripheral vertigo versus central vertigo. Application of the HINTS protocol. *Rev Neurol*. 2014;59:349-353.

140. Korda A, Zamaro E, Wagner F, et al. Acute vestibular syndrome: is skew deviation a central sign? *J Neurol*. 2022;269:1396-1403.
141. Newman-Toker DE, Saber Tehrani AS, Mantokoudis G, et al. Quantitative video-oculography to help diagnose stroke in acute vertigo and dizziness: toward an ECG for the eyes. *Stroke*. 2013;44:1158-1161.
142. Deluca C, Moretto G, Di Matteo A, et al. Ataxia in posterior circulation stroke: clinical-MRI correlations. *J Neurol Sci*. 2011;300:39-46.
143. Nishida K, Usami T, Matsumoto N, Nishikimi M, Takahashi K, Matsui S. Finger-to-nose test improved diagnosis of cerebrovascular events in patients presenting with isolated dizziness in the emergency department. *Nagoya J Med Sci*. 2022;84:621-629.
144. Machner B, Erber K, Choi JH, Trillenber P, Sprenger A, Helmchen C. Usability of the head impulse test in routine clinical practice in the emergency department to differentiate vestibular neuritis from stroke. *Eur J Neurol*. 2021;28:1737-1744.
145. Nazerian P, Bigiarini S, Pecci R, et al. Duplex sonography of vertebral arteries for evaluation of patients with acute vertigo. *Ultrasound Med Biol*. 2018;44:584-592.
146. Quimby AE, Kwok ESH, Lelli D, Johns P, Tse D. Usage of the HINTS exam and neuroimaging in the assessment of peripheral vertigo in the emergency department. *J Otolaryngol Head Neck Surg*. 2018;47:54.
147. Gerlier C, Fels A, Vitaux H, Mousset C, Perugini A, Chatellier G, Ganansia O. Effectiveness and reliability of the four-step STANDING algorithm performed by interns and senior emergency physicians for predicting central causes of vertigo. *Acad Emerg Med*. Forthcoming 2023. doi: 10.1111/acem.14659
148. Edlow JA, Kerber KA. Benign paroxysmal positional vertigo: a practical approach for emergency physicians. *Acad Emerg Med*. Forthcoming 2022. doi: 10.1111/acem.14558
149. Vanni S, Nazerian P, Pecci R, Casati C, Moroni F, Risso M, Ottaviani M, Grifoni S, Vannucchi P. Timing for nystagmus evaluation by STANDING or HINTS in patients with vertigo/dizziness in the emergency department. *Acad Emerg Med*. Forthcoming 2023. doi: 10.1111/acem.14635
150. Vanni S, Nazerian P, Pecci R, et al. Timing for nystagmus evaluation by STANDING or HINTS in patients with vertigo/dizziness in the emergency department. *Acad Emerg Med*. 2022.
151. Hixson HR, Leiva-Salinas C, Sumer S, Patrie J, Xin W, Wintermark M. Utilizing dual energy CT to improve CT diagnosis of posterior fossa ischemia. *J Neuroradiol*. 2016;43:346-352.
152. Karakaya Z, Ozdinc S, Topal F, Korol G, Capaci A, Akyol P. Evaluation of the CCT and MRI results of patients hospitalized after applying to the emergency department with vertigo complaints. *Biomed Res (India)*. 2017;28:1509-1513.
153. Kene MV, Ballard DW, Vinson DR, Rauchwerger AS, Iskin HR, Kim AS. Emergency physician attitudes, preferences, and risk tolerance for stroke as a potential cause of dizziness symptoms. *West J Emerg Med*. 2015;16:768-776.
154. Kohn MA, Carpenter CR, Newman TB. Understanding the direction of bias in studies of diagnostic test accuracy. *Acad Emerg Med*. 2013;20:1194-1206.
155. Fakhraan S, Alhilali L, Branstetter B. Yield of CT angiography and contrast-enhanced MR imaging in patients with dizziness. *AJNR Am J Neuroradiol*. 2013;34:1077-1081.
156. Park MK, Kim K, Lee N, Jung H, Chae S. The usefulness of magnetic resonance imaging for acute isolated vertigo patients in the emergency department. *J Int Adv Otolaryngol*. 2014;10:162-166.
157. Axer H, Grassel D, Bramer D, et al. Time course of diffusion imaging in acute brainstem infarcts. *J Magn Reson Imaging*. 2007;26:905-912.
158. Flossmann E, Rothwell PM. Prognosis of vertebrobasilar transient ischaemic attack and minor stroke. *Brain*. 2003;126:1940-1954.
159. Gulli G, Khan S, Markus HS. Vertebrobasilar stenosis predicts high early recurrent stroke risk in posterior circulation stroke and TIA. *Stroke*. 2009;40:2732-2737.
160. Marquardt L, Kuker W, Chandratheva A, Geraghty O, Rothwell PM. Incidence and prognosis of > or =50% symptomatic vertebral or basilar artery stenosis: prospective population-based study. *Brain*. 2009;132:982-988.
161. IST-3 Collaborative Group, Sandercock P, Wardlaw JM, et al. The benefits and harms of intravenous thrombolysis with recombinant tissue plasminogen activator within 6 h of acute ischaemic stroke (the Third International Stroke Trial [IST-3]): a randomised controlled trial. *Lancet*. 2012;379:2352-2363.
162. Sarikaya H, Arnold M, Engelter ST, et al. Outcomes of intravenous thrombolysis in posterior versus anterior circulation stroke. *Stroke*. 2011;42:2498-2502.
163. Zhu X, Wang N, Lin H, et al. Safety and efficacy of intravenous thrombolytic therapy in patients with acute posterior circulation stroke: a single-center study. *J Stroke Cerebrovasc Dis*. 2020;29:104537.
164. Keselman B, Gdovinova Z, Jatuzis D, et al. Safety and outcomes of intravenous thrombolysis in posterior versus anterior circulation stroke: results from the safe implementation of treatments in stroke registry and meta-analysis. *Stroke*. 2020;51:876-882.
165. Pan Y, Elm JJ, Li H, et al. Outcomes associated with clopidogrel-aspirin use in Minor stroke or transient ischemic attack: a pooled analysis of Clopidogrel in High-Risk Patients With Acute Non-Disabling Cerebrovascular Events (CHANCE) and Platelet-Oriented Inhibition in New TIA and Minor ischemic stroke (POINT) trials. *JAMA Neurol*. 2019;76:1466-1473.
166. Paul NL, Simoni M, Rothwell PM, Oxford VS. Transient isolated brainstem symptoms preceding posterior circulation stroke: a population-based study. *Lancet Neurol*. 2013;12:65-71.
167. Kim HA, Oh EH, Choi SY, et al. Transient vestibular symptoms preceding posterior circulation stroke: a prospective multicenter study. *Stroke*. 2021;52:e224-e228.
168. Dawson J, Merwick A, Webb A, et al. European stroke organisation expedited recommendation for the use of short-term dual antiplatelet therapy early after minor stroke and high-risk TIA. *Eur Stroke J*. 2021;6:CLXXXVII-CLXXCXCI.
169. Kleindorfer DO, Towfighi A, Chaturvedi S, et al. 2021 Guideline for the Prevention of Stroke in Patients with Stroke and Transient Ischemic Attack: a guideline from the American Heart Association/American Stroke Association. *Stroke*. 2021;52:e364-e467.
170. Lip GY, Lim HS. Atrial fibrillation and stroke prevention. *Lancet Neurol*. 2007;6:981-993.
171. Engelter ST, Traenka C, Gensicke H, et al. Aspirin versus anticoagulation in cervical artery dissection (TREAT-CAD): an open-label, randomised, non-inferiority trial. *Lancet Neurol*. 2021;20:341-350.
172. Markus HS, Levi C, King A, Madigan J, Norris J. Cervical artery dissection in stroke study I. antiplatelet therapy vs anticoagulation therapy in cervical artery dissection: the Cervical Artery Dissection in Stroke Study (CADISS) randomized clinical trial final results. *JAMA Neurol*. 2019;76:657-664.
173. Edlow JA, Newman-Toker DE, Savitz SI. Diagnosis and initial management of cerebellar infarction. *Lancet Neurol*. 2008;7:951-964.
174. Wijidicks EF, Sheth KN, Carter BS, et al. Recommendations for the management of cerebral and cerebellar infarction with swelling: a statement for healthcare professionals from the American Heart Association/American Stroke Association. *Stroke*. 2014;45:1222-1238.
175. Brenner DJ, Hall EJ. Computed tomography—an increasing source of radiation exposure. *N Engl J Med*. 2007;357:2277-2284.
176. Smith-Bindman R, Lipson J, Marcus R, et al. Radiation dose associated with common computed tomography examinations and the associated lifetime attributable risk of cancer. *Arch Intern Med*. 2009;169:2078-2086.
177. Burdorf BT. Comparing magnetic resonance imaging and computed tomography machine accessibility among urban and rural county hospitals. *J Public Health Res*. 2021;11(1):2527.

178. Kattah JC, Newman-Toker DE. Video-oculography to guide neuroimaging for dizziness and vertigo. *JAMA Otolaryngol Head Neck Surg.* 2022;148:474-475.
179. Muller-Barna P, Leinweber C, Pfaffenrath J, et al. Identification of stroke and TIA in patients with acute dizziness, vertigo or imbalance in emergency departments of primary care hospitals: early experiences with a network-based telemedical approach. *Front Neurol.* 2022;13:766685.
180. von Martial R, Leinweber C, Hubert N, et al. Feasibility of telemedical HINTS (head impulse-nystagmus-test of skew) evaluation in patients with acute dizziness or vertigo in the emergency department of primary care hospitals. *Front Neurol.* 2021;12:768460.
181. Badihian S, Zee DS, Batazzi A, et al. *Remote Expert Diagnosis by Video-Oculography Is more Accurate than In-Person ED Diagnosis in Acute Vertigo and Dizziness—Preliminary Results of the AVERT Trial.* XXXI Barany Society Meeting; 2022.
182. Korda A, Wimmer W, Zamaro E, et al. Videoculography “HINTS” in acute vestibular syndrome: a prospective study. *Front Neurol.* 2022;13:920357.
183. Easton JD, Saver JL, Albers GW, et al. Definition and evaluation of transient ischemic attack: a scientific statement for healthcare professionals from the American Heart Association/American Stroke Association stroke council; council on cardiovascular surgery and anesthesia; council on cardiovascular radiology and intervention; council on cardiovascular nursing; and the interdisciplinary council on peripheral vascular disease. The American Academy of Neurology affirms the value of this statement as an educational tool for neurologists. *Stroke.* 2009;40:2276-2293.
184. Teggi R, Colombo B, Albera R, et al. Clinical features, familial history, and migraine precursors in patients with definite vestibular migraine: the VM-phenotypes projects. *Headache.* 2018;58:534-544.
185. Lempert T, Olesen J, Furman J, et al. Vestibular migraine: diagnostic criteria (update). *J Vestib Res.* 2022;32:1-6.
186. Lopez-Escamez JA, Carey J, Chung WH, et al. Diagnostic criteria for Meniere's disease. *J Vestib Res.* 2015;25:1-7.
187. Perry JJ, Sivilotti MLA, Emond M, et al. Prospective validation of Canadian TIA score and comparison with ABCD2 and ABCD2i for subsequent stroke risk after transient ischaemic attack: multi-centre prospective cohort study. *BMJ.* 2021;372:n49.
188. Neuhauser H, Lempert T. Vestibular migraine. *Neurol Clin.* 2009;27:379-391.
189. Edlow JA. Managing patients with transient ischemic attack. *Ann Emerg Med.* 2017;71:409-415.
190. Edlow JA. Managing patients with acute episodic dizziness. *Ann Emerg Med.* 2018;72:602-610.
191. Shah KH, Edlow JA. Transient ischemic attack: review for the emergency physician. *Ann Emerg Med.* 2004;43:592-604.
192. Cortel-LeBlanc MA, Sharma M, Cortel-LeBlanc A, et al. Predictors of neurologists confirming or overturning emergency physicians' diagnosis of TIA or stroke. *CJEM.* 2021;23:812-819.
193. Schrock JW, Glasenapp M, Victor A, Losey T, Cydulka RK. Variables associated with discordance between emergency physician and neurologist diagnoses of transient ischemic attacks in the emergency department. *Ann Emerg Med.* 2012;59:19-26.
194. Castle J, Mlynash M, Lee K, et al. Agreement regarding diagnosis of transient ischemic attack fairly low among stroke-trained neurologists. *Stroke.* 2010;41:1367-1370.
195. Markus HS, van der Worp HB, Rothwell PM. Posterior circulation ischaemic stroke and transient ischaemic attack: diagnosis, investigation, and secondary prevention. *Lancet Neurol.* 2013;12:989-998.
196. Searls DE, Pazdera L, Korbel E, Vysata O, Caplan LR. Symptoms and signs of posterior circulation ischemia in the New England Medical Center Posterior Circulation Registry. *Arch Neurol.* 2012;69:346-351.
197. Gulli G, Markus HS. The use of FAST and ABCD2 scores in posterior circulation, compared with anterior circulation, stroke and transient ischemic attack. *J Neurol Neurosurg Psychiatry.* 2012;83:228-229.
198. Tuna MA, Rothwell PM, Oxford VS. Diagnosis of non-consensus transient ischaemic attacks with focal, negative, and non-progressive symptoms: population-based validation by investigation and prognosis. *Lancet.* 2021;397:902-912.
199. Wang J, Wu J, Liu R, Gao F, Hu H, Yin X. The ABCD2 score is better for stroke risk prediction after anterior circulation TIA compared to posterior circulation TIA. *Int J Neurosci.* 2015;125:50-55.
200. Gottesman RF, Sharma P, Robinson KA, et al. Clinical characteristics of symptomatic vertebral artery dissection: a systematic review. *Neurologist.* 2012;18:245-254.
201. Dyken ML, Conneally M, Haerer AF, et al. Cooperative study of hospital frequency and character of transient ischemic attacks. I. Background, organization, and clinical survey. *JAMA.* 1977;237:882-886.
202. Savitz SI, Caplan LR. Vertebrobasilar disease. *N Engl J Med.* 2005;352:2618-2626.
203. Lempert T. Recurrent spontaneous attacks of dizziness. *Continuum (Minneapolis).* 2012;18:1086-1101.
204. Blasberg TF, Wolf L, Henke C, Lorenz MW. Isolated transient vertigo: posterior circulation ischemia or benign origin? *BMC Neurol.* 2017;17:111.
205. Amarenco P, Labreuche J, Lavalée PC. Patients with transient ischemic attack with ABCD2 <4 can have similar 90-day stroke risk as patients with transient ischemic attack with ABCD2 ≥4. *Stroke.* 2012;43:863-865.
206. Schrock JW, Victor A, Losey T. Can the ABCD2 risk score predict positive diagnostic testing for emergency department patients admitted for transient ischemic attack? *Stroke.* 2009;40:3202-3205.
207. Douglas VC, Johnston CM, Elkins J, Sidney S, Gress DR, Johnston SC. Head computed tomography findings predict short-term stroke risk after transient ischemic attack. *Stroke.* 2003;34:2894-2898.
208. Tabuas-Pereira M, Sargento-Freitas J, Isidoro L, et al. Neurosonology accuracy for isolated acute vestibular syndromes. *J Ultrasound Med.* 2017;36:2545-2550.
209. Khan S, Rich P, Clifton A, Markus HS. Noninvasive detection of vertebral artery stenosis: a comparison of contrast-enhanced MR angiography, CT angiography, and ultrasound. *Stroke.* 2009;40:3499-3503.
210. Gulli G, Marquardt L, Rothwell PM, Markus HS. Stroke risk after posterior circulation stroke/transient ischemic attack and its relationship to site of vertebrobasilar stenosis: pooled data analysis from prospective studies. *Stroke.* 2013;44:598-604.
211. Lavalée PC, Meseguer E, Abboud H, et al. A transient ischaemic attack clinic with round-the-clock access (SOS-TIA): feasibility and effects. *Lancet Neurol.* 2007;6:953-960.
212. Rothwell PM, Giles MF, Chandratheva A, et al. Effect of urgent treatment of transient ischaemic attack and minor stroke on early recurrent stroke (EXPRESS study): a prospective population-based sequential comparison. *Lancet.* 2007;370:1432-1442.
213. Luengo-Fernandez R, Li L, Silver L, Gutnikov S, Beddows NC, Rothwell PM. Long-term impact of urgent secondary prevention after transient ischemic attack and minor stroke: ten-year follow-up of the EXPRESS study. *Stroke.* 2022;53:488-496.
214. Amarenco P. Transient ischemic attack. *N Engl J Med.* 2020;382:1933-1941.
215. Giles MF, Rothwell PM. Risk of stroke early after transient ischaemic attack: a systematic review and meta-analysis. *Lancet Neurol.* 2007;6:1063-1072.
216. Agrawal Y, Carey JP, Della Santina CC, Schubert MC, Minor LB. Disorders of balance and vestibular function in US adults: data

- from the National Health and nutrition examination survey, 2001–2004. *Arch Intern Med*. 2009;169:938–944.
217. Huang RJ, Smith SL, Brezina L, Riska KM. A comparison of falls and dizziness handicap by vestibular diagnosis. *Am J Audiol*. 2021;30:1048–1057.
 218. Berger ZD, Brito JP, Ospina NS, et al. Patient centred diagnosis: sharing diagnostic decisions with patients in clinical practice. *BMJ*. 2017;359:j4218.
 219. Lawson J, Johnson I, Bamiou DE, Newton JL. Benign paroxysmal positional vertigo: clinical characteristics of dizzy patients referred to a falls and syncope unit. *QJM*. 2005;98:357–364.
 220. Lindell E, Finizia C, Johansson M, Karlsson T, Nilson J, Magnusson M. Asking about dizziness when turning in bed predicts examination findings for benign paroxysmal positional vertigo. *J Vestib Res*. 2018;28:339–347.
 221. van Dam VS, Maas B, Schermer TR, van Benthem PG, Buintjes TD. Two symptoms strongly suggest benign paroxysmal positional vertigo in a dizzy patient. *Front Neurol*. 2020;11:625776.
 222. Choi JH, Seo JD, Kim MJ, et al. Vertigo and nystagmus in orthostatic hypotension. *Eur J Neurol*. 2015;22:648–655.
 223. Chase M, Goldstein JN, Selim MH, et al. A prospective pilot study of predictors of acute stroke in emergency department patients with dizziness. *Mayo Clin Proc*. 2014;89:173–180.
 224. von Brevern M, Bertholon P, Brandt T, et al. Benign paroxysmal positional vertigo: Diagnostic criteria. *J Vestib Res*. 2015;25:105–117.
 225. Kerber KA, Morgenstern LB, Meurer WJ, et al. Nystagmus assessments documented by emergency physicians in acute dizziness presentations: a target for decision support? *Acad Emerg Med*. 2011;18:619–626.
 226. Korda A, Zee DS, Wyss T, et al. Impaired fixation suppression of horizontal vestibular nystagmus during smooth pursuit: pathophysiology and clinical implications. *Eur J Neurol*. 2021;28:2614–2621.
 227. Strupp M, Fischer C, Hanss L, Bayer O. The takeaway Frenzel goggles: a Fresnel-based device. *Neurology*. 2014;83:1241–1245.
 228. Bashir K, Rauf L, Yousuf A, Anjum S, Bashir MT, Elmoheen A. Teaching benign paroxysmal positional vertigo to emergency medicine residents by using Gagne's nine steps of instructional design. *Adv Med Educ Pract*. 2021;12:1223–1227.
 229. Meurer WJ, Johnson P, Brown D, et al. An educational intervention for acute dizziness care: a randomized. *Vignette-Based Study Otol Neurotol*. 2019;40:e830–e8.
 230. Sandlund MG, Diamant A, Granasen G, Salzer J. Effectiveness of care in acute dizziness presentations. *Eur Arch Otorhinolaryngol*. 2019;276:2389–2396.
 231. Kerber KA, Forman J, Damschroder L, et al. Barriers and facilitators to ED physician use of the test and treatment for BPPV. *Neurol Clin Pract*. 2017;7:214–224.
 232. Kim JS, Zee DS. Clinical practice. Benign paroxysmal positional vertigo. *N Engl J Med*. 2014;370:1138–1147.
 233. Carnevale C, Til Perez G, Arancibia Tagle D, Tomas Barberan M, Sarria EP. Identification of factors related to cases of benign paroxysmal positional vertigo refractory to Canalicular repositioning maneuvers and evaluation of the need for magnetic resonance imaging in their management: retrospective analysis of a series of 176 cases. *Int Arch Otorhinolaryngol*. 2019;23:196–202.
 234. De Schutter E, Adham ZO, Kattah JC. Central positional vertigo: A clinical-imaging study. *Prog Brain Res*. 2019;249:345–360.
 235. Joshi P, Mossman S, Luis L, Luxon LM. Central mimics of benign paroxysmal positional vertigo: an illustrative case series. *Neurol Sci*. 2020;41:263–269.
 236. Tan F, Bartels C, Walsh RM. Our experience with 500 patients with benign paroxysmal positional vertigo: Reexploring aetiology and re-evaluating MRI investigation. *Auris Nasus Larynx*. 2018;45:248–253.
 237. Kim C, Jeong H, Shin J. Incidence of idiopathic benign paroxysmal positional vertigo subtype by hospital visit type: experience of a single center tertiary referral center. *J Laryngol Otol*. 2022;137(1):57–60.
 238. Martens C, Goplen FK, Aasen T, Nordfalk KF, Nordahl SHG. Dizziness handicap and clinical characteristics of posterior and lateral canal BPPV. *Eur Arch Otorhinolaryngol*. 2019;276:2181–2189.
 239. van den Broek EM, van der Zaag-Loonen HJ, Buintjes TD. Systematic review: efficacy of Gufoni maneuver for treatment of Lateral Canal benign paroxysmal positional vertigo with geotropic nystagmus. *Otolaryngol Head Neck Surg*. 2014;150:933–938.
 240. McDonnell MN, Hillier SL. Vestibular rehabilitation for unilateral peripheral vestibular dysfunction. *Cochrane Database Syst Rev*. 2015;1:CD005397.
 241. Oliveira JESL, Khoujah D, Naples JG, et al. Corticosteroids for patients with vestibular neuritis: an evidence synthesis for guidelines for reasonable and appropriate care in the emergency department. *Acad Emerg Med*. Forthcoming 2022. doi: 10.1111/acem.14583
 242. Arshad Q, Seemungal BM. Age-related vestibular loss: current understanding and future research directions. *Front Neurol*. 2016;7:231.
 243. Elwyn G, Frosch D, Thomson R, et al. Shared decision making: a model for clinical practice. *J Gen Intern Med*. 2012;27:1361–1367.
 244. Strupp M, Magnusson M. Acute unilateral vestibulopathy. *Neurol Clin*. 2015;33:669–685.
 245. Cho H, Myung J, Suh HS, Kang HY. Antihistamine use and the risk of injurious falls or fracture in elderly patients: a systematic review and meta-analysis. *Osteoporos Int*. 2018;29:2163–2170.
 246. By the American Geriatrics Society Beers Criteria® Update Expert Panel. American Geriatrics Society 2018 updated AGS Beers Criteria® for potentially inappropriate medication use in older adults. *J Am Geriatr Soc*. 2019;2019(67):674–694.
 247. Sjogren J, Magnusson M, Tjernstrom F, Karlberg M. Steroids for acute vestibular Neuritis—the earlier the treatment, the better the outcome? *Otol Neurotol*. 2019;40:372–374.
 248. Froehling DA, Bowen JM, Mohr DN, et al. The canalith repositioning procedure for the treatment of benign paroxysmal positional vertigo: a randomized controlled trial. *Mayo Clin Proc*. 2000;75:695–700.
 249. Munoz JE, Miklea JT, Howard M, Springate R, Kaczorowski J. Canalith repositioning maneuver for benign paroxysmal positional vertigo: randomized controlled trial in family practice. *Can Fam Physician*. 2007;53:1049–1053, 8.
 250. von Brevern M, Seelig T, Radtke A, Tiel-Wilck K, Neuhauser H, Lempert T. Short-term efficacy of Epley's manoeuvre: a double-blind randomised trial. *J Neurol Neurosurg Psychiatry*. 2006;77:980–982.
 251. Yimtae K, Srirompotong S, Srirompotong S, Sae-Seaw P. A randomized trial of the canalith repositioning procedure. *Laryngoscope*. 2003;113:828–832.
 252. Liang SB, Li L, He HY. The efficacy of Epley procedure for treatment of benign paroxysmal positional vertigo of the posterior semicircular canal. *J Youjiang Medical Univ Nationalities*. 2010;2.
 253. Xie K, Du SW, Gao JJ, Shou GI, Jian HY, Li YZ. Clinical efficacy of Epley procedure for treatment of benign paroxysmal positional vertigo of posterior semicircular canal. *Chinese J Gen Pract*. 2012;12.
 254. von Brevern M, Radtke A, Lezius F, et al. Epidemiology of benign paroxysmal positional vertigo: a population based study. *J Neurol Neurosurg Psychiatry*. 2007;78:710–715.
 255. Lindell E, Kollen L, Johansson M, et al. Benign paroxysmal positional vertigo, dizziness, and health-related quality of life among older adults in a population-based setting. *Eur Arch Otorhinolaryngol*. 2021;278:1637–1644.
 256. Gamiz MJ, Lopez-Escamez JA. Health-related quality of life in patients over sixty years old with benign paroxysmal positional vertigo. *Gerontology*. 2004;50:82–86.
 257. Lopez-Escamez JA, Gamiz MJ, Fernandez-Perez A, Gomez-Finana M. Long-term outcome and health-related quality of life in benign paroxysmal positional vertigo. *Eur Arch Otorhinolaryngol*. 2005;262:507–511.

258. Lopez-Escamez JA, Gamiz MJ, Fernandez-Perez A, Gomez-Finana M, Sanchez-Canet I. Impact of treatment on health-related quality of life in patients with posterior canal benign paroxysmal positional vertigo. *Otol Neurotol*. 2003;24:637-641.
259. Oghalai JS, Manolidis S, Barth JL, Stewart MG, Jenkins HA. Unrecognized benign paroxysmal positional vertigo in elderly patients. *Otolaryngol Head Neck Surg*. 2000;122:630-634.
260. Liao WL, Chang TP, Chen HJ, Kao CH. Benign paroxysmal positional vertigo is associated with an increased risk of fracture: a population-based cohort study. *J Orthop Sports Phys Ther*. 2015;45:406-412.
261. Gananca FF, Gazzola JM, Gananca CF, Caovilla HH, Gananca MM, Cruz OL. Elderly falls associated with benign paroxysmal positional vertigo. *Braz J Otorhinolaryngol*. 2010;76:113-120.
262. Jumani K, Powell J. Benign paroxysmal positional vertigo: management and its impact on falls. *Ann Otol Rhinol Laryngol*. 2017;126:602-605.
263. Reinink H, Wegner I, Stegeman I, Grolman W. Rapid systematic review of repeated application of the epley maneuver for treating posterior BPPV. *Otolaryngol Head Neck Surg*. 2014;151:399-406.
264. Sharif S, Khoujah D, Greer A, Naples J, Upadhye S, Edlow JA. Vestibular suppressants for benign paroxysmal positional vertigo: a systematic review and meta-analysis of randomized controlled trials. *Acad Emerg Med*. Forthcoming 2023. doi: [10.1111/acem.14608](https://doi.org/10.1111/acem.14608)
265. Hunter BR, Wang AZ, Bucca AW, et al. Efficacy of benzodiazepines or antihistamines for patients with acute vertigo: a systematic review and meta-analysis. *JAMA Neurol*. 2022;79:846-855.
266. Edlow JA. Acute dizziness: a personal journey through a paradigm shift. *Acad Emerg Med*. Forthcoming 2023. doi: [10.1111/acem.14559](https://doi.org/10.1111/acem.14559)

SUPPORTING INFORMATION

Additional supporting information can be found online in the Supporting Information section at the end of this article.

How to cite this article: Edlow JA, Carpenter C, Akhter M, et al. Guidelines for reasonable and appropriate care in the emergency department 3 (GRACE-3): Acute dizziness and vertigo in the emergency department. *Acad Emerg Med*. 2023;30:442-486. doi:[10.1111/acem.14728](https://doi.org/10.1111/acem.14728)



PennState Health

Emergency Medicine Residency Program Director

Penn State Health Milton S. Hershey Medical Center is seeking an Emergency Medicine Residency Program Director to join our exceptional academic team located in Hershey, PA. This is an excellent opportunity to join an outstanding academic program with a national reputation and impact the lives of our future Emergency Medicine physicians.

What We're Offering:

- Competitive salary and benefits
- Sign-On Bonus
- Relocation Assistance
- Leadership for Emergency Medicine Residency Program
- Comprehensive benefit and retirement options

What We're Seeking:

- MD, DO, or foreign equivalent
- BC/BE by ABEM or ABOEM
- Leadership experience
- Outstanding patient care qualities
- Ability to work collaboratively within a diverse academic and clinical environment



FOR MORE INFORMATION PLEASE CONTACT:

Heather Peffley, PHR CPRP
Physician Recruiter
Penn State Health

Email: hpeffley@pennstatehealth.psu.edu
Website: careers.pennstatehealth.org

What the Area Offers:

Located in a safe family-friendly setting, Hershey, PA, our local neighborhoods boast a reasonable cost of living whether you prefer a more suburban setting or thriving city rich in theater, arts, and culture. Known as the home of the Hershey chocolate bar, Hershey's community is rich in history and offers an abundant range of outdoor activities, arts, and diverse experiences. We're conveniently located within a short distance to major cities such as Philadelphia, Pittsburgh, NYC, Baltimore, and Washington DC.