

# Engagement of the Median Glossoepiglottic Fold and Laryngeal View During Emergency Department Intubation

Brian E. Driver, MD\*; Matthew E. Prekker, MD; Richard M. Levitan, MD; Jeffrey Corajod, MD; Erin Karl, MD; Andrew D. Smith, BS; Robert F. Reardon, MD

\*Corresponding Author. E-mail: [briandriver@gmail.com](mailto:briandriver@gmail.com).

**Study objective:** When using a standard geometry laryngoscope, experts recommend engaging the hyoepiglottic ligament—a ligament deep to the vallecula not visible to the intubator. The median glossoepiglottic fold (hereafter termed midline vallecular fold) is a superficial mucosal structure, visible to the intubator, that lies in the midline of the vallecula. We aimed to determine whether engaging the midline vallecular fold with a standard geometry blade tip during orotracheal intubation improved laryngeal visualization.

**Methods:** We reviewed laryngoscopic videos from intubations by emergency physicians using standard geometry video laryngoscopes over a 2-year period. Two reviewers watched each video and recorded whether the blade tip engaged the midline vallecular fold (obscured the fold with the blade tip) and the best modified Cormack-Lehane grade and percent of glottic opening obtained. We compared laryngeal views in the presence and absence of fold engagement.

**Results:** We analyzed 183 discrete laryngoscopic episodes, including 113 instances in which the midline vallecular fold was engaged and 70 instances in which the fold was not engaged. The proportion with a Cormack-Lehane grade 1 or 2a was higher with fold engagement (96%) than without (87%) (absolute difference 9% [95% confidence interval (CI) 1 to 18%]). Ordinal logistic regression demonstrated that midline vallecular fold engagement was associated with a more favorable Cormack-Lehane grade (odds ratio 2.1 [95% CI 1.1 to 4.2]). The median percent of glottic opening score was 95% (interquartile range 90 to 100%) with fold engagement and 95% (65 to 100%) without engagement (median difference 0% [95% CI 0 to 5%]).

**Conclusion:** Engaging the midline vallecular fold with the laryngoscope blade tip during orotracheal intubation when using a standard geometry blade was associated with improved laryngeal visualization. [Ann Emerg Med. 2021;■:1-9.]

Please see page XX for the Editor's Capsule Summary of this article.

0196-0644/\$-see front matter

Copyright © 2021 by the American College of Emergency Physicians.

<https://doi.org/10.1016/j.annemergmed.2021.04.024>

## INTRODUCTION

### Background

The Macintosh laryngoscope blade, introduced in 1943, is widely used for both direct laryngoscopy and video laryngoscopy. The best technique for using the Macintosh laryngoscope blade (also referred to as a standard geometry blade) for direct laryngoscopy is well described. However, since the distal tip of the blade and the anatomic structures within the vallecula are not well visualized during direct laryngoscopy, optimal positioning of the blade tip within the vallecula has not been well described. Video laryngoscopy provides visualization of the blade tip and the anatomic structures within the vallecula, allowing detailed study of blade tip position and laryngeal view.

Laryngoscopy technique often determines intubation success or failure. The laryngeal view obtained is strongly associated with intubation success; if a Cormack-Lehane grade 1 or 2 view can be achieved, intubation is usually successful.<sup>1-4</sup> Experts recommend many specific strategies to optimize laryngeal view, including the use of neuromuscular blockade, placing the patient in the ear-to-sternal notch position, head elevation, and external laryngeal manipulation.<sup>5-7</sup>

To indirectly lift the epiglottis to achieve a full laryngeal view when using a standard geometry shaped laryngoscope blade, experts also recommend engaging the tip of the laryngoscope blade with the hyoepiglottic ligament, a ligament deep to the vallecula that is not visible to the intubator. This can be accomplished by

**Editor's Capsule Summary***What is already known on this topic*

Current intubation training does not highlight the midline vallecular fold.

*What question this study addressed*

What is the impact on laryngeal visualization from engaging the laryngoscope blade tip on the midline vallecular fold?

*What this study adds to our knowledge*

In this retrospective video review of 183 laryngoscopies, laryngeal visualization was significantly better in the 113 episodes when the fold was engaged versus the 70 episodes in which it was not (96% versus 87%).

*How this is relevant to clinical practice*

These promising but preliminary findings suggest that simple attention to engaging the midline vallecular fold might improve laryngeal visualization.

placing the blade tip in the epiglottic vallecula, the groove between the tongue and epiglottis, which indirectly lifts the epiglottis upward to expose the larynx. However, optimal blade tip positioning within the vallecula is sometimes difficult to discern, as the hyoepiglottic ligament cannot be seen.

In contrast, the median glossoepiglottic fold (hereafter termed midline vallecular fold), a midline mucosal fold in the vallecula connecting the tongue and the epiglottis that lies superficially to the hyoepiglottic ligament, can be seen when using a video laryngoscope and is a potential target for the tip of the laryngoscope blade (Figures 1 and 2). Anecdotally, placing the blade tip against this fold helps indirectly lift the epiglottis upward. This fold has often been inaccurately referred to as the hyoepiglottic ligament. The midline vallecular fold is poorly visualized during direct laryngoscopy but is often readily identified during video laryngoscopy. To our knowledge, however, there are no clinical data examining the relationship between midline vallecular fold engagement (or, for that matter, hyoepiglottic ligament engagement) and subsequent laryngeal view.

**Study Objectives**

We sought to compare laryngeal view (as measured by modified Cormack-Lehane grade and percent of glottic opening) when the tip of the laryngoscope blade was

engaged with the midline vallecular fold compared to when the blade tip was in the vallecula but not engaged with the fold.

**MATERIALS AND METHODS****Study Design and Setting**

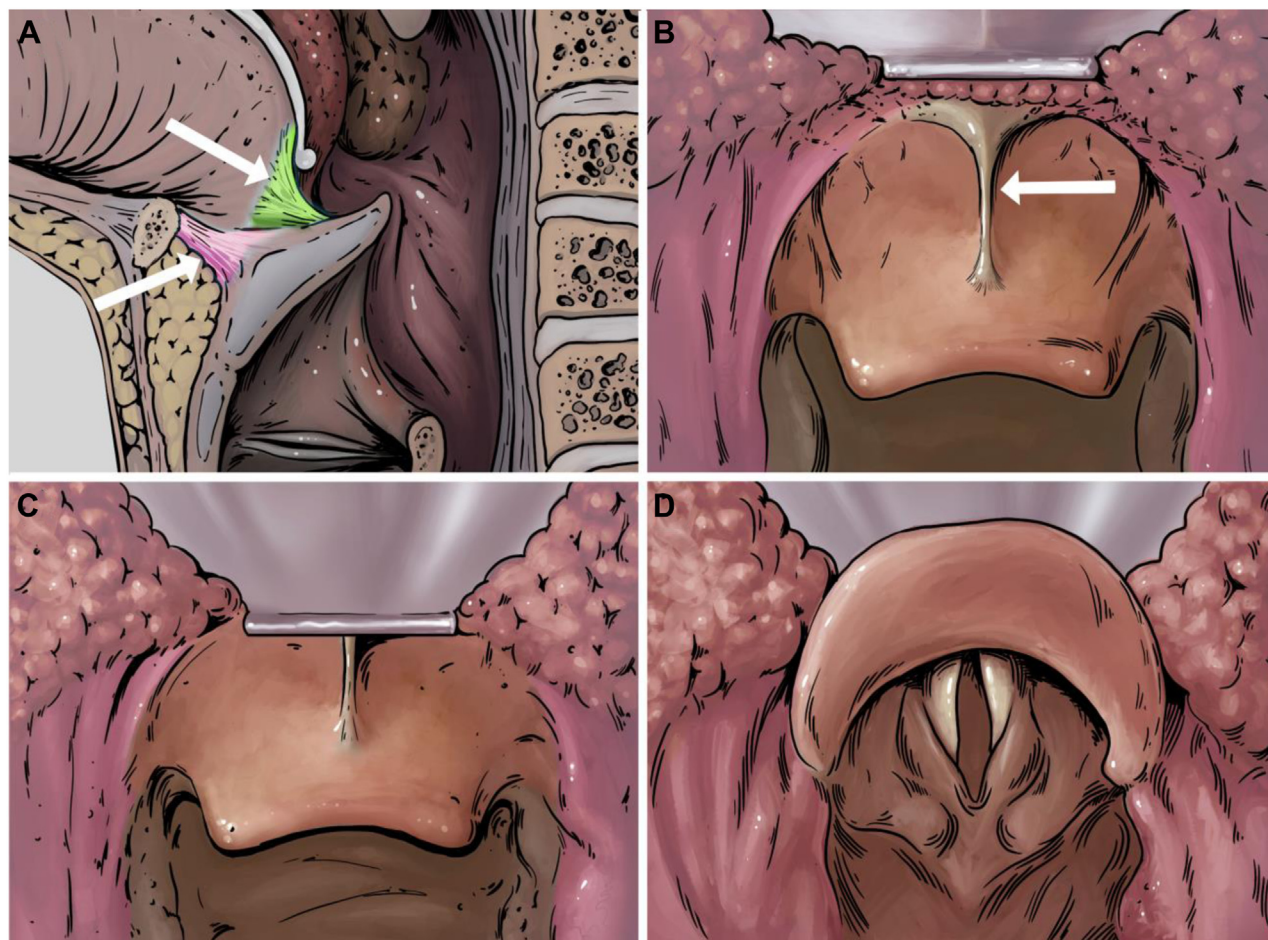We performed a retrospective study of laryngoscopy videos. The study was declared exempt from review by the local institutional review board. This study followed the Strengthening the Reporting of Observational Studies in Epidemiology guidelines.<sup>8</sup>

The study was conducted at Hennepin County Medical Center, in an urban, academic emergency department (ED) with an annual census of approximately 100,000 visits. Approximately 1,000 intubations are performed in this ED annually. All airway management decisions are made and procedures are performed by the treating emergency physicians. Senior emergency medicine residents (postgraduate year 3 and higher) perform the majority of intubations (>85%), with attending supervision; junior residents and attending emergency physicians perform the remainder. More than 90% of intubations are completed with the C-MAC video laryngoscope (Storz CMAC [Karl Storz, Tuttlingen, Germany]) using a standard geometry blade. Secure digital cards are usually available to record videos of emergency intubations, though there is no established protocol for which intubations are recorded. An attending emergency physician uploads videos from the secure digital card onto a single departmental computer, where they are available to search and review.

**Selection of Participants**

We reviewed laryngoscopy videos obtained from standard geometry video laryngoscopes during emergency intubations from January 2016 through December 2017, excluding videos where we could not determine the position of the blade tip due to blood, vomit, or oral secretions. To attempt to estimate the effect of positioning the blade tip on the midline vallecular fold compared to laryngoscopy without fold application, we also excluded videos where the laryngoscopy blade was never placed in the vallecula due to poor technique or placed under the epiglottis (using the technique traditionally reserved for a straight blade). We also excluded videos where it was impossible to determine if the fold was engaged.

The unit of analysis was defined as an instance in the video where the blade was positioned in the vallecula with respect to the midline vallecular fold. For most videos, the blade either engaged the fold the entire time while in the



**Figure 1.** Median glossoepiglottic fold (midline vallecular fold). A, The superficial median glossoepiglottic fold (here, termed midline vallecular fold) is highlighted green (upper arrow). The deeper hyoepiglottic ligament, not visible to the naked eye, is highlighted pink (lower arrow); pressure on the hyoepiglottic ligament also contributes to epiglottic elevation. B, The intubator's view of the fold (arrow), a midline mucosal fold that connects the base of the tongue to the epiglottis, as the blade approaches the vallecula. C, The blade begins to engage the fold, which might help indirectly lift the epiglottis. The intubator must place the tip of the blade deeply into the vallecula and ensure the tip is not too shallow (on the tongue) or too deep (on the epiglottis). D, The laryngeal view after the epiglottis is lifted indirectly. Illustrations courtesy of Hennepin County Medical Center.

vallecula or never engaged it while in the vallecula. However, if a single video contained discrete events where the blade tip was engaged *and* not engaged with the midline vallecular fold while in the vallecula, we analyzed both events as separate instances, one with fold engagement and the other without.

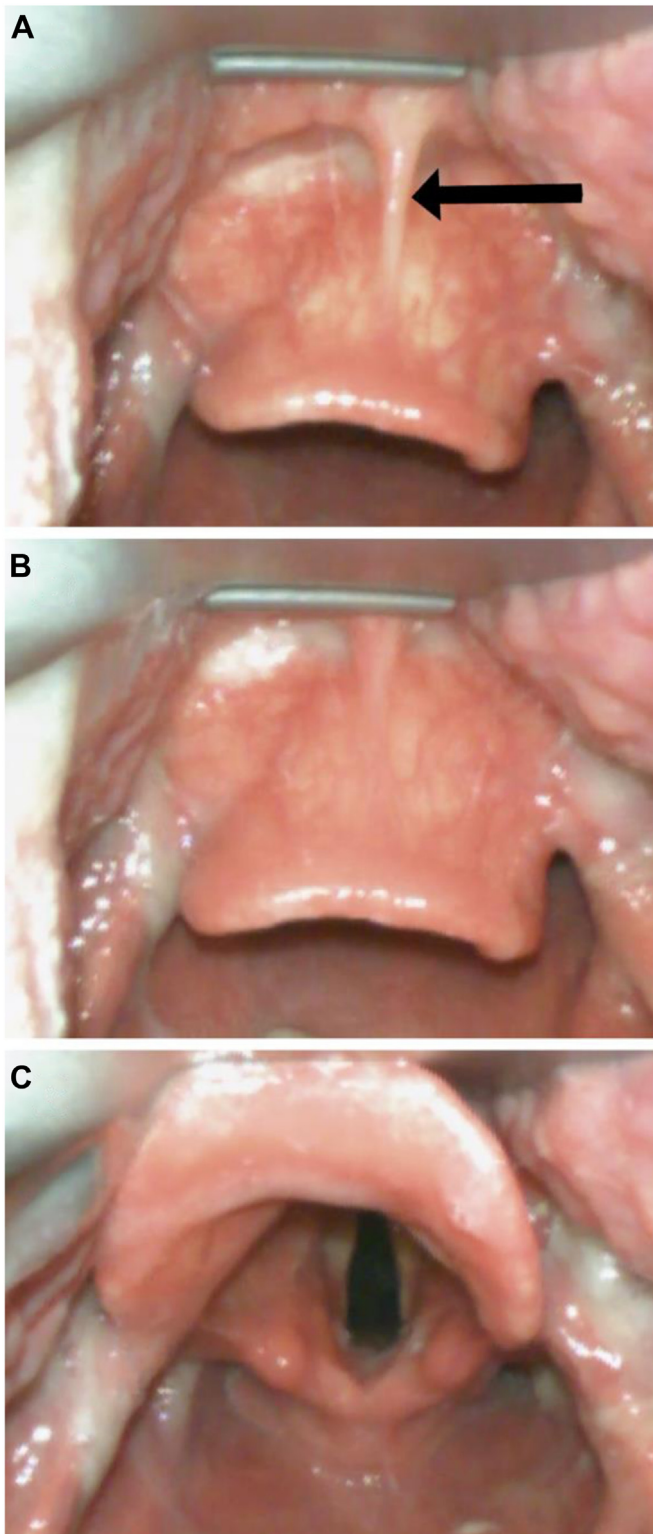
### Methods of Measurement

A senior investigator (BD) trained 2 abstractors to review videos, showed them examples of midline vallecular fold engagement and nonengagement, and reviewed definitions and examples of modified Cormack-Lehane grades and different values for percent of glottic opening. The abstractors were aware that the midline vallecular fold was a main focus of the video review but were blinded to

any underlying hypotheses; they were not told of any anticipated findings or potential benefits of one method versus the other. These 2 abstractors each reviewed every laryngoscopy video and entered data into a standardized form using Research Electronic Data Capture.<sup>9</sup> The initial data collection form was refined after review of the first several videos. The study team met frequently to retrain and answer questions about data collection to ensure uniformity.

The reviewers determined whether the midline vallecular fold was engaged during laryngoscopy and whether the blade was placed in the deepest recess of the vallecula, recording the best modified Cormack-Lehane grade and percent of glottic opening for each laryngoscopy video; they also recorded whether both sides of the epiglottis were lifted symmetrically (ie,





**Figure 2.** Median glossoepiglottic fold (midline vallecular fold) images from video laryngoscopy. This figure parallels Figure 1. A, The intubator's view of the median glossoepiglottic fold (here, termed midline vallecular fold, indicated by the arrow), a midline mucosal fold that connects the base of the tongue to the epiglottis, as the blade approaches the vallecula. B, The

without tilting to the left or right).<sup>2,10,11</sup> Midline vallecular fold engagement was defined as obscuration of the mucosal fold by the blade tip. Blade placement in the deepest recess of the vallecula was defined as blade placement in the deepest possible space between tongue and epiglottis without the blade being too superficial (on the tongue) or too deep (on the epiglottis).

Sometimes, during the course of a single laryngoscope insertion, there were discrete instances in which the fold was both engaged *and* not engaged while the blade tip was in the vallecula; for these, the reviewers recorded the best Cormack-Lehane grade and percent of glottic opening score in each blade position.

Videos with disagreement between the 2 raters for blade position or Cormack-Lehane grade or an absolute difference in percent of glottic opening score >10% (48 videos) were reviewed by an expert reviewer (JC), who provided the final determination.

Because these were unidentified laryngoscopy videos, we were unable to record any other data, including patient characteristics, reason for intubation, or other details of the intubation process.

### Outcomes

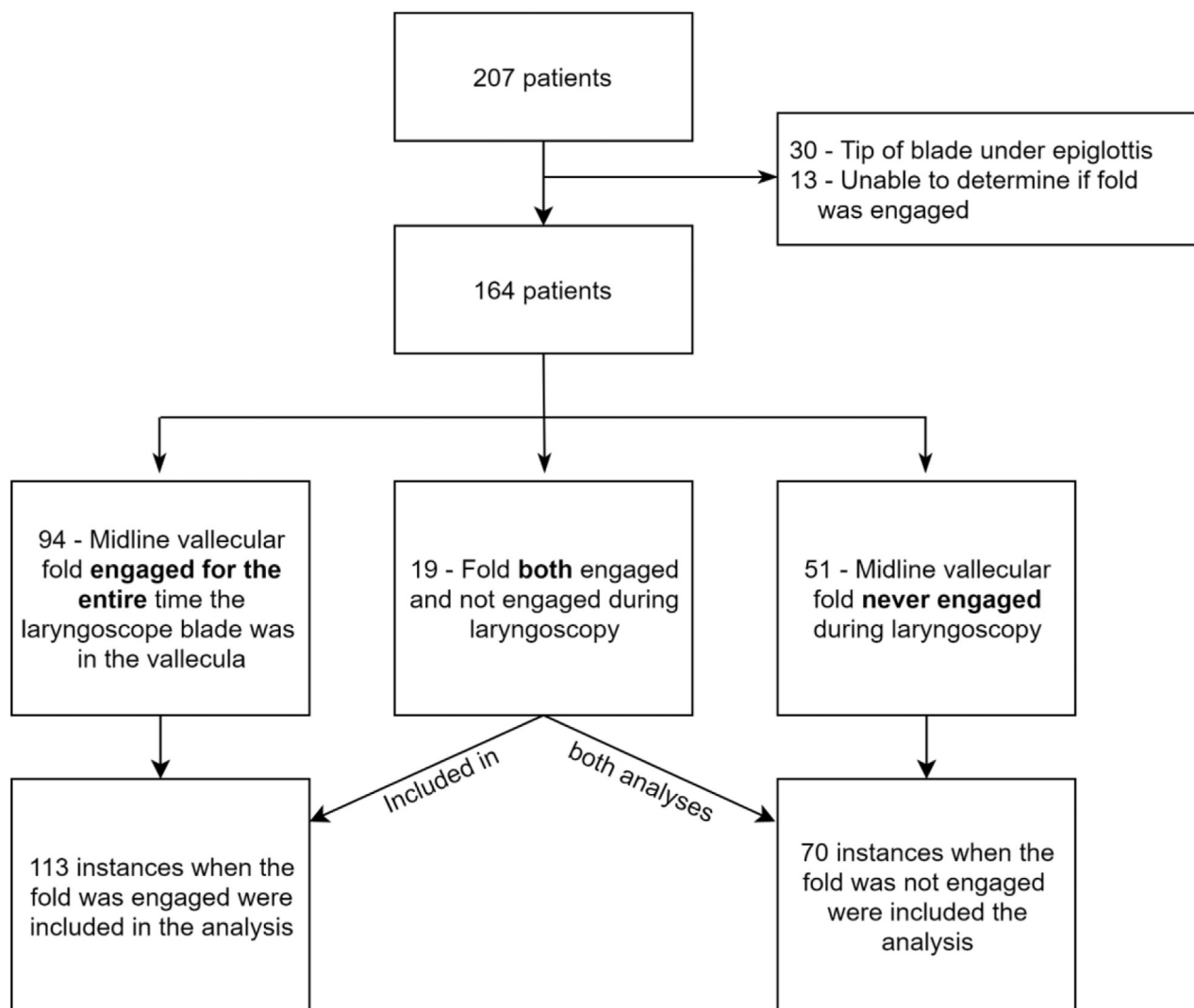
The primary outcome was laryngeal view, as measured by modified Cormack-Lehane grade and percent of glottic opening.

### Data Analysis

Using a pilot data set, we estimated a standard deviation for percent of glottic opening values to be approximately 20%. To detect an absolute difference of 10% in percent of glottic opening between groups with 80% power, an analysis of 128 videos (64 per group) was required. We present counts, proportions, or medians with interquartile ranges, as appropriate, for all measured variables.

To determine if the percent of glottic opening and Cormack-Lehane grade differed between groups defined by midline vallecular fold engagement, we compared the absolute difference in median percent of glottic opening between groups with the associated 95% confidence intervals. We performed ordinal logistic regression with

blade begins to engage the fold, which might help indirectly lift the epiglottis. The intubator must place the tip of the blade deeply into the vallecula and ensure the tip is not too shallow (on the tongue) or too deep (on the epiglottis). C, The laryngeal view after the epiglottis is lifted indirectly. Photos courtesy of Hennepin County Medical Center.



**Figure 3.** Flowchart of videos included and analyzed.

Cormack-Lehane grade as the dependent variable and midline vallecular fold engagement as the independent variable. The Brant test showed that the proportional odds assumption was upheld.

In a post hoc exploratory analysis, we compared laryngeal view for patients who, during a single laryngoscope insertion, had both the midline vallecular fold engaged and not engaged while the blade was in the vallecula. We used Stata (version 15.1; StataCorp, College Station, TX) for data analysis.

## RESULTS

Of the approximately 2,000 patients who were intubated during the study period, there were 207 videos available for review. After excluding 43 videos, there were 164 patients eligible for analysis (Figure 3). From these 164

patients, we analyzed 183 discrete laryngoscopic episodes, including 113 episodes in which the midline vallecular fold was engaged and 70 episodes in which the fold was not engaged.

The Table displays laryngoscopic outcomes for both groups. The blade was seated appropriately, deep in the vallecula, for the vast majority of attempts. A modified Cormack-Lehane grade of 1 or 2a was obtained in 96% of instances in which the midline vallecular fold was engaged, compared to 87% of instances in which the fold was not engaged (absolute difference 9%, 95% confidence interval [CI] 1 to 18%). Ordinal logistic regression demonstrated that engaging the midline vallecular fold was associated with an improved modified Cormack-Lehane grade (odds ratio 2.1 [95% CI 1.1 to 4.2]) versus not engaging the fold.

The median percent of glottic opening score was 0% higher (95% CI 0 to 5%) when the midline vallecular fold

**Table.** Median glossoepiglottic fold engagement and laryngeal view.

Outcome	Midline Vallecular Fold Engaged (n=113)	Midline Vallecular Fold Not Engaged (n=70)	Difference (95% CI)
Percent of glottic opening, median (IQR), %	95 (90-100)	95 (65-100)	0 (0 to 5)
Modified Cormack-Lehane grade 1 or 2a*	109 (96)	61 (87)	9% (1 to 18%)
Best Modified Cormack-Lehane grade during laryngoscopy*			
1	91 (80)	47 (67)	13% (2 to 27%)
2a	18 (16)	14 (20)	-4% (-16 to 7%)
2b	0	2 (3)	-3% (-7 to 1%)
3	4 (4)	5 (7)	-4% (-11 to 3%)
4	0	2 (3)	-3% (-7 to 1%)
Engaged in deepest recess of vallecula†	106 (94)	61 (87)	7% (-2 to 16%)
Epiglottis lifted symmetrically	92 (81)	13 (19)	63% (51 to 74%)

IQR, Interquartile range.

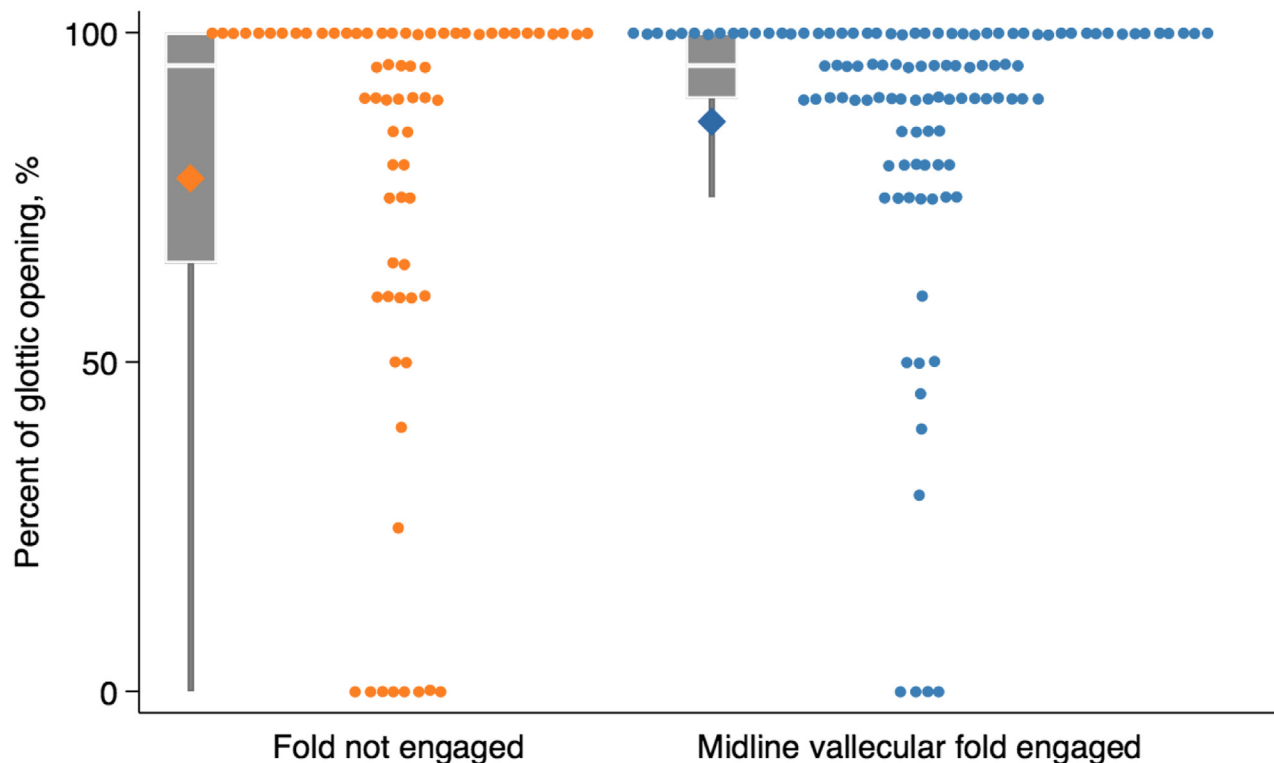
All values are given as number (%) unless otherwise stated. The difference column shows the median difference for percent of glottic opening and the difference in proportions for all remaining variables. The column shows the value for midline vallecular fold engaged minus the fold not engaged. Therefore, a positive value indicates a higher value or proportion for fold engaged, and vice versa.

\*Grade 1: all or most of the glottic opening seen; grade 2a: partial view of the glottic opening; grade 2b: only the posterior portion of the glottis or only arytenoid cartilages are visible; grade 3: only the epiglottis but no portion of the glottis is visible; grade 4: neither the glottis nor the epiglottis can be seen.

†Blade placement in the deepest recess of the vallecula was defined as blade placement in the deepest possible space between tongue and epiglottis without the blade being too superficial (on the tongue) or too deep (on the epiglottis).

was engaged versus not engaged. Figure 4 illustrates the distribution of percent of glottic opening measurements for each laryngoscopic episode. The epiglottis was lifted

symmetrically 81% of the time when the fold was engaged, in contrast to 19% of the time when the fold was not engaged (Table).



**Figure 4.** Percent of glottic opening by midline vallecular fold engagement. This figure shows the percent of glottic opening for each case, stratified by whether the midline vallecular fold was engaged. Diamonds mark the mean values (78% and 87%, respectively). Medians and interquartile ranges are shown in the box plot; the whisker extends to the 10th percentile.

We have included several example videos of midline vallecular fold engagement for review (Videos E1 to E9, available at <http://www.annemergmed.com>). Videos E1 to E3 show examples of engaging the fold. Videos E4 to E6 show examples of asymmetric epiglottic lifting with incomplete laryngeal views when the fold was not engaged. Conversely, Videos E7 and E8 show examples of asymmetric epiglottic lifting with full laryngeal views when the fold was not engaged. Video E9 shows symmetric epiglottic lifting when the fold is engaged and subsequent asymmetric lifting when the blade tip is moved off of the fold.

In an exploratory post hoc analysis, we analyzed 19 patients who had discrete episodes of midline vallecular fold engagement *and* nonengagement during a single course of laryngoscopy. Figure E1 (available at <http://www.annemergmed.com>) shows the modified Cormack-Lehane grades and percent of glottic opening scores in both states. In 15/19 (79%), the percent of glottic opening was unchanged or improved with fold engagement; in 17/19 (89%), the Cormack-Lehane grade was unchanged or improved with fold engagement. There were 2 instances in which switching from fold engagement to not engaging the fold resulted in an improvement from a percent of glottic opening of 0% to 65% and 100%, respectively. In further video review of these cases, the midline vallecular fold appeared inelastic and the blade tip pressure on the fold had no effect on epiglottis position. Moving the blade off of the midline allowed the tip to travel deeper into the vallecula and lift the epiglottis asymmetrically with improvement in laryngeal view. These instances can be viewed in Videos E10 and E11 (available at <http://www.annemergmed.com>).

## LIMITATIONS

This study has several limitations. First, the laryngeal view seen on the video screen does not always correspond to the best line-of-sight view obtained by the operator, which limits the generalizability of our findings when a combined strategy of direct+video laryngoscopy is used.<sup>12</sup> Second, we did not capture the timing or success of intubation attempts; rather, we present evidence for a laryngoscopy maneuver that would benefit from future validation using patient-centered outcome measures. Third, it is possible that engaging the midline vallecular fold is more important in patients with predicted intubation difficulty or vice versa, but we lacked data on patient characteristics to inform questions around heterogeneity of treatment effect. Fourth, this was a convenience sample of video laryngoscope videos, which can introduce bias if it

does not represent the population as a whole. However, there is no reason to think this sample was biased for or against fold engagement, though the sample could have contained more difficult airways than usual, since the intubators chose to record and store them. Fifth, our results are not generalizable to hyperangulated blades, which often require a more panoramic view obtained by placing the blade further away from the larynx, or straight (Miller) blades, which are designed to lift both the epiglottis and tongue rather than seat within the vallecula.<sup>13</sup> Sixth, the analysis of 19 patients who had the fold engaged and not engaged during a single laryngoscope insertion could have other variables that affected laryngeal view, such as lifting force. Thus, this analysis should be viewed as exploratory and requires further verification.

## DISCUSSION

In this retrospective analysis of standard geometry video laryngoscopies, we found that engaging the midline vallecular fold with the tip of the laryngoscope blade was associated with an improved view of the larynx and more symmetric elevation of the epiglottis as compared to not engaging the fold. Since laryngeal view correlates strongly with intubation success, these preliminary data suggest that engaging the midline vallecular fold may potentially be a useful component of optimal laryngoscopy.

To our knowledge, there are no prior human data examining the association between midline vallecular fold engagement during standard geometry laryngoscopy and subsequent laryngeal view or intubation success. In the only related study to our knowledge, Nakao<sup>14</sup> used a bony laryngeal anatomy model, with rubber attaching the hyoid bone and epiglottis and Velcro tape simulating the hyoepiglottic ligament (which is just deep to the midline vallecular fold), to provide evidence of the importance of the hyoepiglottic ligament in laryngeal exposure.

In the present study, it is not clear if the laryngeal view was improved because of engagement of the fold itself or because placing pressure on the fold pushed on the deeper hyoepiglottic ligament. During video review, however, it was clear that the epiglottis often indirectly lifted even with relatively light pressure within the vallecula, indicating that blade position and pressure on mucosal and superficial structures are important and that pressure on the deeper hyoepiglottic ligament, though likely important, is not the only determinant of adequate laryngeal view. Engaging the midline vallecular fold does not necessitate applying a force to the hyoepiglottic ligament and vice versa, though deeply engaging the fold will usually apply force to the



hyoepiglottic ligament. This finer point (ie, what exactly is causing the epiglottis to lift?) is less relevant to the intubating physician, who can target the midline fold that is easily seen when using video laryngoscopy. Other factors not evaluated in this study, such as the amount of force exerted by the operator, the vector of force, and the angle of the blade, also contribute to an optimal laryngeal view; determining the relative contribution of any one factor, including midline vallecular fold engagement, is not feasible in a study of this size and design. Additionally, the median percent of glottic opening of patients *without* fold engagement was quite high (95%), clearly indicating it is possible to achieve good views of the larynx without engaging this midline structure.

Engaging the midline vallecular fold may aid in achieving the best possible view of the larynx, but other practices likely have greater importance in successful intubation (eg, patient positioning, incremental laryngoscope movement to perform epiglottoscopy before laryngeal exposure, external laryngeal manipulation, ensuring adequate tongue sweep for direct laryngoscopy, and tube delivery).<sup>5-7,15,16</sup> In this collection of videos, however, engaging the fold usually resulted in a good laryngeal view and rarely led to a worse view—thus, it could be considered the target for the tip of the laryngoscope. This technique may be especially relevant for those learning laryngoscopy, who should strive to avoid placing the blade too shallowly on the tongue or too deeply, pushing the epiglottis over the laryngeal opening.

This study recorded views obtained by the camera near the tip of the video laryngoscope, which sometimes differ from the views obtained when performing direct laryngoscopy using a line-of-sight view. Available evidence suggests that the video view is almost always the same or better than the direct view.<sup>17-19</sup> Therefore, if engaging the midline vallecular fold improves laryngeal view, this technique should be even more important when performing direct laryngoscopy. However, because the fold is not typically seen when performing direct laryngoscopy, it is more difficult to discern if the fold is engaged. Knowledge of its position from video laryngoscopy will be helpful; the intubator should be able to tell when the blade tip is in the correct position when the epiglottis lifts up symmetrically to reveal the larynx. Many intubators probably already routinely engage the midline vallecular fold, even if they are not aware of it.

The symmetric lifting of the epiglottis when the fold is engaged may contribute to improved laryngeal view, though this is not certain. We have included videos of symmetric and asymmetric epiglottic lifting with both complete and incomplete laryngeal views. In review of

these and other videos, it does seem that the blade engagement with the midline vallecular fold, rather than blade placement near the midline but off of the fold, is commonly the cause of symmetric epiglottic lifting. Symmetric lifting could theoretically ease tube delivery since a broader view of the larynx can be achieved. Conversely, an intubator could use this knowledge to their advantage if a floppy epiglottis is encountered, by moving the tip of the blade off the fold to the right to move the epiglottis to the left (Videos E7 and E8 serve as examples of how this technique might work). Although symmetric epiglottic lifting occurred much more often when the fold was engaged, the significance of this and its association with laryngeal view and eventual success remain unknown. It is possible this is not a key factor in optimizing laryngeal view; this should be elucidated further in future research.

Although achieving the fullest laryngeal view has been associated with easier intubation when using a standard geometry laryngoscope, a deliberately restricted view (defined as a percent of glottic opening of <50%) might improve success when using a hyperangulated video laryngoscope.<sup>2,3,13</sup> Therefore, the present results should not be generalized to hyperangulated video laryngoscopes.

There were 2 instances in which engaging the midline vallecular fold resulted in a worse laryngeal view compared to placing the blade tip off of midline, seemingly because of inelasticity of the fold. This has not been described previously, but it is important. If engaging the fold does not result in an adequate view, the intubator should move the tip off of midline to attempt to engage deeper within the vallecula in order to better lift the epiglottis.

Future research should examine consecutive intubations and adjust for other factors known to be associated with intubation success, which will better explain any relationship between fold engagement with laryngeal view and intubation success.

In summary, engaging the midline vallecular fold with the tip of the standard geometry laryngoscope blade during intubation was associated with improved laryngeal visualization.

---

*Supervising editor:* Steven M. Green, MD. Specific detailed information about possible conflict of interest for individual editors is available at <https://www.annemergmed.com/editors>.

*Author affiliations:* From the Department of Emergency Medicine (Driver, Prekker, Corajod, Reardon), Hennepin County Medical Center, Minneapolis, MN; the Department of Medicine, Division of Pulmonary and Critical Care (Prekker), Hennepin County Medical Center, Minneapolis, MN; the Department of Emergency Medicine (Levitan), Littleton Regional Health, Littleton, NH; the University of



Minnesota School of Medicine (Karl), Minneapolis, MN; and the Des Moines University College of Osteopathic Medicine (Smith), Des Moines, IA.

**Author contributions:** BD, MP, and RR conceived and designed the study. JC, EK, and AS performed video review. BD performed the data analysis. BD, MP, RL, and RR interpreted the data. BD and MP drafted the initial manuscript, and all authors contributed substantially to its revision. BD takes responsibility for the study as a whole.

All authors attest to meeting the 4 [ICMJE.org](http://www.icmje.org) authorship criteria: (1) Substantial contributions to the conception or design of the work; or the acquisition, analysis, or interpretation of data for the work; AND (2) Drafting the work or revising it critically for important intellectual content; AND (3) Final approval of the version to be published; AND (4) Agreement to be accountable for all aspects of the work in ensuring that questions related to the accuracy or integrity of any part of the work are appropriately investigated and resolved.

**Funding and support:** By *Annals* policy, all authors are required to disclose any and all commercial, financial, and other relationships in any way related to the subject of this article as per ICMJE conflict of interest guidelines (see [www.icmje.org](http://www.icmje.org)). The authors have stated that no such relationships exist. The authors report this article did not receive any outside funding or support.

**Publication dates:** Received for publication February 26, 2021. Revision received April 9, 2021. Accepted for publication April 13, 2021.

Presented at the Annual Meeting of the Society of Academic Emergency Medicine, Indianapolis, IN, in May 2018.

## REFERENCES

1. Benumof JL. Difficult laryngoscopy: obtaining the best view. *Can J Anaesth*. 1994;41:361-365.
2. Yentis SM, Lee DJ. Evaluation of an improved scoring system for the grading of direct laryngoscopy. *Anaesthesia*. 1998;53:1041-1044.
3. Koh LKD, Kong CE, Ip-Yam PC. The modified Cormack-Lehane score for the grading of direct laryngoscopy: evaluation in the Asian population. *Anaesth Intensive Care*. 2002;30:48-51.
4. Driver BE, Prekker ME, Klein LR, et al. Effect of use of a bougie vs endotracheal tube and stylet on first-attempt intubation success among patients with difficult airways undergoing emergency intubation: a randomized clinical trial. *JAMA*. 2018;319:2179-2189.
5. Collins JS, Lemmens HJM, Brodsky JB, et al. Laryngoscopy and morbid obesity: a comparison of the "sniff" and "ramped" positions. *Obes Surg*. 2004;14:1171-1175.
6. Levitan RM, Mechem CC, Ochroch EA, et al. Head-elevated laryngoscopy position: improving laryngeal exposure during laryngoscopy by increasing head elevation. *Ann Emerg Med*. 2003;41:322-330.
7. Levitan RM, Mickler T, Hollander JE. Bimanual laryngoscopy: a videographic study of external laryngeal manipulation by novice intubators. *Ann Emerg Med*. 2002;40:30-37.
8. Von Elm E, Altman DG, Egger M, et al. The Strengthening of Reporting of Observational Studies in Epidemiology (STROBE) statement: guidelines for reporting observational studies. *Ann Intern Med*. 2007;147:573-577.
9. Harris PA, Taylor R, Thielke R, et al. Research electronic data capture (REDCap)—a metadata-driven methodology and workflow process for providing translational research informatics support. *J Biomed Inform*. 2009;42:377-381.
10. Cormack RS, Lehane J. Difficult tracheal intubation in obstetrics. *Anaesthesia*. 1984;39:1105-1111.
11. Levitan RM, Ochroch EA, Kush S, et al. Assessment of airway visualization: validation of the percentage of glottic opening (POGO) scale. *Acad Emerg Med*. 1998;5:919-923.
12. Dodd KW, Prekker ME, Robinson AE, et al. Video screen viewing and first intubation attempt success with standard geometry video laryngoscope use. *Am J Emerg Med*. 2019;37:1336-1339.
13. Gu Y, Robert J, Kovacs G, et al. A deliberately restricted laryngeal view with the GlideScope® video laryngoscope is associated with faster and easier tracheal intubation when compared with a full glottic view: a randomized clinical trial. *Can J Anaesth*. 2016;63:928-937.
14. Nakao H. The Macintosh laryngoscope: the mechanism of laryngeal exposure and the optimal maneuver. *Journal of Current Surgery*. 2018;8:1-6.
15. Levitan RM. The mystique of direct laryngoscopy. *Respir Care*. 2007;52:21-23.
16. Reardon RF, Carleton SC. Direct laryngoscopy. In: Brown CAIII, Sakles JC, Mick NW, eds. *The Walls Manual of Emergency Airway Management*. Wolters Kluwer; 2018:139-155.
17. Sakles JC, Mosier JM, Patanwala AE, et al. The utility of the C-MAC as a direct laryngoscope for intubation in the emergency department. *J Emerg Med*. 2016;51:349-357.
18. Sakles JC, Mosier J, Chiu S, et al. A comparison of the C-MAC video laryngoscope to the Macintosh direct laryngoscope for intubation in the emergency department. *Ann Emerg Med*. 2012;60:739-748.
19. Brown CA III, Bair AE, Pallin DJ, et al. Improved glottic exposure with the Video Macintosh Laryngoscope in adult emergency department tracheal intubations. *Ann Emerg Med*. 2010;56:83-88.